

Hyperreactive Malarial Syndrome

Lani Ackerman, MD

Hyperreactive malarial syndrome or hyperreactive malarial splenomegaly syndrome, formerly known as tropical splenomegaly, is a common condition in parts of the developing world.¹ It is characterized by splenic enlargement of at least 10 cm below the costal margin and hemolytic anemia, both of which improve with antimalarial therapy.¹ Hyperreactive malarial syndrome is possibly caused by an excessive immunoglobulin response to malarial antigens or mitogens in patients with a genetic influence on immunoglobulin production. Failure to diagnose this condition can lead to unnecessary splenectomy.² Surgery should be reserved for those patients who fail medical therapy. With increased travel to areas with malaria and an increase in refugees and immigrants entering the United States, family physicians need to be familiar with this condition.

Case Report

A 27-year-old Sudanese man was cared for in the emergency department after being kicked in the abdomen during an altercation. Upon admission by the surgical service, he related a brief history and was given a physical examination. His blood pressure was 110/60 mmHg, heart rate 78 beats per minute, temperature 97.7°F, and respiratory rate 32/min. Findings on the physical examination were unremarkable except for mild midepigastic and left upper quadrant tenderness. He had no hepatomegaly or splenomegaly.

Initial laboratory results were hemoglobin 15.1 g/dL, hematocrit 38.5 percent, white cell count 16,700/ μ L with 79 percent neutrophils, 2 percent band cells, 8 percent lymphocytes, 7 percent monocytes, and 4 percent eosinophils, platelets

110,000/ μ L, sodium 139 mEq/L, potassium 3.3 mEq/L, calcium 9.1 mg/dL, total protein 7.0 g/dL, albumin 4.0 g/dL, bilirubin 3.2 mg/dL, direct bilirubin 0.6 mg/dL, phosphorus 2.8 mg/dL, alkaline phosphatase 66 U/L, carbon dioxide 25.6 mEq/L, cholesterol 251 mg/dL, chloride 108 mEq/L, glucose 115 mg/dL, blood urea nitrogen 4 mg/dL, creatinine 0.8 mg/dL, uric acid 9.1 mg/dL, lactate dehydrogenase 251 U/L, alanine aminotransferase 73 U/L, prothrombin time 12.2 sec with control of 14.5 sec, and partial thromboplastin time 30.1 sec with control of 32.3 sec. A computed tomographic (CT) scan of the abdomen showed a massive spleen 18.0 cm in length and 14.0 cm in anteroposterior dimension. There was no evidence of splenic injury or infiltration. A sonogram of the abdomen had similar findings, and a Doppler examination of the splenic and portal veins indicated normal flow. There were normal findings on posteroanterior and lateral chest radiographs.

The patient was admitted for 24-hour observation. Repeat hemoglobin readings were 13.4, 13.1 and 14.1 g/dL. His temperature, blood pressure, and heart and respiratory rate were stable. Although the patient's abdominal pain resolved and his hemoglobin was stable, he was not discharged because of his splenomegaly. On additional laboratory studies he had a negative direct Coombs test, reticulocyte count of 8.6 percent, leukocyte alkaline phosphatase of 53 U/L, erythrocyte count $3.79 \times 10^6/\mu$ L, mean corpuscular volume $95.5 \mu\text{m}^3$, mean corpuscular hemoglobin 39.9 pg, mean corpuscular hemoglobin concentration 37.6 g/dL, red cell distribution width 15.5 percent, and peripheral smear showing occasional macrocytes and anisocytosis.

A hematology-oncology consultation was requested on the fourth day of hospitalization. At that time the patient reported he had had malarial infections while he lived in Kenya. Further laboratory studies were ordered, with the following results: serum haptoglobin < 5.8 mg/dL (normal

Submitted, revised, 14 March 1996.

From the Department of Family Practice and Community Medicine, John Peter Smith Hospital, Fort Worth, Tex. Address reprint requests to Lani Ackerman, MD, Department of Family Practice and Community Medicine, John Peter Smith Hospital, 1500 South Main St, Fort Worth, TX 76104-4940.

16-200 mg/dL) and negative VDRL and malarial smears; bone marrow aspirate and biopsy showed erythroid hyperplasia without infiltrations, tumors, or effacements; and there were no growth of cultures and no acid-fast bacilli. The patient was believed to have hypersplenism and hemolytic anemia. Differential diagnosis included malaria, chronic myelogenous leukemia, hairy cell leukemia, myeloid metaplasia, storage diseases, portal vein thrombosis, cirrhosis, and inflammatory diseases.

Although no specific diagnosis was made, the surgical consultant decided to perform a splenectomy because of the hemolytic anemia and massive splenomegaly. Pathologic examination of the spleen showed marked congestion of splenic cords and sinuses and extensive hemosiderin deposition consistent with hypersplenism secondary to hemolytic anemia. Liver biopsies showed normal architecture and extensive hemosiderin deposition within hepatocytes consistent with changes secondary to hemolytic anemia.

The patient had a difficult postsurgical recovery and was discharged 4 weeks after admission. One of the family practice residents on the surgical service referred the patient to the International Health Clinic within the Family Health Clinic for follow-up and ongoing care. The possible diagnosis of hyperreactive malarial syndrome was made based on the patient's history.³

Discussion

Hyperreactive malarial syndrome, formerly called tropical splenomegaly syndrome, has been renamed to reflect the role of malaria in its pathogenesis, the excessive activity of the immune system, the other organs involved in the process, and the difference between this syndrome and other forms of malarial splenomegaly.^{1,4,5}

Hyperreactive malarial syndrome has a distribution that correlates with malaria-endemic areas. The greatest number of cases are from New Guinea and Africa. The incidence rate ranges from 0.5 to 80.0 percent in populations in New Guinea, Uganda, and Nigeria.¹ Clusters of cases in families and tribes indicate there might be a genetic predisposition.⁶

The major diagnostic criteria are gross splenomegaly extending 10 cm below the costal margin, immunity to malaria acquired by long-term residency in a malarious area, hyperelevation of

Table 1. Major Diagnostic Criteria for Hyperreactive Malarial Syndrome.

Major diagnostic criteria	
Gross splenomegaly > 10 cm below costal margin with no other cause	
Immunity to malaria	
Serum IgM at least two standard deviations above the local mean	
Clinical and immunologic response to antimalarial treatment	
Minor diagnostic criteria	
Hepatic sinusoidal lymphocytosis	
Normal cellular and humoral responses to antigenic challenge	
Normal phytohemagglutinin response—in contrast to patient with lymphoma or chronic lymphocytic leukemia (there is a wide variation in phytohemagglutinin response)	
Hypersplenism—as shown by red cell pooling and hemolysis, granulocytopenia, thrombocytopenia, and plasma volume expansion.	
Lymphocyte proliferation—peripheral lymphocytosis and infiltration of the bone marrow by mature lymphocytes	
Occurrence in families—certain races and families are more prone to develop this syndrome, and sickle cell trait offers partial protection.	

serum IgM levels, and response to antimalarial treatment as evidenced by clinical, hematologic, and immunologic improvement. Minor criteria are hepatic sinusoidal lymphocytosis (which occurs in more than 80 percent of patients), a normal phytohemagglutinin response (compared with chronic lymphocytic leukemia and lymphoma), hypersplenism, lymphocyte proliferation, and familial predisposition (Table 1).^{3,4}

In many countries IgM levels and phytohemagglutinin lymphocyte transformation tests are not available. In practice the diagnosis of hyperreactive malarial syndrome is usually based on clinical findings and exclusion of other diseases as well as splenic regression with antimalarial treatment. Schistosomiasis, leishmaniasis, onchocerciasis, tuberculosis, and hematologic malignancies must be ruled out⁷ by clinical examination, history, and bone marrow studies.

Clinical features commonly seen include left-sided abdominal pain, fever, cough, fatigue, weakness, pallor, abdominal swelling, portal hypertension, jaundice, anemia, thrombocytopenia, and leukopenia (Table 2).^{1,3}

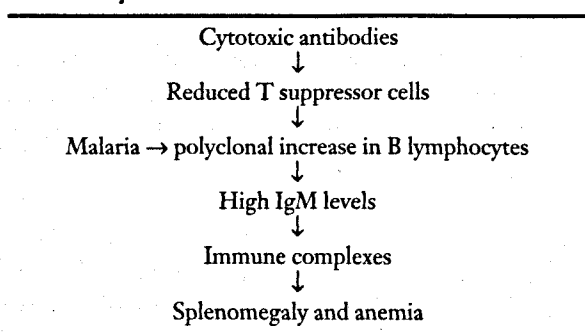
The main factor in the anemia is an expanded plasma volume that is due partially to increased albumin and IgG turnover. Severe acute hemolytic

Table 2. Main Signs and Symptoms in 69 Patients in Zariz, Nigeria.

Symptoms and Signs	No. (%)
Symptoms	
Abdominal swelling	44 (63.8)
Abdominal pain	36 (52.2)
Cough	9 (13.0)
Weakness and loss of energy	8 (11.6)
Leg swelling	6 (8.7)
Epistaxis	5 (7.2)
Hernia	3 (4.3)
Signs	
Splenomegaly (> 15 cm in 30)	69 (100)
Hepatomegaly	64 (92.8)
Pallor	19 (27.5)
Jaundice	12 (17.4)
Hemic murmur	3 (4.3)
Hernia	2 (2.9)
Leg ulcer	1 (1.4)

Adapted from Fakunle.³

Table 3. Suggested Pathogenesis of Hyperreactive Malarial Syndrome.



anemia can occur, particularly in pregnant women.⁵ Patients with hyperreactive malarial syndrome have an increased mortality rate caused by overwhelming infection and, according to some observers, the development of lymphomas.³

The mechanism of this anemia was studied in the past by Pryor⁸ and Ringelmann et al.⁹ Red cell life span was moderately reduced and was compensated for by increased production. Selective red cell destruction occurred in the spleen. There was no evidence of an intrinsic red cell defect. Red cell volume was normal or increased in nearly all patients, reflecting effective erythropoiesis. There was an increased plasma volume, accounted for in some part by the increased albumin and IgG turnover. Because there was an inverse relation between hematocrit and plasma volume in Pryor's

study, he believed the anemia was dilutional. Red cell pooling occurred in the spleen.^{3,10}

In hyperreactive malarial syndrome, the reasons for hemolysis are unclear; no malaria parasites are detected and the direct Coombs' test and screening for glucose-6-phosphate dehydrogenase deficiency are both negative. The hemolytic anemia is more severe in pregnant women because of superimposed iron and folic acid deficiencies.^{5,10}

The pathogenesis of hyperreactive malarial syndrome is not completely understood. The underlying defect appears to be a lack of T lymphocytes (suppressor cells) involved in controlling antibody production by B lymphocytes (Table 3).^{6,11} The overproduction of IgM is due to stimulation of B lymphocytes by a malarial antigen or mitogen in response to repeated malarial infections. Antibodies combine with antigens to form immune complexes that can be detected in blood. Antimalarial antibodies, cryoglobulins, immune complexes, and autoantibodies are all found. Immune complexes are removed from the blood by splenic macrophages and the spleen eventually hypertrophies. The splenic enlargement results in pooling red cells and trapping platelets in the spleen and plasma volume expansion, which causes anemia and thrombocytopenia. Examination of the liver and spleen reveals reticuloendothelial and sinusoidal hyperplasia, infiltration of hepatic sinuses by T lymphocytes, and splenic sequestration and phagocytosis of erythrocytes. Malarial parasites are rarely detected on peripheral blood smears or splenic tissue tests.^{3,4,6}

The treatment of hyperreactive malarial syndrome consists of inhibition of the triggering mechanism of IgM production.¹² Once the diagnosis of hyperreactive malarial syndrome is suspected, regular antimalarial prophylaxis with proguanil or chloroquine daily³ causes splenic size to regress and immunologic features to be normalized. Recently, pyrimethamine and folic acid have also been used successfully.^{7,11} It can take 3 months of therapy before a notable size decrease occurs. Lifelong malarial prophylaxis is usually required if the patient is still exposed to malaria. Splenectomy is rarely needed and is generally associated with an increased mortality due to sepsis.

This case represents a probable missed diagnosis of hyperreactive malarial syndrome that

resulted in an unnecessary splenectomy. Unfortunately, serum IgM levels and a phytohemagglutinin response were not obtained, and a trial of antimalarial therapy was never given. The patient's country of origin, a several-year stay in Kenya, and his history of repeated malarial infections warranted a more complete diagnostic effort. With the increasing immigrant population seen by family physicians, hyperreactive malarial syndrome should be considered in the differential diagnosis of patients from endemic areas who have massive splenomegaly, and a trial of antimalarial medications should be given in a suspected case before resorting to splenectomy.

References

1. Strickland GT. Hunter's tropical medicine. 7th ed. Philadelphia, WB Saunders Co, 1991:615-7.
2. Gibney EJ. Surgical aspects of malaria. *Br J Surg* 1990;77:964-7.
3. Fakunle YM. Tropical splenomegaly. Part 1: Tropical Africa. *Clin Haematol* 1981;10:963-75.
4. Zingman BS, Viner BL. Splenic complications in malaria: case report and review. *Clin Infect Dis* 1993;16:223-32.
5. Cook GC. Prevention and treatment of malaria. *Lancet* 1988;1:32-7.
6. Bates I. Hyperreactive malarial splenomegaly in pregnancy. *Trop Doct* 1991;21:101-3.
7. Siqueira-Batista, Quintas LER. Tropical splenomegaly syndrome: a review from Brazil. *East Afr Med J* 1994;71:771-2.
8. Pryor DS. The mechanism of anaemia in tropical splenomegaly. *Q J Med* 1967b;36:337.
9. Ringelhann B, Miller H, Konotey-Ahulu FI. The origin of anaemia in tropical splenomegaly syndrome. *Acta Med Acad Sci Hung Tomus* 1973;30:331.
10. Crane GG. Tropical splenomegaly. Part 2: Oceania. *Clin Haematol* 1981;10:976-82.
11. Manenti F, Porta E, Esposito R, Antinori S. Treatment of hyperreactive malarial splenomegaly syndrome. *Lancet* 1994;343:1441-2.
12. Betticher DC, Nicole A, Pugin P, Regamey C. The hyperreactive malarial splenomegaly syndrome in a European: has the treatment a modulatory effect on the immune system? *J Infect Dis* 1990;161:157-9.