

# Angioedema And Angiotensin-Converting Enzyme (ACE) Inhibitors

Jay R. Varma, MD, and George A. Nixon, MD

Angioedema is defined as anaphylaxis limited to the skin and subcutaneous tissues caused by drug allergy, insect bites, certain foods, and injections of sera. It appears as a diffuse swelling of loose subcutaneous areas: dorsum of the hands and feet, eyelids, lips, mucous membranes, and genitalia. When the edema involves the respiratory passage, it could produce respiratory distress.

It is estimated that 22 percent of the population in the United States has hypertension for which 56 percent of these patients are currently taking medications. How many of these patients are receiving angiotensin-converting enzyme (ACE) inhibitors is difficult to estimate; however, sales figures of ACE inhibitors indicate that they are frequently prescribed. Introduced in 1984, ACE inhibitors are relatively new agents for treatment of hypertension and congestive heart failure. They have an excellent safety profile and are tolerated well.<sup>1-3</sup>

Angioedema has been reported to occur in patients who are taking ACE inhibitors.<sup>1-3</sup> We present 2 patients who were taking these agents and who complained of angioedema.

## Illustrative Cases

### Case 1

A 49-year-old African-American woman, who had hypertension and iron deficiency anemia secondary to uterine fibroids and perimenopausal bleeding, came to the Family Medicine Center complaining of swelling of her upper lip that had begun 4 hours earlier.

The patient was alarmed by the swelling, which involved the entire upper lip and nasolabial region. She had no other complaints or history of similar swelling.

She related no history of trauma, insect sting, urticaria, or exposure to any known allergens or new drugs. She had a lunch of seafood gumbo the previous evening without ill effect, and she denied any history of seafood allergy. Her current medications were norethindrone ethinyl estradiol (Ovcon), triamterene, hydrochlorothiazide (Dyazide), and enalapril (Vasotec).

That morning the patient noticed the onset of symptoms as a tingling of the upper lip beginning approximately 1 hour after taking her first 10-mg dose of enalapril. During the preceding 3 months she had taken 5 mg of enalapril daily without adverse effects. Her enalapril dosage had been increased the previous day at a scheduled follow-up visit because her blood pressure control was inadequate at the 5 mg/d dose.

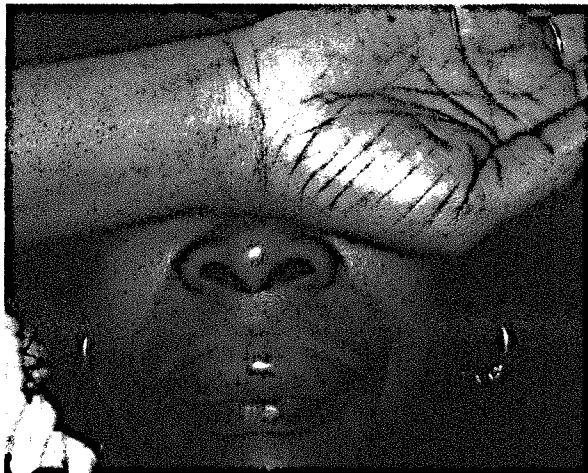
On physical examination she was alert and in some emotional, but in no acute physical, distress. She denied any difficulty swallowing, breathing, or other areas of swelling. Her blood pressure was 180/108 mmHg, pulse 78 beats per minute, respirations 18/min, and temperature 98.6°F. No change in speech was noted. There was no swelling of the tongue or pharyngeal tissue. The patient had no difficulty swallowing, and there was no evidence of stridor or respiratory compromise. She did have localized angioneurotic edema of the upper lip (Figure 1) without evidence of oral pharyngeal or respiratory involvement.

Fifty milligrams of diphenhydramine were administered intramuscularly; the patient was instructed to discontinue enalapril and return to the clinic or the emergency department if she had any difficulty with breathing or swallowing. Four hours later the patient returned to the Family Medicine Clinic with new symptoms of swelling of her lower lip and mild nausea. The patient appeared to be in no acute distress, but she had moderate swelling of the lower lip. She had no swelling of the tongue or pharyngeal tissues. Her speech was clear, her swallowing was unimpaired, and she had normal air movement on lung examination without wheezes or rhonchi. Her

---

Submitted, revised, 6 May 1994.

From the Department of Family Medicine, Medical College of Georgia, Augusta. Address reprint requests to Jay R. Varma, MD, Department of Family Medicine, Medical College of Georgia, Augusta, GA 30912.



**Figure 1. Case 1: A 49-year-old woman with localized angioneurotic edema of the upper lip.**

blood pressure, respirations, and temperature were stable.

The decision was made to continue treatment on an outpatient basis as the swelling remained limited to the lips and perioral mucosa, and she had no evidence of tongue, laryngeal, or pulmonary involvement. She was prescribed 60 mg of prednisone to be taken orally. Twenty-four hours later all swelling had resolved without interval progression of symptoms. Since then no ACE inhibitors have been prescribed, and the patient has experienced no further recurrences of angioneurotic edema.

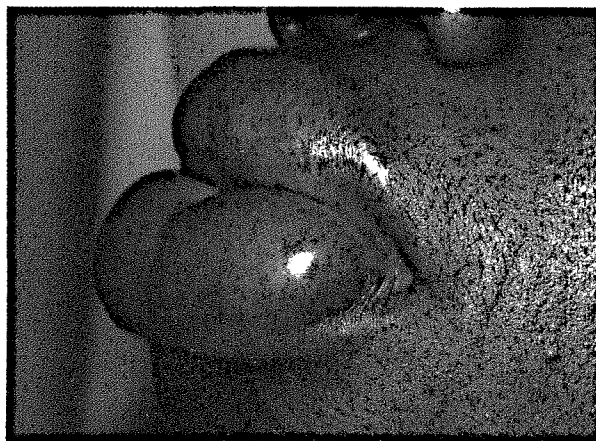
#### **Case 2**

The second patient, a 45-year-old African-American woman, came to the Family Medicine Center at about 2 PM on the day of admission complaining of urticaria for about 4 hours and swelling of the lower lip for about 3 hours.

She was not in any distress. Her temperature was 99.4°F, pulse 100 beats per minute, respirations 20/min, blood pressure 140/96 mmHg, and weight 248 lb. She had been seen in the Family Medicine Center in the past, and her current medication consisted of enalapril 5 mg every morning, prescribed for hypertension 3 weeks earlier, which she took on the morning of admission at 7:30 AM. She was also taking 25 mg of hydroxyzine pamoate on an as-needed basis. She denied similar problems in the past. The patient had breakfast at 8 AM, which consisted of raisin bran cereal and milk. She noticed itching and a few small bumps under her skin when she arrived at work at about

8:30 AM at the Augusta National Golf Club, where she worked as a housecleaner. At approximately 11 AM, she developed increased itching of the skin and swelling of the lower lip. She also noticed burning in the chest and decided to have a Coca Cola, which did not help. At that time she decided to seek medical advice. On arriving at the Family Medicine Center, the swelling of the left lower lip and upper lip was evident, which gradually increased in size (Figure 2). In addition, the urticarial lesions, noted under the skin, had increased in size while she was being examined.

During this period she was very stable. She was given 50 mg of diphenhydramine hydrochloride intramuscularly and 60 mg of methylprednisone intramuscularly. An intravenous drip was started with normal saline. At approximately 2:45 PM she complained of palpitations, and on re-examination the only change in her clinical condition was an increase in her pulse to 120 beats per minute. She consented to hospitalization for monitoring and was admitted with the diagnosis of angioneurotic edema, probably secondary to enalapril. She was kept under observation for 36 hours with no further development. The urticaria and the swelling of the lips all resolved within 24 hours. She continued to take diphenhydramine hydrochloride orally. When she was seen in the Family Medicine Center again 24 hours after hospital discharge, she was doing well and had only some residual pruritus. She was prescribed hydrochlorothiazide for blood pressure control and was also advised to continue the diphenhydramine until the pruritus resolved completely.



**Figure 2. Case 2: A 45-year-old woman with swelling of the left lower lip and upper lip.**

## Discussion

Angioedema is listed as a potential adverse reaction to ACE inhibitors and appears to occur at similar frequencies with the following medication: enalapril (0.2 percent), captopril (0.1 percent), lisinopril (0.1 percent), and quinapril (0.1 percent).<sup>4</sup>

As in the patients presented here, angioedema of the face and lips is described, as well as of the face, tongue, glottis, mucous membranes, larynx, and extremities. Episodes of angioneurotic edema can occur after the first dose or anytime during the course of therapy. It would therefore be important to discuss this possibility with the patient, and the patient should also be monitored after the first dose of any ACE inhibitor.

One study reporting 4 cases of ACE inhibitor-associated edema found that all 4 patients had a history of idiopathic angioedema.<sup>5</sup> There was no such history in either of our patients. With enalapril the risk of angioneurotic edema appears to be highest during the first week of therapy and then to decrease thereafter.<sup>6</sup> The first patient had taken enalapril for 3 months without problems. Adverse effects developed when the dose was increased, suggesting that the occurrence of angioneurotic edema could be related not only to a particular brand of ACE inhibitor but also to dosage. Whether enalapril or another ACE inhibitor can be safely resumed is not clear from the medical literature.

We recommend that this class of drugs be discontinued in patients who have experienced angioedema after taking any one of its members. Most cases might require no treatment other than discontinuation of the ACE inhibitor. Antihistamines can enhance resolution of symptoms. This class of antihypertensive drugs was not prescribed again for these patients because angioedema can

produce fatal edema of the larynx. In cases in which there is swelling of the tongue or larynx or evidence of respiratory compromise, the ACE inhibitor should be discontinued. If there is laryngeal or glottic edema or evidence of respiratory compromise, then epinephrine should be administered (0.3 to 0.5 mg subcutaneously 1:1000 solution), and the patient should be hospitalized for observation and further medical interventions as necessary. In view of the possible occurrence of angioedema in patients who are given ACE inhibitors, it would be important to elicit a history of drug reactions, which would certainly raise some concern and alert the physician to the possibility of a reaction occurring. We also believe very strongly that all patients should be kept under supervision and observation for several hours either in the outpatient setting where monitoring is available or in the emergency department or, if indicated, in the hospital.

## References

1. Finley CJ, Silverman MA, Nunez AE. Angiotensin-converting enzyme inhibitor-induced angioedema: still unrecognized. *Am J Emerg Med* 1992; 10:550-2.
2. Rees RS, Bergman J, Ramirez-Alexander R. Angioedema associated with lisinopril. *Am J Emerg Med* 1992; 10:321-2.
3. Seidman MD, Lewandowski CA, Sarpa JR, Potesta E, Schweitzer VG. Angioedema related to angiotensin-converting enzyme inhibitors. *Otolaryngol Head Neck Surg* 1990; 102:727-31.
4. Olin BR. Drug facts and comparisons. 47th ed. St. Louis: Facts and Comparisons, 1993:818.
5. Orfan N, Patterson R, Dykewicz MS. Severe angioedema related to ACE inhibitors in patients with a history of idiopathic angioedema. *JAMA* 1990; 264:1287-9.
6. Slater EE, Merrill DD, Guess HA, Roylance PJ, Cooper WD, Inman WH, Ewan PW. Clinical profile of angioedema associated with angiotensin-converting-enzyme inhibition. *JAMA* 1988; 260:967-70.