

Osteitis Pubis

Chris Vincent, MD

Background: A 55-year-old woman was seen for pubic symphysis tenderness that started 3 weeks after bladder suspension surgery for urinary incontinence. A diagnosis of osteitis pubis was made based on the results of the physical, radiographic, and laboratory examinations. The paucity of information on this topic in primary care textbooks prompted a literature review of the subject.

Methods: A computer-assisted literature search of the MEDLINE files from 1966 to the present was performed using the terms "osteitis," "osteomyelitis," and "pubic symphysis." Older documents and papers of related interest were obtained by cross-reference of the bibliographies of the articles generated by the search.

Results and Conclusions: Osteitis pubis is an infrequent complication of pelvic surgery, parturition, or athletic activities. The diagnosis is made on the basis of the typical findings of pubic tenderness and pain on hip abduction that occurs a few weeks following the inciting event. Initial treatment consists of rest, physical therapy, and oral nonsteroidal or glucocorticoid anti-inflammatory medications. The use of intra-articular glucocorticoid injections is controversial. Surgery is rarely indicated and should be reserved for patients who have severe pain or pubic instability that has not responded to conservative therapy. (J Am Board Fam Pract 1993; 6:492-496.)

Osteitis pubis is an uncommon inflammatory condition of the pubic symphysis that is usually triggered by pelvic surgery, vaginal delivery, or strenuous athletic activity. Afflicted persons complain of groin pain exacerbated by walking or pelvic motion. The erythrocyte sedimentation rate (ESR) is usually elevated. Findings on pelvic radiographs and bone scans with technetium Tc 99m methylenediphosphonate (^{99m}Tc MDP) are usually abnormal, but the radiographic findings can be normal early in the course of the disease. Osteitis pubis is a clinical diagnosis and is treated conservatively with rest, physical therapy, and anti-inflammatory agents. The prognosis is generally good, and complete resolution of pain occurs within 6 to 12 months. Because osteomyelitis of the symphysis pubis is treated aggressively with surgical débridement and intravenous antibiotics, this diagnosis must be excluded before starting therapy for osteitis pubis.

Case Report

The patient, a 55-year-old gravida 9, para 6, woman, had an uncomplicated Marshall-Marchetti bladder suspension for urinary stress incontinence. Three weeks following the procedure, she complained of increasing anterior pelvic pain and associated groin pain with walking. A pelvic sonogram was unremarkable, and her ESR was 53 mm/h. She was treated with two 6-day courses of methylprednisolone (Medrol Dosepak), as well as 2 weeks of naproxen (Naprosyn) without improvement. Six weeks following her operation she came to her family physician complaining of worsening pelvic pain. She denied having any fever, dysuria, or vaginal discharge.

She walked with a slow, wide-based, waddling gait, keeping her knees and hips slightly flexed. Her os pubis was tender to palpation, and pressure on her anterior superior iliac spine produced pain in the region of the pubic symphysis. Passive movement of her hip joints caused a similar pain. Her white cell count was $15.8 \times 10^9/\text{L}$ ($15,800/\text{mm}^3$) with a left shift. Her ESR was 35 mm/h. Results of a urinalysis and findings on a pelvic radiograph were normal (Figure 1).

A pelvic magnetic resonance image was obtained to try to exclude the possibility of a pelvic abscess. STIR (short T1 inversion recovery) images showed inflammatory changes of the pubic

Submitted, revised, 28 April 1993.

From the Swedish Hospital Family Practice Residency, Seattle, Washington. Address reprint requests to Chris Vincent, MD, Swedish Hospital Family Practice Residency, 700 Minor Avenue, Seattle, WA 98104.

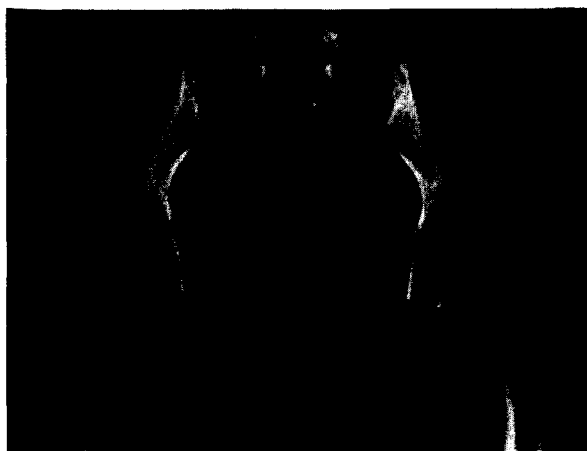


Figure 1. Initial pelvic radiograph (taken 3 weeks after the onset of symptoms) showing normal pubic symphysis.

symphysis and surrounding tissue. These changes were believed to be consistent with either osteitis pubis or osteomyelitis of the symphysis pubis. To differentiate between these two conditions, a fine-needle aspiration of the pubic symphysis was performed. Histologic examination of the retrieved tissue showed inflammatory cells without bacteria. Cultures for fungal, tuberculous, and anaerobic and aerobic organisms were sterile. The patient was treated with physical therapy, etodolac (Lodine), and acetaminophen with oxycodone (Tylox). During the next 6 months her symptoms gradually resolved. Subsequent pelvic radiographs showed widening of the symphysis pubis with irregularity and sclerosis of the bony margins (Figures 2–4). Her ESR returned to normal. On two separate occasions during the early phase of her recovery, she developed urinary tract infections caused by *Pseudomonas aeruginosa*. Both episodes were treated successfully with 10-day courses of oral ciprofloxacin (Cipro).

Discussion

Osteitis pubis was first described in the English literature by Beer,¹ a urologist, in 1924. He noted that the disease followed suprapubic operations. The most characteristic symptom he reported was severe pain in the symphysis brought on by movement of the trunk or pelvis. He observed that subsequently the condition extended to the pubic ramis so that the thigh adductor muscles were involved, resulting in pain with leg movement. These symptoms did not begin until 3 or 4 weeks after the surgery. Physical signs, he

noted, were minimal, consisting mainly of tenderness over the pubic symphysis.

Since Beer's time little has been added to his original description. Osteitis pubis has now been reported in association with parturition, trauma, nonurological surgery, arthritic disorders, and athletic activities, especially running or kicking.^{2–6} At times, no inciting factor is found.^{3,7} The disease occurs in men and women. In some case series a female predominance has been reported,^{2,3,6} whereas others have observed the disease more often in men.^{5,8} There have been no published accounts of osteitis pubis in the pediatric literature, but there have been several reports of pelvic osteomyelitis in children who have sterile blood and bone cultures.^{9,10}

Many have observed that affected patients have a shuffling or waddling gait.^{3,6,8} Occasionally patients complain of a clicking sensation in the symphysis pubis when walking on uneven ground or on rising from a chair.^{3,11,12} Physical findings associated with osteitis pubis are listed in Table 1. Pubic tenderness is present in 25 to 70 percent of patients.^{3,5} Fever, usually absent, would suggest osteomyelitis.

Diagnostic studies can help confirm the clinical diagnosis, although most abnormalities are not specific for osteitis pubis. An ESR of more than 20 mm/h (Westergren method) can be present.^{3,7,12,13} Early on, findings on the anteroposterior pelvic radiograph can be normal. Within a few weeks of the onset of symptoms, however, bilateral rarefaction, erosion of the symphysis mar-




Figure 2. Pelvic radiograph taken 2 months after the onset of symptoms. Note the widening of the pubic symphysis and the irregular margins of joint.




Figure 3. Pelvic radiograph taken 6 months after the onset of symptoms. Note the sclerosis of the margins of the pubic symphysis.

gins, and widening of the joint space are seen. Several months later, the radiograph shows narrowing of the joint space with sclerosis of the adjacent pubic bones.^{3,5,6,8,11,12} A ^{99m}Tc MDP bone scan showing increased isotope uptake by the symphysis is often observed.^{5,14}

The differential diagnoses of osteitis pubis are listed in Table 2.^{12,14} Medical history, examination, laboratory testing, and radiography are usually sufficient to make the diagnosis. Osteomyelitis of the symphysis pubis is the most difficult condition to exclude. The signs and symptoms of osteomyelitis — anterior pelvic pain, spasm of the hip adductor and rectus abdominis muscles, and wide-based gait — mimic those of osteitis pubis.^{12,15,16} Radiographic and bone scan findings are likewise similar.^{12,17,18} Patients with osteomyelitis might be afebrile and have a normal white cell count, although the ESR is almost always elevated.¹⁵⁻¹⁸ Unilateral involvement or the demonstration of a sequestrum on the pelvic radiograph suggests osteomyelitis.^{3,15,16} If the diagnosis is in question, a needle aspiration or bone biopsy should be done to obtain material for culture.¹⁵⁻¹⁸

The exact pathogenesis of osteitis pubis is unclear. Three factors — antecedent trauma, venous stasis, and low-grade infection — have been present in varying degrees in most patients with osteitis pubis. Beer¹ was the first to theorize that indirect injury of the pubic attachment of the rectus abdominis muscle caused osteitis pubis. His view has been supported by most authors,^{3-7,11-14} although the disease in athletes might result from

a periostitis of the pubic symphysis caused by a mechanical strain of the gracilis muscle.¹⁹ Steinbach, et al.²⁰ were the first to demonstrate that patients with osteitis pubis had impaired venous flow from the pubic bone. Holmgren²¹ and Mynors²² noted dramatic relief of pain in patients treated with heparin, lending support to the idea that osteitis pubis is caused by pubic thrombosis.

There is still controversy concerning the role infection plays in the genesis of osteitis pubis. Many authors have noted that patients with osteitis pubis have an associated urinary tract infection.^{3,7,23,24} Others have not found evidence of infection.^{2,4,6,11,13,14} Attempts to reproduce osteitis pubis in animals by bacterial inoculation were unsuccessful.²⁵ Bone biopsy of patients without obvious osteomyelitis have shown marrow fibrosis with plasma cell and lymphocyte infiltration, suggesting chronic inflammation without acute infection.^{3,6,16}

The prognosis for patients with osteitis pubis is generally good. Gradual resolution of symptoms taking 3 to 12 months is the rule, although a few patients will continue to have pain for several years following the initial onset.^{1-3,5,8,11,19-21,23}

The therapeutic regimens that have been tried for the treatment of osteitis pubis include body cast immobilization, vitamin B complex injections, antibiotics, physical therapy, rest, radiation therapy, adrenocorticotrophic hormone injection, intravenous heparin, nonsteroidal anti-inflammatory agents, surgery, and intralesional, oral, and intravenous glucocorticoids.^{1-11,13,14,19-25} To date

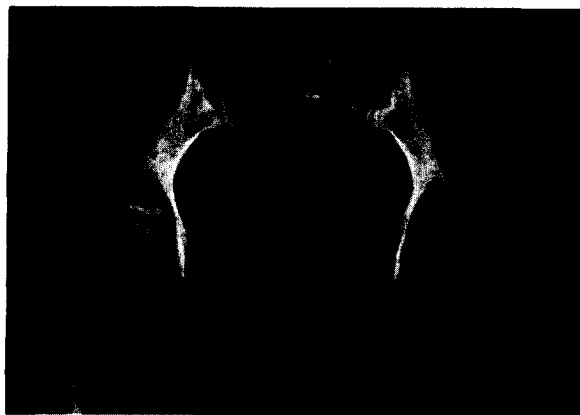

Figure 4. Pelvic radiograph taken 8 months after the onset of symptoms. Note the sclerosis of the margins of the pubic symphysis, as well as the joint narrowing.

Table 1. Physical Findings Associated with Osteitis Pubis (listed in order of most frequent to least frequent finding).*

Finding	Percent
Pubic symphysis tenderness	27-68
Adductor longus tenderness	41
Restricted hip abduction or rotation	25-40
Pain on pelvic compression	24
Gait disturbance	22
Hip muscle weakness	14
Pubic symphysis instability or audible "click"	9

*Adapted from Coventry and Mitchell³ and Fricker, et al.⁵

no single method has been shown to be superior to others, and some might be harmful. The most recent reports have recommended a combination of rest, physical therapy, and oral nonsteroidal or glucocorticoid anti-inflammatory medications.^{4,5,19} The use of intra-articular glucocorticoid injections is controversial.^{5,11,13,14} Surgery is rarely indicated and should be reserved for patients who have severe pain or pubic instability that has not responded to conservative therapy.^{2,3,5,11} Because of the infrequency of the disease, there have been no randomized, controlled trials to evaluate the merits of various treatment protocols.

There are few long-term complications of osteitis pubis. Chronic pain and hip stiffness appear to be the only major residual problems, and both occur infrequently. During the acute phase, a concomitant urinary tract infection might be present and, if so, should be treated.^{3,5,7,23} Athletes with

osteitis pubis can usually return to sports activities after 2 to 4 months, although repetitive trauma, such as kicking or running, might reactivate symptoms.^{5,19}

Conclusion

Osteitis pubis is an infrequent complication of pelvic surgery or trauma resulting from parturition or athletic activities. The diagnosis is made on the basis of the typical findings of pubic tenderness and pain on hip abduction that occur a few weeks following surgery or trauma. Laboratory and imaging studies are of limited use but can be helpful in excluding other more serious conditions, such as osteomyelitis of the pubic symphysis or a malignant growth. The treatment is conservative and supportive. Family physicians, because of their training in urology, gynecology, obstetrics, and sports medicine, should be well equipped to diagnose and treat osteitis pubis.

References

1. Beer E. Periostitis of the symphysis and descending rami of the pubes following suprapubic operations. *Int J Med Surg* 1924; 37(5):224-5.
2. Schnute WJ. Osteitis pubis. *Clin Orthop* 1961; 20:187-92.
3. Coventry MB, Mitchell WC. Osteitis pubis. Observations based on a study of 45 patients. *JAMA* 1961; 178:898-905.
4. Gonik B, Stringer CA. Postpartum osteitis pubis. *South Med J* 1985; 78:213-4.
5. Fricker PA, Taunton JE, Ammann W. Osteitis pubis in athletes. Infection, inflammation or injury? *Sports Med* 1991; 12:266-79.
6. Grace JN, Sim FH, Shives TC, Coventry MB. Wedge resection of the symphysis pubis for the treatment of osteitis pubis. *J Bone Joint Surg* 1989; 71:358-64.
7. Catania J, Fullerton KJ. Osteitis pubis in a 78-year-old female. *Postgrad Med J* 1988; 64:132-3.
8. Lavalley LL, Hamm FC. Osteitis pubis: its diagnosis and treatment. *J Urol* 1949; 61:83-90.
9. Edwards MS, Baker CJ, Granberry WM, Barrett FF. Pelvic osteomyelitis in children. *Pediatrics* 1978; 61:62-7.
10. Heldrich F, Harris V. Osteomyelitis of the pubis. *Acta Paediatr Scand* 1979; 68:39-41.
11. Harris NH, Murray RD. Lesions of the symphysis pubis in athletes. *Br Med J* 1974; 4:211-4.
12. Sequeira W. Disease of the pubic symphysis. *Semin Arthritis Rheum* 1986; 16:11-21.
13. Watt J, Bottomley MB, Read MT. Olympic athletics medical experience, Seoul — personal views. *Br J Sports Med* 1989; 23:76-9.

Table 2. Differential Diagnosis of Osteitis Pubis.*

Osteomyelitis of the symphysis pubis
Ankylosing spondylitis
Reiter syndrome
Adductor muscle strain
Gout
Pseudogout (calcium pyrophosphate disease)
Hyperparathyroidism
Prostatitis
Orchitis
Urolithiasis
Primary or metastatic cancer
Symptomatic separation of the symphysis due to pregnancy

*Adapted from Sequeira¹² and Koch and Jackson.¹⁴

14. Koch RA, Jackson DW. Pubic symphysisitis in runners. A report of two cases. *Am J Sports Med* 1981; 9:62-3.
15. Burns JR, Gregory JG. Osteomyelitis of the pubic symphysis after urologic surgery. *J Urol* 1977; 118:803-5.
16. Rosenthal RE, Spickard WA, Markham RD, Rhamy RK. Osteomyelitis of the symphysis pubis: a separate disease from osteitis pubis. Report of three cases and a review of the literature. *J Bone Joint Surg* 1982; 64:123-8.
17. del Busto R, Quinn EL, Fisher EJ, Madhavan T. Osteomyelitis of the pubis. Report of seven cases. *JAMA* 1982; 248:1498-500.
18. Michiels E, Knockaert DC, Vanneste SB. Infectious osteitis pubis. *Neth J Med* 1990; 36:297-300.
19. Hanson PG, Angerine M, Juhl JH. Osteitis pubis in sports activities. *Phys Sports Med* 1978; 6(10):111-4.
20. Steinbach HL, Petrakis NL, Gilfillan RS, Smith DR. The pathogenesis of osteitis pubis. *J Urol* 1955; 74:840-6.
21. Holmgren G. The treatment of osteitis pubis with anticoagulants. A report of three cases in Africans. *Cent Afr J Med* 1972; 18:10-2.
22. Mynors JM. Osteitis pubis. *J Urol* 1974; 112:664-5.
23. Daw WJ, Funke AH. Osteitis pubis treated by cortisone. *J Urol* 1953; 69:686-91.
24. Gilbert DN, Azorri M, Gore R, Hofeldt R. The bacterial causation of postoperative osteitis pubis. *Surg Gynecol Obstet* 1975; 141:195-8.
25. Wheeler WK. Periostitis pubes following suprapubic cystostomy. *J Urol* 1941; 45:467-75.