

Hepatitis Associated With Lyme Disease

Keith Sinusas, M.D., Michael A. Kazakoff, M.D., and Christine Macchia, M.P.H.

Lyme borreliosis is an important clinical illness, the incidence of which has increased greatly during the previous decade.¹ Nationally the disease has been documented in 46 states with a 16-fold increase in reported cases since 1982.² Lyme disease is named after the town of Old Lyme, Connecticut, from which the first cases reported in the United States were found.³ Our service area in Connecticut remains an area of high occurrence for Lyme disease.⁴

Lyme disease is caused by the spirochete *Borrelia burgdorferi*, which is spread to humans by a tick vector, primarily *Ixodes dammini*. It is a multisystem illness potentially involving the skin, heart, joints, and central nervous system.⁵ The eyes, lymphatics, respiratory system, and genitourinary system can also be involved.⁶ Involvement of the liver is also known to occur.^{5,6} We report a case of early disseminated Lyme disease in which hepatocellular dysfunction was discovered. This subclinical hepatitis resolved completely after appropriate treatment with oral antibiotics.

Case Report

A 52-year-old man came to his family physician with a 1-week history of fever, lethargy, fatigue, and diffuse myalgias and arthralgias. The symptoms had been progressively worsening during that period. Five days before the visit he noticed a peculiar rash over his entire body. At the time of presentation he was also complaining of a headache and nonspecific chest pains. Nausea was a prominent symptom but was not associated with any vomiting, diarrhea, or abdominal pain. The patient gave no history of a recent deer tick bite.

On examination his oral temperature was 37.5°C (99.5°F) and his blood pressure was 130/92 mmHg. His skin was diffusely involved with multiple erythematous patches that had a

central clearing ranging from 4 to 15 cm in diameter (Figure 1). Findings on examination of his ears, nose, and throat were normal. There was no adenopathy in the neck and no evidence of meningeal irritation. His cardiovascular examination was normal. There was no abdominal tenderness, and there was no hepatosplenomegaly. No evidence of effusion, synovitis, or limitation of range of motion could be found on joint examination.

A clinical diagnosis of early disseminated Lyme disease was made based on the constellation of findings, including the typical erythema migrans rash. Therapy was initiated with oral amoxicillin 500 mg three times a day.

Initial laboratory studies showed evidence of hepatocellular dysfunction with elevation of direct and indirect bilirubin, aspartate aminotransferase, alanine aminotransferase, gamma-glutamyltranspeptidase, and alkaline phosphatase, as detailed in Table 1. Serologic testing for Lyme disease by polyvalent enzyme-linked immunosorbent assay was positive at a titer of 1:2560. Serologic testing for hepatitis A and B was negative.

A careful history obtained later revealed no known exposure to hepatitis, no history of transfusions, no intravenous drug use, and no homosexual activity. The patient had no history of liver or gall bladder disease. He drank alcoholic beverages infrequently. His only medication was verapamil 240 mg/d for hypertension.

After the 10th day of treatment the patient developed hives, presumed secondary to the antibiotic treatment. Accordingly, his medication was changed to oral doxycycline 100 mg twice a day, which was continued for an additional 21 days.

The patient's clinical picture showed quick resolution of the generalized symptoms following the initiation of treatment. The erythema migrans rash finally resolved after 2 weeks of treatment. Liver function abnormalities returned to near normal 3 weeks after the initial visit. On a follow-up examination 15 months after the initial presentation, no clinical evidence of any late se-

Submitted, revised, 6 February 1992.

From the Family Practice Residency Program, Middlesex Hospital, Middletown, CT. Address reprint requests to Keith Sinusas, M.D., Family Practice Residency Program, Middlesex Hospital, 90 South Main Street, Middletown, CT 06457.

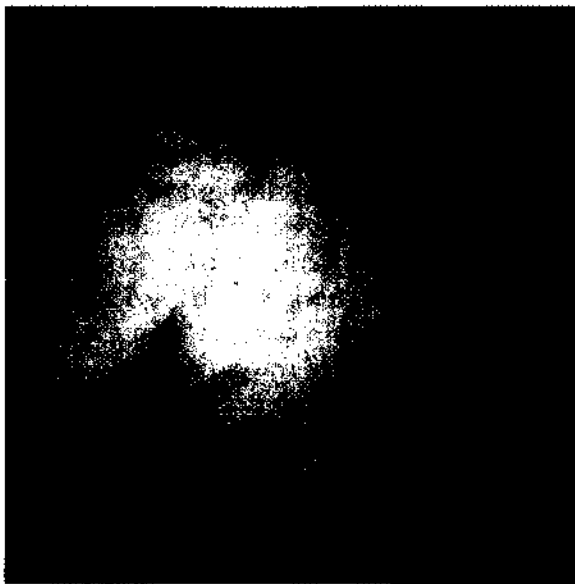


Figure 1. A patient with Lyme disease who has erythematous patches with central clearing, which is characteristic of erythema migrans.

quela of Lyme disease was found. Liver function tests at 15 months were normal except for minimal elevation of indirect bilirubin.

Discussion

This case is an excellent example of the hepatic involvement that can occur with Lyme borreliosis. Treatment of the underlying spirochetal in-

fection resulted in resolution of liver dysfunction in this patient. Since May 1989 we have observed hepatocellular dysfunction in 20 (27 percent) of 73 patients with documented early Lyme disease in whom liver function tests were performed (unpublished data). This case demonstrated the highest degree of liver involvement we have seen to date.

Liver dysfunction in Lyme disease was first reported by Steere, et al. in 1983,⁵ but in a search of the literature we found only three case reports of marked hepatic involvement with Lyme disease.⁷⁻⁹ None of these reported cases involved patients with early Lyme disease and erythema migrans, as does the case presented here. In two of the cases, the diagnosis was presumed because of positive serologic tests and a good response to antibiotic therapy.^{7,8} The third case was definite (although not early) Lyme disease because the spirochete was recovered from the liver. This patient also recovered after appropriate antibiotic treatment.⁹ No cases of fulminant hepatitis have been reported.

In patients who come to the office with early disseminated Lyme disease, characterized by multiple erythema migrans lesions and systemic symptoms, it is unclear whether further biochemical testing to uncover evidence of hepatic or other organ involvement is warranted. It is also not known whether patients with

Table 1. Laboratory Findings.

Test (normal values)	Initial	10 Days	21 Days	15 Months
Aspartate aminotransferase (AST/SGOT) (0 - 44 U/L)	161	28	31	24
Alanine aminotransferase (ALT/SGPT) (0 - 56 U/L)	428	88	76	40
Alkaline phosphate (26 - 140 IU/L)	339	149	98	77
Gamma-glutamyltranspeptidase (GGTP) (0 - 50 IU/L)	436	166	78	26
Bilirubin, total (0.1 - 1.2 mg/dL)	2.3	0.8	1.3	1.7
Bilirubin, direct (0.0 - 0.4 mg/dL)	0.7	0.1	0.1	0.1
Bilirubin, indirect (0.1 - 1.1 mg/dL)	0.6	0.7	1.2	1.6
Creatinine (0.6 - 1.7 mg/dL)	1.3			
Leukocyte (4,500 - 11,000/mm ³)	10,600			
Hematocrit (42 - 52%)	40.8			
Erythrocyte sedimentation rate, Westergren (0 - 15 mm/h)	66			
Lyme titer by ELISA (< 1:160)	1:2560			
Hepatitis B surface antigen (HBsAg) (negative)	Negative			
Antibody to hepatitis B core antigen (anti-HBc) (negative)	Negative			
Antibody to hepatitis A virus (anti-HAV) (negative)	Negative			

hepatic involvement have a longer or more serious illness.

Treatment of early disseminated Lyme disease should initially be with oral antibiotics, either doxycycline 100 mg twice a day for 21 days or amoxicillin 500 mg three times a day for 21 days. Parenteral antibiotics should be reserved for patients who do not respond to oral antibiotics or who manifest evidence of central nervous system involvement. When parenteral antibiotics are indicated, we recommend ceftriaxone 2 g intravenously once daily for 14 days.

Further study of hepatic dysfunction in Lyme disease is needed. Some of the important questions to be answered are (1) what is the typical clinical picture of the Lyme disease when a patient's liver is involved, (2) what are the ranges of liver function test abnormalities in such patients, (3) does hepatic involvement change the clinical course or outcome, and (4) when is further diagnostic testing indicated (e.g., sonography or screening for viral hepatitis)? Definitive answers to these questions will help physicians decide whether routine biochemical testing is, in fact, indicated for patients with Lyme disease.

It is well known that Lyme disease can present only as a flu-like illness with fever, malaise, and nausea.⁶ Viral hepatitis can also present in a similar fashion. It is logical therefore to include Lyme disease in the differential diagnosis of acute hepatitis in areas endemic for Lyme disease.

Physicians should be alert to the possibility of hepatic involvement with early Lyme disease. Based on current information in the published

literature and our experience in this endemic area, we recommend that patients with early disseminated Lyme disease and hepatic involvement be initially treated with oral antibiotics with the expectation of full recovery. Failure to respond to initial therapy might then be an indication for intravenous antibiotics and for a more detailed investigation into other possible causes of hepatic dysfunction.

References

1. Lyme disease — Connecticut. *MMWR* 1988; 37:1-3.
2. Dennis DT. Lyme disease. Tracking an epidemic. *JAMA* 1991; 266:1269-70.
3. Steere AC, Malawista SE, Snyderman DR, Shope RE, Andiman WA, Ross MR, et al. Lyme arthritis: an epidemic of oligoarticular arthritis in children and adults in three Connecticut communities. *Arthritis Rheum* 1977; 20:7-17.
4. Cartter ML, editor. Lyme disease in Connecticut. *Conn Epidemiol* 1990; 10(3):9-10.
5. Steere AC, Bartenhagen NH, Craft JE, Hutchinson GJ, Newman JH, Rahn DW, et al. The early clinical manifestations of Lyme disease. *Ann Intern Med* 1983; 99:76-82.
6. Steere AC. Lyme disease. *N Engl J Med* 1989; 321:586-96.
7. Chavanet P, Pillon D, Lancon JP, Waldner-Combernoux A, Maringe E, Portier H. Granulomatous hepatitis associated with Lyme disease. *Lancet* 1987; 2:623-4.
8. Goellner MH, Agger WA, Burgess JH, Duray PH. Hepatitis due to recurrent Lyme disease. *Ann Intern Med* 1988; 108:707-8.
9. Edwards KS, Kanengiser S, Li KI, Glassman M. Lyme disease presenting as hepatitis and jaundice in a child. *Pediatr Infect Dis J* 1990; 9:592-3.