

# The Bone Scan In Primary Care: Diagnostic Pitfalls

William F. Keenan, Jr., M.D., Lisa M. Fedullo, M.D., Marie E. Robb, M.D.,  
and Gary R. Plotkin, M.D.

**Abstract:** Skeletal scintigraphy (bone scanning) is a useful adjunct in the diagnosis of disease states, such as osteomyelitis, and in the evaluation of occult fractures. Certain conditions can alter the appearance of bone scans, such as age of the patient, prior use of antibiotics, concomitant diseases, and disruption of the vascular supply. Three patients whose clinical problems highlight diagnostic problems with bone scans are discussed. (J Am Board Fam Pract 1992; 5:63-67.)

Radiologists have long been aware of the limitations of plain film radiographs in the diagnosis of bone disease. Such films may be normal or inconclusive in several disorders, including fractures and osteomyelitis. Several radiolabeled pharmaceutical agents are available for skeletal scintigraphy; scintigrams made with such agents can supply information beyond that available with plain films.

Diphosphonates, compounds that are incorporated into metabolically active bone, can be labeled with technetium 99m to obtain high-quality scans. The three-phase scintiscan (indicating vascular, blood pool, and bone localization phases) is often used in skeletal imaging when osteomyelitis is suspected. Inflammatory diseases of the skeleton can also be studied with gallium citrate Ga 67 (which is concentrated in infected and malignant tissues by processes that are not fully understood) or indium 111-labeled leukocytes.

Unfortunately, there are few true "gold standards" in medicine, and nuclear scintigrams have their own limitations.<sup>1-4</sup> Excessive reliance on such studies can lead to serious errors. The patients described below had nuclear scintigrams that were believed not to show abnormalities when, in fact, disease was actually present. Difficulties with interpretation of nuclear scintigrams, as well as alternative imaging modalities, are discussed.

## Illustrative Cases

### Case 1

A 72-year-old man developed *Escherichia coli* sepsis, presumably from diverticulitis. He was treated with intravenous antibiotics, and his temperature and white cell count returned to normal; his abdominal complaints resolved. Soon after admission to the hospital, he complained of low back pain. Plain roentgenograms showed advanced degenerative joint disease but no other abnormality. A three-phase <sup>99m</sup>Tc-methylenediphosphonate scintigram was done 5 days after the onset of back pain (6 days after the diagnosis of sepsis) as his physician was concerned that the sepsis had seeded the vertebral bodies and that osteomyelitis was present.

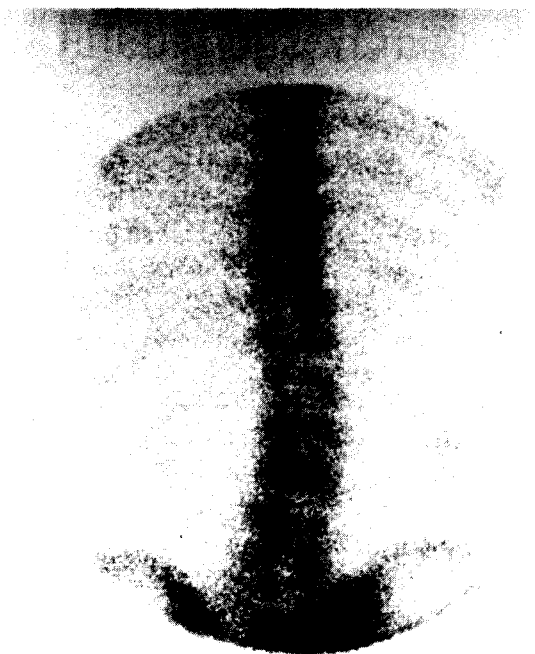
The changes seen on the scintigram (Figure 1) were thought to be compatible with his known osteoarthritis, and his physician assumed that his degenerative joint disease was responsible for his back pain. The patient was discharged home with outpatient physical therapy and nonsteroidal anti-inflammatory agents. His pain initially improved but shortly worsened and, within 2 weeks, the patient was rehospitalized. At this point, both plain films and computed tomography (Figure 2) showed marked destruction of his lower lumbar vertebral bodies by osteomyelitis. He has responded to aggressive antibiotic therapy but has persistent pain.

### Case 2

A 54-year-old man was admitted to the hospital with a 2-day history of fever, rigors, and back pain. Blood cultures were positive for *Staphylococcus aureus*. Plain roentgenograms and selected tomographic views showed hypertrophic osteoarthritic changes but no bone destruction. A

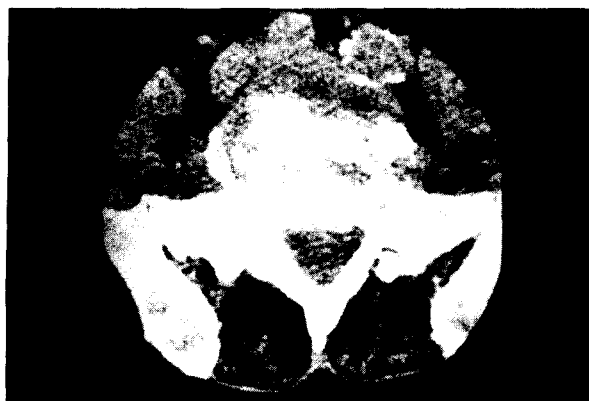Submitted, revised, 29 August 1991.

From the Family Practice Residency Program, The Williamsport Hospital and Medical Center, Williamsport, PA, and the Department of Radiology, St. Luke's Hospital, Bethlehem, PA. Address reprint requests to William F. Keenan, Jr., M.D., Department of Family Practice, Williamsport Hospital and Medical Center, 699 Rural Ave., Williamsport, PA 17701.



**Figure 1.** Technetium-99m scintigram of a 72-year-old man who has vertebral osteomyelitis. This scintigram was originally read as negative with changes compatible with known osteoarthritis.

three-phase  $^{99m}\text{Tc}$ -methylenediphosphonate bone scan performed 48 hours after admission failed to show any evidence of an infectious process. Computed axial tomography done on the 8th hospital day did not show any osteomyelitic process or any paravertebral soft-tissue changes. On the 14th day of hospitalization, a gallium scan



**Figure 2.** CT image of the patient in Figure 1 showing marked bone destruction 2 weeks later. Image is degraded by patient obesity.

(utilizing 3.6 mCi of gallium citrate Ga 67) was interpreted as normal.

Despite the above radiologic studies, clinical suspicion for an osteomyelitic process was high and intravenous antibiotic therapy was continued for a total of 8 weeks with slow resolution of the patient's back pain.

Roentgenograms done during follow-up finally showed destructive changes of the inferior portion of the fourth lumbar vertebra and the superior portion of the fifth lumbar vertebra, consistent with the clinical diagnosis of osteomyelitis.

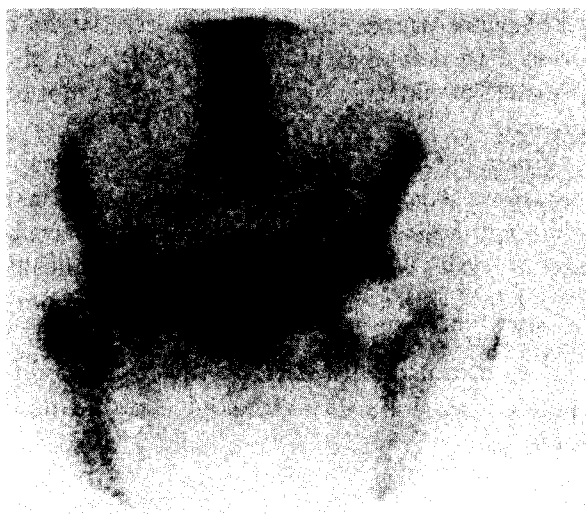### Case 3

A 91-year-old woman fell at home and injured her right hip. Her hospital examination showed only marked tenderness and diffuse muscle spasm about the hip. Plain roentgenograms showed marked degenerative joint disease but were otherwise nondiagnostic. A bone scintigram utilizing  $^{99m}\text{Tc}$ -methylenediphosphonate was done 24 hours after admission and showed changes, but these changes were believed to be consistent with the observed osteoarthritis (Figure 3). The patient could not tolerate physical therapy or attempts at ambulation. Repeat plain films 1 week later showed no major change. Because clinical suspicion for an occult fracture was high, tomography was done on the 9th day of hospitalization and clearly showed a healing nondisplaced fracture line through the right femoral neck (Figure 4).

### Discussion

The increase in metabolic activity associated with infection or fracture repair results in concentration of radiopharmaceutical agents. Thus, abnormalities can be visualized by scintigraphy when plain films show no changes or when changes are masked by other processes. As our experience with the above patients shows, however, such scans cannot be relied upon in all cases.

Because routine scintigrams are nonspecific, different disease processes can produce similar appearing abnormalities. As examples, the increased uptake that occurs with degenerative joint disease or Paget disease can mask other abnormalities. In fact, the presence of such abnormalities can give rise to a falsely positive scan. The osteoarthritis seen in patients 1 and 3 may have hidden other abnormalities. It is important



**Figure 3.** A “negative” technetium-99m scintigram of 91-year-old patient who was thought to have a hip fracture. Mild increase in activity on the patient’s right side (left side of scan) was thought to be compatible with the marked degenerative changes seen on plain roentgenograms.

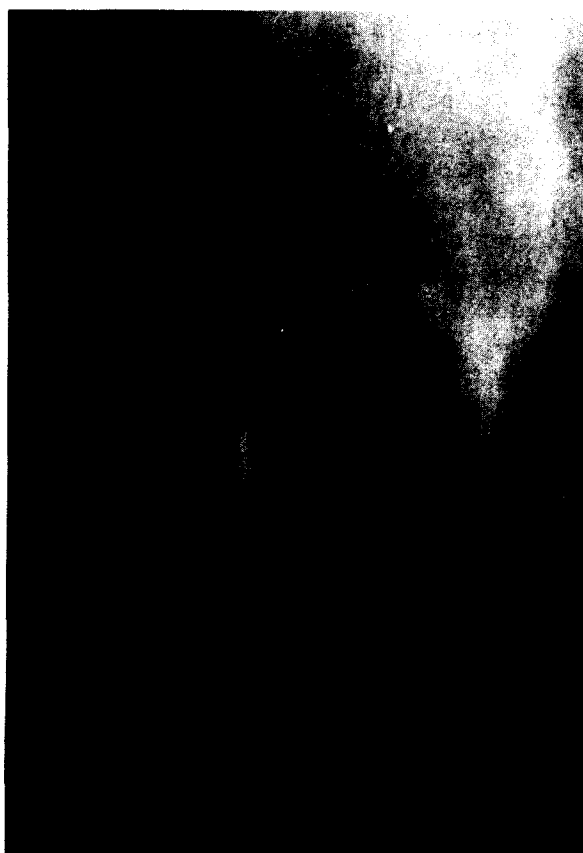
that an adequate differential diagnosis be made; to do so often requires good communication between the radiologist and primary care physician.

Recent advances in computer technology and camera technology have given rise to single photon emission computed tomography (SPECT), which improves spatial resolution and image contrast compared with classical planar imaging and is less likely to be distorted by nearby disease processes. SPECT imaging promises to play an increasingly important role in the diagnosis of bone abnormalities.<sup>5,6</sup> As in any new technology, SPECT equipment is not available in many hospitals, and several third-party payers regard it as still experimental (and thus nonreimbursable).

Even SPECT scintigrams, however, depend upon the delivery of tracer to the diseased organ, which in turn depends upon an intact vascular supply. A partial disruption of this supply, as can result from edema of the marrow space (e.g., in infection) or traumatic injury, can prevent the expected increase in activity from occurring. In fact, complete disruption of the vascular supply will result in a “cold spot,” which itself is abnormal and has a certain amount of prognostic significance in certain disease states, such as fracture of the femoral head and avascular necrosis.<sup>4,7-9</sup>

The development of abnormal findings on a scintigram is also time-dependent in that a certain amount of time must elapse before abnormalities can be seen. In experimental osteomyelitis in rabbits, abnormal findings were noted on a little more than one-half of the bone scans 5 days after injection of *Staphylococcus aureus*, while most scintiscans showed abnormal findings by day 10.<sup>10</sup> In cases 1 and 2, repeat testing within 48 hours might have shown evidence of infection.

The same appears to hold true for fractures. Elderly patients seem to pose greater diagnostic challenges than younger patients. It has been estimated that abnormal findings are evident on 95 percent of bone scintigrams 1 day after a fracture and on almost 100 percent of the scintigrams within 3 days in patients aged less than 65 years, but in patients aged more than 65 years, the corresponding percentages are 80 to 95 percent, re-



**Figure 4.** Tomograms through the right femoral neck taken 1 week after the scintigram in Figure 3. A nondisplaced fracture through the femoral head can be seen.

spectively.<sup>11</sup> Thus, the testing performed on our 3rd patient simply may have been done too early. The optimal time to do such scans is unknown, but in one study of 693 elderly patients with suspected hip fractures, 43 had nondiagnostic findings on plain films. Scintigraphy with technetium 99m was done at 48 hours, and the results were abnormal in 13 patients, all of whom were later proved to have fractures. None of the patients with unremarkable scintigrams at 48 hours went on to develop problems.<sup>12</sup>

Even when there is sufficient time allowed for abnormalities to develop, the scintigram using technetium 99m can still be nondiagnostic. Although, in general, radioactive technetium scintigraphy is very sensitive, published estimates of its sensitivity in various disease states vary; it appears that younger patients, especially neonates, are more likely to have false-negative results on a scintigram. Scanning with radioactive gallium has been proposed as an adjunctive study in difficult cases,<sup>3,13</sup> but as in our 2nd patient, it can give false-negative results. One reason may be the inhibition of inflammation from partial treatment with antibiotics, a factor that can partly explain the decreased reaction seen on the scans of patients in cases 1 and 2.

Alternate imaging modalities, such as tomography, computed tomography (CT), and magnetic resonance imaging (MRI), are available to the clinician, but they, too, have their limitations. Because of artifacts induced by metal rods and pins, distortions of the image can make both CT and MRI less reliable in postsurgical patients. Both CT contrast material and gadolinium, the contrast agent available in MRI, can enhance images, but they also depend on an intact vascular supply.

A small number of studies have compared CT and MRI with scintigraphy. In general, scintigraphy is probably the most sensitive but the least specific of the three modalities.<sup>14,17</sup> With improvements in technology, some investigators believe that MRI is now the modality of choice in certain situations, such as diseases of the hip and infections of the spine.<sup>18,19</sup>

As the 1st case illustrates, reliance on supposedly negative findings can lead to near disastrous results for the patient. Unfortunately, in this era of diagnostic-related groups and of oversight by

third-party payers, the physician can be hard-pressed to defend treatment strategy when the presence of clinically suspected disease cannot be proved.

Finally, advances in imaging are occurring rapidly. Careful clinicians might wish to consult their radiology colleagues about which of the available modalities is most likely to be clinically useful in a given circumstance. Because abnormalities noted on scintigraphy can be due to a variety of causes, discussion of the possible differential diagnosis with radiologic consultants is important.

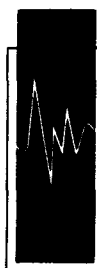## References

1. Wald ER, Mirro R, Gartner JC. Pitfalls in the diagnosis of acute osteomyelitis by bone scan. *Clin Pediatr* 1980; 19:597-601.
2. Berkowitz ID, Wenzel W. "Normal" technetium bone scans in patients with acute osteomyelitis. *Am J Dis Child* 1980; 134:828-30.
3. Handmaker H. Acute hematogenous osteomyelitis: has the bone scan betrayed us? *Radiology* 1980; 135:787-9.
4. Schlaeffer F, Mikolich DJ, Mates SM. Technitium Tc-99m diphosphonate bone scan; false-normal findings in elderly patients with hematogenous vertebral osteomyelitis. *Arch Intern Med* 1987; 147: 2024-6.
5. Collier BD Jr, Hellman RS, Krasnow AZ. Bone SPECT. *Semin Nucl Med* 1987; 17:247-66.
6. Weber DA. Options in camera technology for the bone scan: role of SPECT. *Semin Nucl Med* 1988; 18:78-89.
7. O'Mara RE, Wilson GA, Burke AM. The role of nuclear imaging in osteomyelitis. In: Raynaud C, editor. *Nuclear medicine and biology, proceedings of the third world congress of nuclear medicine and biology I*. Paris: Pergamon Press, 1982:1094-6.
8. Rosenthal L, Lisbona R. Role of radionuclide imaging in benign bone and joint diseases of orthopedic interest. In: Freeman LM, Weissman HS, editors. *Nuclear medicine annual*. New York: Raven Press, 1980:267-301.
9. Bauer G, Weber DA, Cedar L, Darte L, Egund N, Hansson LI, et al. Dynamics of Tc-99m methylenediphosphonate imaging of the femoral head after hip fracture. *Clin Orthop* 1980; 152:85-92.
10. Risky L, Goris ML, Schurman DJ, Nagel DA. 99-technetium bone scanning in experimental osteomyelitis. *Clin Orthop* 1977; 128:361-6.
11. Mettler FA Jr, Guiberteau MJ. *Essentials of nuclear imaging*. 2nd ed. Orlando: Grune & Stratton, 1985:269-72.
12. Fairclough J, Colhoun E, Johnston D, Williams LA. Bone scanning for suspected hip fractures. A pro-

- spective study in elderly patients. *J Bone Joint Surg* 1987; 69:251-3.
13. Handmaker H, O'Mara RE. Gallium imaging in pediatrics. *J Nucl Med* 1977; 18:1057-63.
  14. Modic MT, Pflanze W, Feiglin DH, Belhobek G. Magnetic resonance imaging of musculoskeletal infections. *Radiol Clin North Am* 1986; 24: 247-58.
  15. Beltran J, McGhee RB, Shaffer PB, Olsen JO, Bennett WF, Foster TR, et al. Experimental infections of the musculoskeletal system: evaluation with MR imaging and Tc-99m MDP and Ga-67 scintigraphy. *Radiology* 1988; 167:167-72.
  16. Unger E, Moldofsky P, Gatenby R, Hartz W, Broder G. Diagnosis of osteomyelitis by MR imaging. *AJR* 1988; 150:605-10.
  17. Beltran J, Noto AM, McGhee RB, Freedy RM, McCalla MS. Infections of the musculoskeletal system: high-field-strength MR imaging. *Radiology* 1987; 164:449-54.
  18. Miller GM, Forbes GS, Onofrio BM. Magnetic imaging of the spine. *Mayo Clin Proc* 1989; 64: 986-1004.
  19. Musculoskeletal applications of magnetic resonance imaging. Council on Scientific Affairs. *JAMA* 1989; 262:2420-7.

# To Someone Who Stutters, It's Easier Done Than Said.

The fear of speaking keeps many people from being heard. If you stutter or know someone who does, write for our free informative brochures on prevention and treatment of stuttering.



**STUTTERING  
FOUNDATION  
OF AMERICA**

FORMERLY SPEECH FOUNDATION OF AMERICA

*A Non-Profit Organization*

*Since 1947 —*

*Helping Those Who Stutter*

P.O. BOX 11749 • MEMPHIS, TENNESSEE 38111-0749