

Sinusoidal Fetal Heart Rate Pattern After Administration Of Nalbuphine

William Zeller, M.D., Jana Kueck, R.N., and Glenda Tennis, R.N.

Feinstein, et al.¹ described a sinusoidal fetal heart pattern occurring minutes after the intravenous administration of nalbuphine to a patient in labor. This pattern lasted 2 hours 15 minutes; the infant was subsequently delivered by Cesarean section, apparently because of late decelerations that were reported, but not illustrated, in their report. The baby, a 4564-g (10 lb, 3 oz) girl, had Apgar scores of 8 and 9 at 1 and 5 minutes, respectively, and both mother and baby had an uneventful postpartum course.

Because sinusoidal fetal heart patterns have been associated with severe fetal distress, their occurrence creates apprehension among obstetric attendants; in the Feinstein report and in our case, however, the infants had no distress at birth. In addition, there was a definite association between the quality of the labor and the administration of nalbuphine.

Case Report

A 27-year-old woman at term, gravida 1, who had had a normal prenatal course, arrived at the hospital in active labor with intact membranes. Her cervix was dilated 2 cm. After 7 hours of ineffectual contractions, augmentation with oxytocin was instituted. During this period and for the next 5 hours, fetal heart rate monitoring showed a normal reactive pattern. The patient's cervix had dilated to 8 cm after 12 hours of labor, but the fetal vertex remained high at -2 station. At this point, the patient was acutely uncomfortable, and 10 mg of nalbuphine (Nubain™) was administered intravenously. Approximately 13 minutes later, a sinusoidal pattern appeared on the external fetal heart monitor (Figure 1). Nasal oxygen was administered, the patient was placed in the left lateral decubitus position, and the oxytocin was discontinued immediately. A sonogram

showed a normal placenta with no evidence of abruption or previa. An umbilical artery flow velocity study was performed, as described by Ferrazzi, et al.,² and showed a normal pulsatility index. The sinusoidal pattern continued for 56 minutes (accompanied by normal maternal blood pressure, pulse, and respiratory measurements) and then ended abruptly (Figure 2). Labor was allowed to continue for another 2 hours until the cervix was completely dilated, but the fetal vertex failed to descend beyond -2 station. A Cesarean section was performed, and the mother was delivered of a healthy 3808-g (8 lb, 8 oz) baby girl, who had Apgar scores of 5 and 9 at 1 and 5 minutes, respectively. The Apgar score of 5 at 1 minute was attributed to the general anesthesia given for the Cesarean section. Spinal anesthesia was attempted but was unsuccessful. Both mother and baby had an uncomplicated hospital stay.

Comment

Nalbuphine is a synthetic narcotic agonist-antagonist that is similar to morphine sulfate in its ability to relieve pain on a milligram-to-milligram basis. When compared with morphine and meperidine, two other narcotics used in obstetrics, its alleged advantage is that after 20 mg are administered, further doses will not depress a patient's respiratory center in the brain. The side

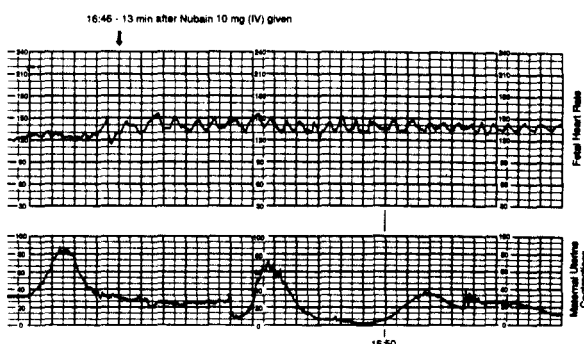


Figure 1. Onset of sinusoidal pattern. Nasal oxygen was administered at 4 l/min, and patient was placed in a left lateral decubitus position at 16:50.

From the Department of Obstetrics and Family Practice, Skaggs Community Hospital, Branson, MO. Address reprint requests to William Zeller, M.D., P.O. Box 1306, Branson, MO 65616.

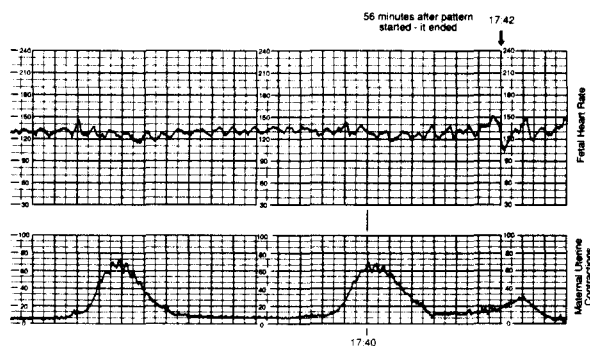


Figure 2. End of sinusoidal pattern.

effects, in addition to respiratory depression, that occur in a fetus are unknown.

Historically, the sinusoidal pattern has almost always been associated with severe fetal distress, severe fetal anemia, and sometimes fetal death. In 1978, Gal, et al.³ reported two cases of sinusoidal pattern; one fetal death occurred, and the other severely depressed infant required resuscitation. It was these authors' opinion that a sinusoidal pattern on a fetal monitor indicated severe fetal distress and mandated prompt delivery. Others, such as Rochard, et al.,⁴ have reported similar cases and speculated that the sinusoidal pattern represents an absence of central nervous system control over the heart, signaling the end stage of fetal distress.

Our case appears to be the second published report of sinusoidal fetal heart rate pattern associated with the use of nalbuphine. In both instances, a healthy infant was delivered showing no

evidence of neonatal distress or catastrophic event. It is also interesting that both mothers had labors that were ineffectual. Nalbuphine may exert some effect on the vagal tone of the fetal cardiac conducting system or on the central nervous system control over the heart that is now of unknown clinical importance. We have continued to use nalbuphine analgesia in labor without any adverse effects and believe that this drug represents a good alternative to morphine and meperidine. We report this case, however, so that others who observe a sinusoidal pattern soon after nalbuphine administration can assess fetal well-being with umbilical artery velocities or scalp pH before assuming that severe fetal distress is present.

References

1. Feinstein SJ, Lodeiro JG, Vintzileos AM, Campbell WA, Montgomery JT, Nochimson DJ. Sinusoidal fetal heart rate pattern after administration of nalbuphine hydrochloride: a case report. *Am J Obstet Gynecol* 1986; 154:159-60.
2. Ferrazzi E, Pardi G, Bauscaglia M, Marconi AM, Gomenti B, Bellotti M, et al. The correlation of biochemical monitoring versus umbilical flow velocity measurements of the human fetus. *Am J Obstet Gynecol* 1988; 159:1081-7.
3. Gal D, Jacobson LM, Ser H, Park SA, Tanger ML. Sinusoidal pattern: an alarming sign of fetal distress. *Am J Obstet Gynecol* 1978; 132:903-5.
4. Rochard F, Schiffrin BS, Goupil F, Legrand H, Blottiere J, Sureau C. Nonstressed fetal heart rate monitoring in the antepartum period. *Am J Obstet Gynecol* 1976; 126:699-706.