J Am Board Fam Med: first published as 10.3122/jabfm.2022.220143R1 on 9 February 2023. Downloaded from http://www.jabfm.org/ on 20 April 2024 by guest. Protected by copyright.

ORIGINAL RESEARCH

Expert Consensus Statement on Proficiency Standards for Dermoscopy Education in Primary Care

Tiffaney Tran, BS, Peggy R. Cyr, MD, MS, Alex Verdieck, MD, Miranda D. Lu, MD, Hadjh T. Ahrns, MD, Elizabeth G. Berry, MD, William Bowen, MD, Ralph P. Braun, MD, Joshua M. Cusick-Lewis, MD, Hung Q. Doan, MD, PhD, Valerie L. Donohue, MD, Deborah R. Erlich, MD, MMedEd, Laura K. Ferris, MD, PhD, Evelyne Harkemanne, MD, Rebecca I. Hartman, MD, MPH, James Holt, MD, Natalia Jaimes, MD, Timothy A. Joslin, MD, Zhyldyz Kabaeva, MD, Tracey N. Liebman, MD, Joanna Ludzik, MD, PhD, Ashfaq A. Marghoob, MD, Isac Simpson, DO, Jennifer A. Stein, MD, PhD, Daniel L. Stulberg, MD, Isabelle Tromme, MD, PhD, Matthew J. Turnquist, MD, Richard P. Usatine, MD, Alison M. Walker, MD, Bryan L. Walker, MD, Robert F. West, MD, MMed, Megan L. Wilson, MD, Alexander Witkowski, MD, PhD, Dominic J. Wu, MD, Elizabeth V. Seiverling, MD, and Kelly C. Nelson, MD

Background: **Primary care providers (PCPs) frequently address dermatologic concerns and perform skin examinations during clinical encounters. For PCPs who evaluate concerning skin lesions, dermoscopy (a noninvasive skin visualization technique) has been shown to increase the sensitivity for skin cancer diagnosis compared with unassisted clinical examinations. Because no formal consensus existed on the fundamental knowledge and skills that PCPs should have with respect to dermoscopy for skin cancer detection, the objective of this study was to develop an expert consensus statement on proficiency standards for PCPs learning or using dermoscopy.**

Methods: **A 2-phase modified Delphi method was used to develop 2 proficiency standards. In the study's first phase, a focus group of PCPs and dermatologists generated a list of dermoscopic diagnoses and associated features. In the second phase, a larger panel evaluated the proposed list and determined whether each diagnosis was reflective of a foundational or intermediate proficiency or neither.**

Results: **Of the 35 initial panelists, 5 PCPs were lost to follow-up or withdrew; 30 completed the fifth and last round. The final consensus-based list contained 39 dermoscopic diagnoses and associated features.**

Conclusions: **This consensus statement will inform the development of PCP-targeted dermoscopy training initiatives designed to support early cancer detection. (J Am Board Fam Med 2023;36:25–38.)**

Keywords: **Continuing Medical Education, Delphi Method, Dermoscopy, Expert Opinion, Focus Groups, General Practitioners, Melanoma, Primary Care Physicians, Primary Health Care, Skin Cancer**

Background

Skin cancer is the most common cancer in the United States, and the 3 major types are basal cell carcinoma (BCC), squamous cell carcinoma (SCC), and melanoma. While most BCCs and SCCs are treatable and curable, melanoma is fatal when

This article was externally peer reviewed.

Submitted 8 April 2022; revised 16 August 2022; accepted 17 August 2022.

From the Department of Dermatology, The University of Texas MD Anderson Cancer Center, Houston (TT, HQD, KCN); Department of Family Medicine, Maine Medical Center, Portland (PRC, HTA); Department of Family Medicine, Tufts University School of Medicine, Boston, MA (PRC, DRE); Department of Family Medicine, Oregon Health & Science University School of Medicine, Portland (AV, TAJ); Swedish First Hill Family Medicine Residency, Seattle, WA (MDL); Department of Dermatology, Oregon Health & Science University School of Medicine, Portland (EGB, JL, AW); Christus St. Vincent Family Medicine Center, Sante Fe, NM (WB); Department of Dermatology, University Hospital of Zürich, University of Zürich, Zürich,

detected at advanced stages.[1,2] Delays in diagnosis and treatment can be caused by lack of timely recognition exacerbated by poor access to dermatology specialists for evaluation of skin lesions. In the United States, these access disparities occur along the lines of patient socioeconomic status, race/ethnicity, and rural residence.[3,4] In regions with barriers to dermatology access, trained primary care providers (PCPs) including advanced practice practitioners, such as physician assistants and nurse practitioners, play an important role in the detection, diagnosis, and management of skin cancer.[5]

For the early detection of skin cancer, clinical skin examinations are 1 of the safest and most cost-effective screening interventions available to patients.[6] Skin examinations may be performed unassisted (with the naked eye) or with dermoscopy, a visualization technique involving use of a dermatoscope. A dermatoscope is a handheld instrument consisting of a magnifier and a polarized light source that enables detailed examination of surface and subsurface features not discernible by the naked eye.[7] Dermoscopy use results in a higher diagnostic accuracy for melanoma detection compared with unassisted examinations.[8] In a large meta-analysis of 104 published studies, dermoscopy was shown to significantly improve both the sensitivity and specificity for melanoma diagnosis when compared with visual inspection alone.[9] This significantly reduces the number of melanomas overlooked and the number of benign lesions unnecessarily biopsied in the course of identifying melanoma, reducing patient morbidity and mortality.

On the frontline of health care delivery, PCPs frequently address dermatologic problems and perform skin examinations,[10] and an estimated 12% to 25% of primary care encounters address a patient's dermatologic problem.[11,12] In a population-based study, 65.1% of patients presenting to their PCPs with skin-related issues did not seek further dermatologic care from a dermatologist or other health care provider that year.[11] For patients at risk for skin cancer, each of these encounters in the primary care setting represents an opportunity to detect skin cancer at an early stage.

Among PCPs who treat skin conditions, appropriate training in the dermoscopic evaluation of skin lesions has been shown to improve their diagnostic sensitivity for skin cancer, including melanoma.[13–17] To gain proficiency in dermoscopy, clinicians must become familiar with the dermoscopic features (eg, colors, structures, patterns) of common dermatologic diagnoses.[18] The recognition of these features supports a clinician's decision of whether to biopsy, refer, or offer reassurance.

Before this study, no formal consensus existed on the fundamental competencies that PCPs should have with respect to dermoscopy for skin cancer detection.[19,20] While a foundational dermoscopy proficiency standard has been developed for dermatology residents,[21] the practice needs of PCPs differ from those of dermatologists, warranting a focused effort tailored to the primary care context. Therefore, the objective of this study was to develop an expert consensus statement on proficiency standards for PCPs learning or using dermoscopy.

To achieve this, the research team coordinated a modified Delphi exercise, an iterative method commonly used to obtain consensus opinion from a group of subject matter experts.[22,23] For each proficiency standard, the expert panel determined which diagnoses and features are important for PCPs to identify, informing learner expectations for dermoscopy educators. In seeking agreement on specific competencies, this study will also establish content validity[24] for PCP-targeted dermoscopy training programs and proficiency assessments.

Methods

Study Design

This study received approval from the MD Anderson Cancer Center Institutional Review Board (Protocol #2020-0667). The consensus process, as shown in Figure 1, used a 2-phase modified Delphi method for both the diagnoses and features stages. In the first phase, a smaller focus group

Switzerland (RPB); Cabin Creek Health Systems, Dawes, WV (JMC-L); Lincoln Medical Partners, Damariscotta, ME (VLD); Department of Dermatology, University of Pittsburgh Medical Center, Pittsburgh, PA (LKF); Dermatology Department, Cliniques Universitaires Saint-Luc, Brussels, Belgium (EH); Institute of Experimental & Clinical Research, Université Catholique de Louvain, Brussels, Belgium (EH); Department of Dermatology, Brigham and Women's Hospital, Boston, MA (RIH); Melanoma Program, Dana-Farber Cancer Institute, Boston, MA (RIH); Veterans Integrated Services Network, Jamaica Plain, MA (RIH); Department of Family Medicine, East Tennessee State University James H. Quillen College of Medicine, Johnson City, TN (JH); Dr. Phillip Frost Department of Dermatology and Cutaneous Surgery, University of Miami Miller School of Medicine, Miami, FL

J Am Board Fam Med: first published as 10.3122/jabfm.2022.220143R1 on 9 February 2023. Downloaded from http://www.jabfm.org/ on 20 April 2024 by guest. Protected by copyright.

Figure 1. Consensus process using a 2-phase modified Delphi method.

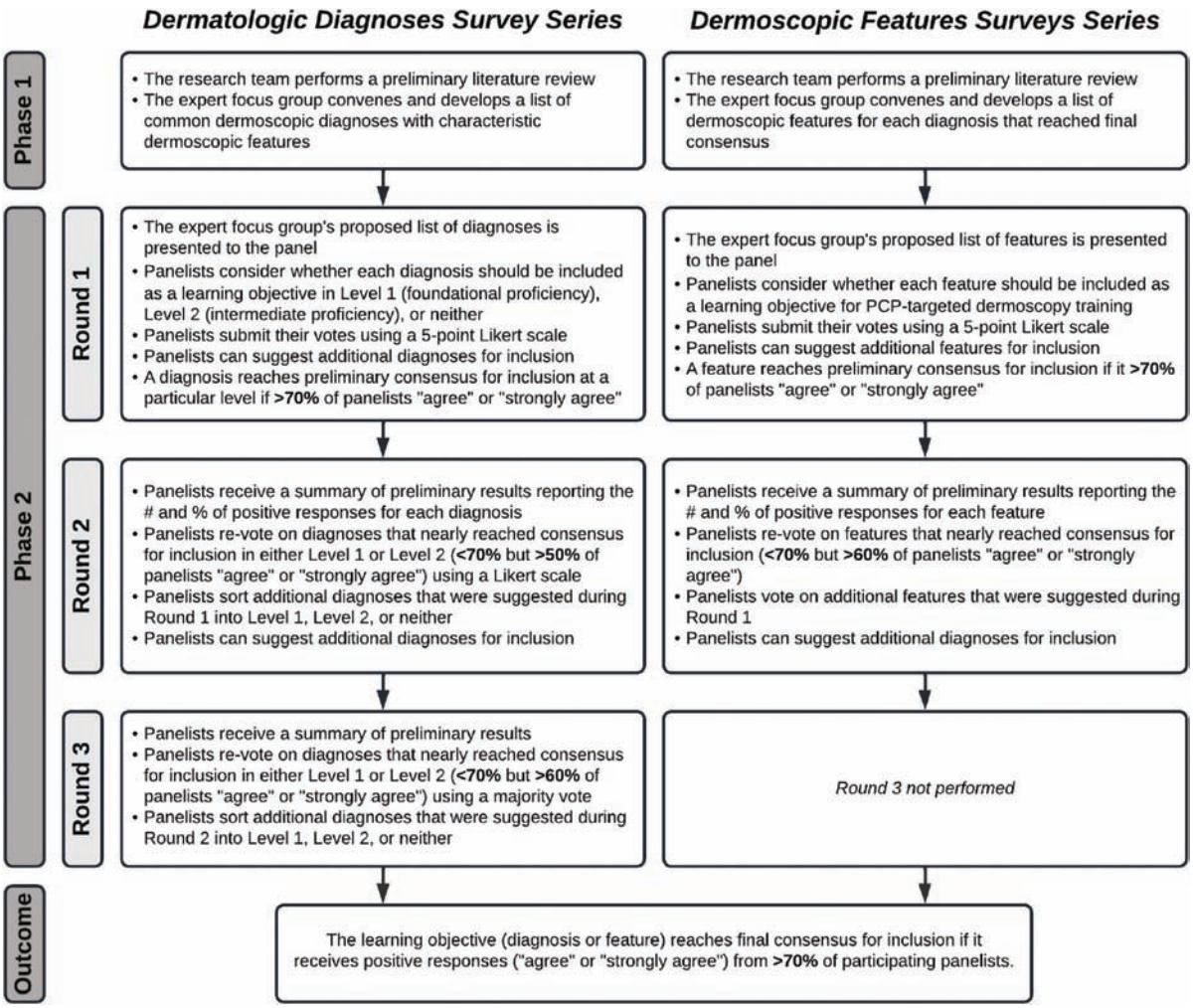

generated a preliminary statement, and in the second phase, a larger panel refined the proposed statement through a controlled feedback process.[21] This structured method guarantees that outcomes most closely represent the collective viewpoints of the group.[22,23] To ensure anonymity of panelists, the research team administered electronic surveys using the web-based platform REDCap (Version 12.2.6, Vanderbilt University, Nashville, TN).

This consensus process was organized as 2 successive stages: (1) a diagnoses survey series, and (2) a features survey series. To steer the consensus process, a focus group of 5 experts was assembled: 3 PCPs (PRC, AV & MDL) who routinely use dermoscopy in clinical practice and 2 pigmented lesion experts (EVS & KCN) who are highly engaged in PCP dermoscopy training initiatives. The focus group convened virtually before each survey series to propose, discuss, and approve survey items.

For the diagnoses survey series, the objective was to create an expert-approved list of common dermatologic diagnoses with characteristic

(NJ); Sylvester Comprehensive Cancer Center, Miami, FL (NJ); Department of Internal Medicine, Maine Medical Center, Cape Elizabeth, ME (ZK); The Ronald O. Perelman Department of Dermatology, New York University Grossman School of Medicine, New York (TNL, JAS); Department of Telemedicine and Bioinformatics, Jagiellonian University Medical College, Krakow, Poland (JL); Dermatology Service, Memorial Sloan Kettering Cancer Center, New York, NY (AAM); Simpson DermCare & Family Medicine, Ammon, ID (IS); Department of Family & Community Medicine, University of New Mexico School of Medicine, Albuquerque (DLS); Dermatology Department, King Albert II Cancer and Hematology Institute, Cliniques Universitaires Saint-Luc, Brussels, Belgium (IT); Department of Family Medicine, Millinocket Regional Hospital, Millinocket, ME (MJT); Western Maine

J Am Board Fam Med: first published as 10.3122/jabfm.2022.220143R1 on 9 February 2023. Downloaded from http://www.jabfm.org/ on 20 April 2024 by guest. Protected by copyright.

dermoscopic features that should be included in dermoscopy training for PCPs. In the initial round, the panel reviewed a proposed list of diagnoses developed by the focus group. Most items on the list were drawn from a prior modified Delphi study that generated a foundational dermoscopy proficiency standard for dermatology residents.[21] Contributors to this prior effort included members of the Melanoma Prevention Working Group–Pigmented Lesion Subcommittee (MPWG-PLS, affiliated with the Southwest Oncology Group and the Eastern Cooperative Oncology Group–American College of Radiology Imaging Network) and other pigmented lesion experts.[21]

The proposed list was divided into 5 categories: nonmelanocytic lesions, benign melanocytic lesions, melanoma, special sites, and other diagnoses such as skin infections and infestations.[21] This last category encompassed additional diagnoses (eg, verruca, molluscum contagiosum) that PCPs frequently encounter in clinical practice. Given the range of interest in and engagement with dermoscopy among PCPs, panelists were asked to assign each diagnosis to 1 of the following 3 options:

- Level 1 (foundational): Clinicians who desire a basic yet practical understanding of dermoscopy and its application for skin cancer detection should be able to recognize these diagnoses with basic training.
- Level 2 (intermediate): More experienced clinicians who are highly interested in learning dermoscopy beyond level 1 should be able to recognize these diagnoses. With adequate training, recognition of these "above and beyond" diagnoses would demonstrate an additional level of mastery beyond level 1. Diagnoses that do not reach consensus for inclusion in level 1 may be considered for inclusion in level 2.
- Neither level 1 nor level 2: Recognition of these diagnoses using dermoscopy would not reflect either foundational or intermediate dermoscopy proficiency for PCPs. This may include diagnoses that are extremely rare in the population or that are especially challenging to diagnose, even by advanced dermoscopy users.

For each diagnosis, panelists rated how strongly they agreed or disagreed (via a 5-point Likert scale) with its inclusion in level 1, level 2, or neither. Panelists were also able to provide written feedback or suggest additional diagnoses to be presented in the next round. In subsequent rounds, panelists rerated diagnoses that nearly reached consensus for inclusion at a particular level (positive responses from >50% to 60% but <70% of participating panelists). Panelists also assigned additional diagnoses to level 1, level 2, or neither. Three formal rounds of surveys were performed between October and December 2021 until all diagnoses received a consensus-based assignment.

For the features survey series, the objective was to develop an expert-approved list of dermoscopic features for each included diagnosis. The aim was to capture features that are highly characteristic and important to recognize and that should be included in PCP dermoscopy education. Commonly seen structures may be included even if not specific to that diagnosis.

Based on a literature review, a proposed list of features was developed by the steering committee and presented to the panel. References for this list included the MPWG-PLS consensus on dermoscopy proficiency expectations for dermatology residents,[21] the Dermoscopedia website,[25] the 2016 International Dermoscopy Society consensus on dermoscopy terminology,[26] the International Skin Imaging Collaboration dictionary of standardized terms, and other medical literature on PubMed, as documented in the online appendices.

For each feature, panelists rated on a 5-point Likert scale how strongly they would agree or disagree with its inclusion in dermoscopy training for primary care. Panelists were also able to propose wording modifications or suggest additional features. In the subsequent round, panelists rerated features that nearly reached consensus (positive responses from >60% but <70% of participating

Primary Care, Norway (MJT); Department of Dermatology & Cutaneous Surgery, Department of Family & Community Medicine, The University of Texas Health Science Center at San Antonio, San Antonio, TX (RPU); Brigham and Women's Health Care Center, Pembroke, MA (AMW); South Shore Medical Center, Norwell, MA (BLW); Redirect Health, Glendale, AZ (RFW); Department of Family Medicine, University of Washington School of Medicine, Seattle (MLW); Department of Dermatology, University of Kansas Medical Center, Kansas City (DJW); Division of Dermatology, Maine Medical Center, Portland (EVS); Department of Dermatology, Tufts University School of Medicine, Boston, MA (EVS)

Funding: This project was supported in part by the generous philanthropic contributions of the Lyda Hill Foundation to the University of Texas MD Anderson

J Am Board Fam Med: first published as 10.3122/jabfm.2022.220143R1 on 9 February 2023. Downloaded from http://www.jabfm.org/ on 20 April 2024 by guest. Protected by copyright.

panelists) and rated additional features. Two formal rounds of features surveys were performed between December 2021 and February 2022.

On the conclusion of each round, all responses were deidentified, and data analyses were performed using REDCap and Microsoft Excel. Panelists received a summary of the preliminary results that reported the percentage of positive responses for each diagnosis. These results summaries were intended to inform panelists' decisions in subsequent rounds.

Each specific item that reached final consensus for inclusion received positive responses (defined as selection of "strongly agree" or "agree" on the Likert scale) from >70% of participating panelists. This threshold criterion was derived from the MPWG-PLS's consensus process that used a similar 2-phase modified Delphi method.[21] Features that received >50% but <70% positive responses were not formally included in the final consensus statement but were labeled as "optional to include" for PCP-targeted dermoscopy training.

Panel Recruitment

Through known professional networks, 40 subject matter experts were invited to join the panel: 25 PCPs (23 family medicine physicians and 2 internal medicine physicians) who routinely use dermoscopy in clinical practice and 15 dermatologists. Of the 15 invited dermatologists, most are directly involved in dermoscopy education and skin cancer detection training for PCPs, and 2 previously worked in primary care.

At the beginning of each survey, panelists reviewed and acknowledged a consent statement. No monetary compensation for panel participation was offered. For both survey series, copies of the consent statement, survey instruments, and results summaries can be found in the online appendices.

Results

Panelist Demographics

Of the 40 active physicians invited to join the panel, 35 (87.5%) participated in the initial round (Table 1). Of these 35, 21 (60.0%, 19 family medicine physicians and 2 internal medicine physicians) were PCPs (76.2% response rate), and the remaining 14 (40.0%) were dermatologists (93.3% response rate). Sixteen of the initial panelists (45.7%) reported specializing in pigmented lesions, dermoscopy, or melanoma as an attending physician. Of these 16, 3 were PCPs (2 family medicine physicians and 1 internal medicine physician), while the remainder were dermatologists. A majority (62.9%) reported being directly involved in dermoscopy training for primary care, offering training in the clinic and/or through lectures.

Over the course of the study, 5 PCPs were lost to follow-up or withdrew from the study. Of the 30 who completed the fifth and last round, 16 (53.3%, 14 family medicine physicians and 2 internal medicine physicians) were PCPs (76.2% retention rate), and 14 (46.7%) were dermatologists (100% retention rate).

Survey Results

The consensus process involved 2 successive survey series: (1) diagnoses, and (2) features. In the diagnoses survey series, panelists voted on a total of 51 diagnoses (Table 2). Of this total, 15 represented additional diagnoses written in by panelists, and 39 received >70% positive responses and reached final consensus for inclusion (13 in level 1 and 26 in level 2).

In the features survey series, panelists voted on the inclusion of different dermoscopic features for each included diagnosis. A summary of the features survey results—organized into the categories of nonmelanocytic lesions, benign melanocytic lesions, melanoma, special sites, and other diagnoses—is included in Tables 3-7. Of the 156 total features surveyed, 6 represented additional features written in by panelists, and 120 features received >70% positive responses and reached final consensus for inclusion (62 in level 1 and 58 in level 2). Certain features may have been excluded if they are rarely seen, challenging to discern, and/or of poor diagnostic value. Of note, 19 features (4 in level 1

Cancer Center Moon Shots Program. The funding source was not involved in the design or conduct of the study; the collection, management, analysis, or interpretation of the data; the preparation, review, or approval of the manuscript; or the decision to submit the manuscript for publication.

Conflict of interest: None.

Prior presentation: A summary of this original work was presented as a medical student poster by Ms. Tiffaney Tran at the annual American Dermoscopy Meeting in St. George, Utah, on July 1, 2022. This work has otherwise not been previously posted or published elsewhere, nor is it under consideration for publication elsewhere.

Corresponding author: Kelly C. Nelson, MD, Department of Dermatology, 1400 Pressler St., Unit 1452, University of Texas MD Anderson Cancer Center, Houston, TX 77030 (E-mail: kcnelson1@mdanderson.org).

J Am Board Fam Med: first published as 10.3122/jabfm.2022.220143R1 on 9 February 2023. Downloaded from http://www.jabfm.org/ on 20 April 2024 by guest. Protected by copyright.

Table 1. Demographic Characteristics of Larger Expert Panel (n = 35 Participants in First Round)

Specialty (n = 35)	Count	%
Family medicine	19	54.3%
Internal medicine	2	5.7%
Medicine—pediatrics	0	0.0%
Dermatology	14	40.0%
Other	0	0.0%
Dermoscopy use in clinical practice (n = 35)	**Count**	**%**
Yes	35	100%
No	0	0.0%
No. years of dermoscopy use in clinical practice (n = 35)	**Count**	**%**
0 to 1 year	0	0.0%
1 to 5 years	16	45.7%
6 to 10 years	10	28.6%
11 to 15 years	4	11.4%
15 + years	5	14.3%
Specialization in pigmented lesions, dermoscopy, or melanoma as an attending physician (n = 35)	**Count**	**%**
Yes	16	45.7%
No	19	54.3%
No. years of specialization in pigmented lesions, dermoscopy, or melanoma as an attending physician (n = 16)	**Count**	**%**
0 to 1 year	0	0.0%
1 to 5 years	7	43.8%
6 to 10 years	2	12.5%
11 to 15 years	4	25.0%
15 + years	3	18.8%
Direct involvement in dermoscopy training for primary care (n = 35)	**Count**	**%**
Yes	22	62.9%
No	13	37.1%
If directly involved in dermoscopy training for primary care, type of training offered* (n = 22)	**Count**	**%**
Dermoscopy training in clinic	18	81.8%
Dermoscopy training in a lecture format	15	68.2%
Other†	3	13.6%

*Multiple selections allowed, sum of percentages >100%.
†Other delivery methods for dermoscopy training, as reported by panelists, included virtual training, e-learning, distance learning.

and 15 in level 2) received >50% but <70% positive responses and thus did not reach final consensus. However, depending on the degree of interest and skill level of the educational cohort, these features may be added as a learning objective at the discretion of the curricular development team.

The online appendices contain the final list of diagnoses and their associated features, organized into levels 1 and 2 based on Delphi agreement. For each associated feature, dermoscopy users may customarily refer to different nomenclatures to describe the same pattern. In this study, the exact wording for each feature was considered less important than the described feature itself.

Discussion

Through a modified Delphi exercise, an expert panel that comprised family medicine physicians, internal medicine physicians, and dermatology specialists achieved consensus on proficiency standards for PCPs learning or using dermoscopy. This collaboration between primary care and dermatology reflects a growing national partnership that has been emerging as an important strategy for skin cancer prevention and detection, especially in rural areas.

Given the range of interest in dermoscopy among PCPs, the consensus process generated 2 levels of proficiency standards. The focus of level 1 (foundational proficiency) is training in the basic skills required to differentiate between benign and malignant lesions under dermoscopy. As expected, level 1 teaches an overview of nevi patterns and melanoma patterns as well as classic features for keratinocyte carcinomas, namely BCC and SCC.

Level 1 also contains common benign diagnoses that closely align with the triage amalgamated dermoscopy algorithm (TADA).[27,28] This diagnostic aid trains learners to first search for specific features of common benign diagnoses (ie, angioma/hemangioma, seborrheic keratosis, dermatofibroma).[29,30] In suspicious lesions, learners next evaluate for characteristic features of malignant diagnoses that would warrant biopsy, excision, or referral to a specialist.[31] Training programs based on TADA have been shown to improve the sensitivity for skin cancer detection compared with baseline.[29–32] Given the proven effectiveness of TADA in training PCPs and novices,[33] PCP-targeted dermoscopy education based on level 1 may begin with TADA and then continue to the other level 1 diagnoses.

Extending beyond level 1, level 2 is intended for more experienced PCPs who desire more advanced dermoscopy skills. Compared with those in level 1,

J Am Board Fam Med: first published as 10.3122/jabfm.2022.220143R1 on 9 February 2023. Downloaded from http://www.jabfm.org/ on 20 April 2024 by guest. Protected by copyright.

Table 2. Dermoscopic Diagnoses by Lesion Category and Proficiency Standard

Category	Level 1 (Foundational)	Level 2 (Intermediate)	Neither
Nonmelanocytic lesions	• Hemangioma • Seborrheic keratosis • Dermatofibroma • Solar lentigo • Basal cell carcinoma • Squamous cell carcinoma • Actinic keratosis	• Sebaceous hyperplasia • Pigmented actinic keratosis • Squamous cell carcinoma in situ • Keratoacanthoma • Angiokeratoma • Lichen planus-like keratosis • Ink spot lentigo†	• Clear cell acanthoma • Merkel cell carcinoma† • Porokeratosois† • Poroma‡ • Xanthogranuloma‡
Benign melanocytic lesions	• Overview of benign nevi patterns • Intradermal nevi	• Blue nevi • Spitz nevi • Congenital melanocytic nevi • Recurrent/persistent nevi • Halo nevi†	• Combined nevi†
Melanoma	• Overview of melanoma patterns	• Acral melanoma • Lentigo maligna melanoma • Melanoma of the nail • Amelanotic/hypomelanotic melanoma	• Desmoplastic melanoma† • Nevoid melanoma† • Verrucous melanoma†
Special sites	Subungual hemorrhage	• Dermoscopic features of the face • Benign patterns of acral nevi • Nevus of the nail • Lentigo of the nail • Talon noir†	• Nevi of the mucosa† • Nevi of the mucocutaneous junction†
Other	• Verruca* • Scabies	• Molluscum contagiosum* • Radiation tattoo* • Scars* • Venous lake* • Psoriasis†	• Atopic dermatitis†

*Suggested by the expert focus group to add onto the Melanoma Prevention Working Group-Pigmented Lesions Subcommittee consensus-based list for dermatology residents.
†Suggested by a panelist during round 1 of the diagnoses survey series.
‡Suggested by a panelist during round 2 of the diagnoses survey series.

diagnoses in level 2 are mostly considered less common in the general population and/or more challenging to discern (eg, pigmented actinic keratosis, lichen planus-like keratosis). Level 2 also incorporates different types of melanoma (eg, lentigo maligna melanoma, amelanotic/hypomelanotic melanoma) and benign nevi (eg, blue nevi, acral nevi) and demonstrates a broader utility of dermoscopy in the identification of other diagnoses frequently encountered by PCPs (eg, molluscum contagiosum, psoriasis).

With the exception of 1 diagnosis that required 2 rounds of feedback (ie, scabies), all level 1 diagnoses were deemed "foundational" by the panel during the very first round of voting, demonstrating strong consensus on the diagnoses reflective of a basic yet practical skillset for PCPs. Subsequent rounds focused on sorting between level 1 and 2 diagnoses and identifying diagnoses that should be excluded from either level. For instance, the decision-making process for lichen planus-like keratosis required 3 rounds of voting before assigning the diagnosis to level 2.

The outcome of this PCP-focused consensus effort differs in some ways from the proficiency standard developed by the MPWG-PLS for dermatology residents.[21] In addition to assigning diagnoses to level 1 or 2, this panel approved the inclusion of additional diagnoses and excluded clear cell acanthoma from either level. Of the 15 total additional diagnoses suggested by panelists, 1 (ie, verruca) reached consensus for inclusion in level 1, and 4 (ie,

J Am Board Fam Med: first published as 10.3122/jabfm.2022.220143R1 on 9 February 2023. Downloaded from http://www.jabfm.org/ on 20 April 2024 by guest. Protected by copyright.

Table 3. Dermoscopic Characteristics of Nonmelanocytic Lesions

Diagnosis (Level 1 or 2) Feature included as a learning objective (>70% positive responses)	Round 1: % Positive Responses* (n = 33)	Round 2: % Positive Responses* (n = 30)
Hemangioma (level 1)		
Red, blue-red, red-purple, or maroon lacunae/lagoons with white septae	72.7%	—
Blue-black coloring in lacunae (when thrombosed) in absence of other structures	72.7%	—
Seborrheic keratosis (level 1)		
Milia-like cysts (cloudy or starry) and comedo-like openings	93.9%	—
"Fissures and ridges"/"gyri and sulci"/cerebriform pattern	93.9%	—
Moth-eaten (sharply demarcated) borders	87.9%	—
Fat fingers	78.8%	—
Fingerprint-like structures (parallel lines)	78.8%	—
Hairpin (looped) vessels	78.8%	—
Dermatofibroma (level 1)		
Central scar-like white patch/depigmentation	100.0%	—
Fine/delicate surrounding/peripheral network-like structures	100.0%	—
Central shiny white lines/streaks under polarized dermoscopy	84.8%	—
Ring-like globules	66.7%	↓ 60.0%
Solar lentigo (level 1)		
Moth-eaten (sharply demarcated) borders	90.9%	—
Fingerprint-like structures (parallel lines)	90.9%	—
Homogenous light brown pigmentation	87.9%	—
Uniform brown perifollicular pigmentation	75.8%	—
Network-like structures	63.6%	↓ 63.3%
Basal cell carcinoma (level 1)		
Arborizing vessels	97.0%	—
Ulceration/erosion	93.9%	—
Leaf-like structures/areas	90.9%	—
Blue-gray ovoid nests	87.9%	—
Spoke-wheel-like structures/areas/concentric structures	87.9%	—
Multiple blue-gray dots and globules (buckshot scatter)	84.8%	—
Shiny white blotches and strands/structures under polarized dermoscopy	69.7%	↑ 76.7%
Short fine telangiectasias (superficial BCC)	69.7%	↑ 70.0%
Squamous cell carcinoma (level 1)		
Yellow keratin mass/scale-crust	100.0%	—
Ulceration/blood spots/hemorrhage	93.9%	—
White circles ("keratin pearls")	90.9%	—
Glomerular (coiled) vessels	90.9%	—
Hairpin vessels	78.8%	—
Rosettes	75.8%	—
Actinic keratosis (level 1)		
Surface scale	97.0%	—
Rosettes	81.8%	—
Strawberry pattern (pink-red pseudonetwork ± fine wavy vessels [straight or coiled] surrounding hair follicles ± white circles with central yellow clod [targetoid hair follicles])	78.8%	—
Sebaceous hyperplasia (level 2)		
Pale yellow lobules (popcorn-like structures) around a central follicular opening	100.0%	—
Crown vessels, out of focus	90.9%	—

Continued

J Am Board Fam Med: first published as 10.3122/jabfm.2022.220143R1 on 9 February 2023. Downloaded from http://www.jabfm.org/ on 20 April 2024 by guest. Protected by copyright.

Table 3. Continued

Diagnosis (Level 1 or 2) Feature included as a learning objective (>70% positive responses)	Round 1: % Positive Responses* (n = 33)	Round 2: % Positive Responses* (n = 30)
Pigmented actinic keratosis (level 2)		
Surface scale	90.9%	—
Rosettes	75.8%	—
Annular-granular pattern (gray dots around follicular openings)	66.7%	↓ 53.3%
Red pseudonetwork†	57.6%	—
Patent/evident follicles†	57.6%	—
Squamous cell carcinoma in situ (level 2)		
Irregularly arranged glomerular (coiled)/dotted vessels	93.9%	—
Surface scale	87.9%	—
Keratoacanthoma (level 2)		
Central keratin mass	93.9%	—
Hairpin (looped) or serpentine (linear-irregular) vessels, usually at the periphery, with white-yellow halo	87.9%	—
Angiokeratoma (level 2)		
Red/purple/black ("dark") lacunae	93.9%	—
Hemorrhagic crust	75.8%	—
Lichen planus-like keratosis (level 2)		
Features of a lentigo or seborrheic keratosis in an area	72.7%	—
Peppering (evenly spaced gray dots)	69.7%	↓ 63.3%
Sharp cut-off borders (scalloped/moth-eaten)	69.7%	↓ 63.3%
Coarse gray granularity	63.6%	↓ 53.3%
Ink spot lentigo (level 2)		
Prominent dark homogenous (uniform) reticular network	93.9%	—
Chicken-wire fence	63.6%	↓ 50.0%

*% of panelists who indicated on a 5-point Likert scale that they "strongly agree" (5) or "agree" (4) with the feature being included in dermoscopy training for primary care providers.
†Suggested by a panelist during round 1 of the features survey series.
Abbreviations: BCC, basal cell carcinoma; SCCIS, squamous cell carcinoma in situ (Bowen's disease).

ink spot lentigo, halo nevi, talon noir, psoriasis) in level 2. The expert focus group also removed simple lentigo from the list due to its overlap with solar lentigo. With the exception of psoriasis (level 2), all other diagnoses excluded from the foundational proficiency standard for dermatology residents (eg, poroma, Merkel cell carcinoma, nevoid melanoma, desmoplastic melanoma) were likewise excluded from the foundational and intermediate proficiency standards for PCPs. The mutual exclusion of these extremely rare and/or challenging diagnoses by this panel serves to validate the results of this consensus process.

This consensus statement will contribute to the development of effective educational interventions that teach expert-approved learning objectives and have content validity.[24] It may also serve as the basis of formal proficiency certification or continuing medical education credit for PCPs. Yet, the application of this consensus statement comes with an important caveat: educators and learners alike are strongly discouraged from approaching dermoscopy training as a process akin to the rote memorization of a list of diagnoses and features. Efficient interpretation of dermoscopic images relies heavily on pattern recognition skills[34] and "fast thinking."[35] Though the educational science for dermoscopy education remains to be further developed, active learning strategies, such as visual perceptual training[36] or deliberate practice,[37] are generally more effective than passive instructional approaches. Future studies will explore the application of this consensus statement to dermoscopy educational interventions for PCPs. Further

J Am Board Fam Med: first published as 10.3122/jabfm.2022.220143R1 on 9 February 2023. Downloaded from http://www.jabfm.org/ on 20 April 2024 by guest. Protected by copyright.

Table 4. Dermoscopic Characteristics of Benign Melanocytic Lesions

Diagnosis (Level 1 or 2) Feature included as a learning objective (>70% positive responses)	Round 1: % Positive Responses* (n = 33)	Round 2: % Positive Responses* (n = 30)
Overview of benign nevi patterns (level 1)		
Diffuse reticular network	100.0%	—
Peripheral reticular network with central hypopigmentation	100.0%	—
Peripheral reticular network with central hyperpigmentation	100.0%	—
Globular pattern	100.0%	—
Patchy reticular network	97.0%	—
Homogenous (tan, brown, blue, or pink)	93.9%	—
Peripheral reticular network with central globules	90.9%	—
Central network with evenly distributed peripheral globules	87.9%	—
Symmetric multicomponent pattern	75.8%	—
Symmetric two-component pattern	69.7%	↓ 60.0%
Intradermal nevi (level 1)		
Comma-shaped (curved) vessels	93.9%	—
Homogenous (structureless) brown/tan/pink pigmentation	93.9%	—
Peripheral network	72.7%	—
Globules	87.9%	—
Blue nevi (level 2)		
Homogenous blue/blue-gray pigmentation	100.0%	—
Well-circumscribed lesion	93.9%	—
Spitz nevi (level 2)		
Starburst pattern with tiered globules/streaks and regularly spaced pseudopods at the periphery (radial streaming)	87.9%	—
Vascular pattern (pink homogenous with dotted vessels)	75.8%	—
Congenital melanocytic nevi (level 2)		
Cobblestone pattern/globular pattern	93.9%	—
Reticular network	90.9%	—
Homogenous background pigmentation	87.9%	—
Hypertrichosis	78.8%	—
Perifollicular hyper-/hypopigmentation	69.7%	↓ 60.0%
Recurrent/persistent nevi (level 2)		
Pigment within the scar, not extending beyond	81.8%	—
Halo nevi (level 2)		
Encircling/surrounding depigmentation/pallor	93.9%	—
Central reticulation with peripheral white depigmentation	78.8%	—
Benign nevi patterns, globular, homogenous	78.8%	—

*% of panelists who indicated on a 5-point Likert scale that they "strongly agree" (5) or "agree" (4) with the feature being included in dermoscopy training for primary care providers.

research is also needed to determine best practices for dermoscopy proficiency assessments.

Conclusions

Dermoscopy is a valuable tool that assists clinicians in discriminating malignant from benign skin lesions. For PCPs who treat skin conditions and evaluate skin lesions, dermoscopy training improves sensitivity for skin cancer diagnosis. However, 1 of the obstacles to developing a standardized dermoscopy curriculum for PCPs has been the lack of consensus on appropriate learning objectives. To PCPs using dermoscopy in clinical practice, this study provides meaningful insight into the diagnoses and features that an expert panel considers important to recognize, especially in the course of identifying skin cancer.

The consensus statement generated by this modified Delphi study will inform future dermoscopy

J Am Board Fam Med: first published as 10.3122/jabfm.2022.220143R1 on 9 February 2023. Downloaded from http://www.jabfm.org/ on 20 April 2024 by guest. Protected by copyright.

Table 5. Dermoscopic Characteristics of Melanomas

Diagnosis (Level 1 or 2) Feature included as a learning objective (>70% positive responses)	Round 1: % Positive Responses* (n = 33)	Round 2: % Positive Responses* (n = 30)
Overview of melanoma patterns *(level 1)*		
Blue structures (blue-white veil, blue-gray structures)	100.0%	—
Shiny white lines/structures (crystalline structures)	100.0%	—
Atypical pigment network	97.0%	—
Atypical/irregular streaks (radial streaming, pseudopods)	97.0%	—
Atypical/irregular dots/globules	93.9%	—
Regression structures (white scar-like area and/or peppering)	93.9%	—
Negative pigment network	87.9%	—
Atypical vascular pattern/structures, polymorphous vessels (2 + types of blood vessels)	87.9%	—
Peripheral brown/tan structureless area	78.8%	—
Angulated lines (extrafacial)/polygons/zig-zag pattern	75.8%	—
Atypical/off-center blotch(es)	69.7%	↑ 90.0%
Acral melanoma *(level 2)*		
Parallel ridge pattern	93.9%	—
Ulceration	90.9%	—
Irregular diffuse pigmentation or blotch	84.8%	—
Multicomponent pattern, asymmetry of structures/colors	84.8%	—
Atypical fibrillar pattern	72.7%	—
Neovascularization, milky red	72.7%	—
Lentigo maligna melanoma *(level 2)*		
Annular-granular pattern (gray dots around follicular openings)	90.9%	—
Asymmetric pigmentation around follicular openings/asymmetric follicular openings	87.9%	—
Rhomboidal structures (angulated lines)/zig-zag pattern	81.8%	—
Dark blotches ± obliterated hair follicles	75.8%	—
Circle within a circle (isobar)	60.6%	↓ 56.7%
Melanoma of the nail *(level 2)*		
Pigmentation of periungual skin (micro-Hutchinson's sign)	90.9%	—
Triangular shape of pigment band (band diameter wider at proximal end)	87.9%	—
Longitudinal brown/black broken lines with irregular spacing, width, coloration, or parallelism	81.8%	—
Band width >3 mm or two thirds of nail plate width	78.8%	—
Brown to black dots/globules associated with longitudinal lines	60.6%	↓ 50.0%
Amelanotic/hypomelanotic melanoma *(level 2)*		
Milky red areas	81.8%	—
Shiny white lines (crystalline structures)	81.8%	—
Atypical vascular pattern, polymorphous vessels (2 + types of blood vessels)	81.8%	—
Scar-like depigmentation	75.8%	—

*% of panelists who indicated on a 5-point Likert scale that they "strongly agree" (5) or "agree" (4) with the feature being included in dermoscopy training for primary care providers.

training programs designed to support early skin cancer detection by PCPs. Through the dissemination of a standardized dermoscopy curriculum, the dermatoscope may become increasingly recognized as a valuable component of the PCP's toolbox alongside other commonly used medical instruments such as the ophthalmoscope, otoscope, and stethoscope.[38] The ultimate goal of these dermoscopy training initiatives would be to decrease patient morbidity and mortality from skin cancer, especially in regions without convenient access to dermatology specialists.

The research team wishes to acknowledge Dr. Lauren Fried for her guidance on the study design.

J Am Board Fam Med: first published as 10.3122/jabfm.2022.220143R1 on 9 February 2023. Downloaded from http://www.jabfm.org/ on 20 April 2024 by guest. Protected by copyright.

Table 6. Dermoscopic Characteristics of Benign Diagnoses at Special Sites

Diagnosis (Level 1 or 2) Feature included as a learning objective (>70% positive responses)	Round 1: % Positive Responses* (n = 33)	Round 2: % Positive Responses* (n = 30)
Subungual hemorrhage (level 1)		
Well-circumscribed red-black dots or blotches/blood spots	90.9%	—
Discontiguous with the cuticle (not connected to the proximal nailfold or edge of nail)	87.9%	—
Distal streaks of red-brown coloration ("filamentous" distal end)	81.8%	—
Homogenous red/purple/black coloration without melanin granules	69.7%	↓ 60.0%
Dermoscopic features of the face (level 2)		
Pseudonetwork	78.8%	—
Benign patterns of acral nevi (level 2)		
Parallel furrow pattern (with pattern variations including single line, double line, single dotted line, double dotted line)	93.9%	—
Lattice-like pattern	87.9%	—
Fibrillar pattern (soles only)	84.8%	—
Homogenous pattern	75.8%	—
Peas-in-a-pod pattern (parallel furrow + globules on ridges) (acral congenital melanocytic nevi)	69.7%	↓ 56.7%
Nevus of the nail (level 2)		
Uniform band thickness, color, and spacing with parallel band configuration and unbroken lines	87.9%	—
Homogenous brown background coloration	84.8%	—
Lentigo of the nail (level 2)		
Homogenous gray band or lines ± gray background	78.8%	—
Regular light-brown lines†	—	60.0%
Talon noir (level 2)		
Homogenous red-brown coloration	78.8%	—
Cracks (lightning bolt sign)‡	51.5%	—

*% of panelists who indicated on a 5-point Likert scale that they "strongly agree" (5) or "agree" (4) with the feature being included in dermoscopy training for primary care providers.
†Suggested by a panelist during round 1 of the dermoscopic features survey series.
‡Feature did not undergo a revote in round 2 due to original threshold criteria for a revote being <70% but >60% positive responses.

To see this article online, please go to: http://jabfm.org/content/36/1/25.full.

References

1. Siegel RL, Miller KD, Fuchs HE, Jemal A. Cancer statistics, 2022. CA A Cancer J Clinicians 2022;72:7–33.
2. Howlader NN, Krapcho M, Miller D, et al. editors. SEER cancer statistics review, 1975-2016 [Internet].2019 [cited 2021 July 1]. Available from: https://seer.cancer.gov/csr/1975_2016/.
3. Glazer AM, Farberg AS, Winkelmann RR, Rigel DS. Analysis of trends in geographic distribution and density of US dermatologists. JAMA Dermatol 2017;153:322–5.
4. Vaidya T, Zubritsky L, Alikhan A, Housholder A. Socioeconomic and geographic barriers to dermatology care in urban and rural US populations. J Am Acad Dermatol 2018;78:406–8.
5. Wu X, Marchetti MA, Marghoob AA. Dermoscopy: not just for dermatologists. Melanoma Manag 2015;2:63–73.
6. Losina E, Walensky RP, Geller A, et al. Visual screening for malignant melanoma: a cost-effectiveness analysis. Arch Dermatol 2007;143:21–8.
7. Marghoob NG, Liopyris K, Jaimes N. Dermoscopy: a review of the structures that facilitate melanoma detection. J Am Osteopath Assoc 2019;119:380–90.
8. Vestergaard ME, Macaskill P, Holt PE, Menzies SW. Dermoscopy compared with naked eye examination for the diagnosis of primary melanoma: a meta-analysis of studies performed in a clinical setting. Br J Dermatol 2008;159:669–76.
9. Dinnes J, Deeks JJ, Grainge MJ, et al. Visual inspection for diagnosing cutaneous melanoma in adults. Cochrane Database Syst Rev 2018;12:CD013194.
10. Prasad S, Black S, Chen HW, et al. Beliefs and barriers to care of primary care practitioners toward

J Am Board Fam Med: first published as 10.3122/jabfm.2022.220143R1 on 9 February 2023. Downloaded from http://www.jabfm.org/ on 20 April 2024 by guest. Protected by copyright.

Table 7. Dermoscopic Characteristics of Other Diagnoses, Including Skin Infections and Infestations

Diagnosis (Level 1 or 2) Feature included as a learning objective (>70% positive responses)	Round 1: % Positive Responses* (n = 33)	Round 2: % Positive Responses* (n = 30)
Verruca (level 1)		
Papilliform structures	93.9%	—
Tiny red-black dots (papillary capillaries)	90.9%	—
Scabies (level 1)		
Delta-wing jet with contrail sign (small dark brown triangular structure located at the end of whitish structureless curved/wavy lines)	90.9%	—
Molluscum contagiosum (level 2)		
Central pore or umbilication	93.9%	—
Polylobular white-yellow amorphous structures	81.8%	—
Linear or branched vessels (red corona)/crown vessels	63.6%	↓ 63.3%
Radiation tattoo (level 2)		
Homogenous blue or black coloration	84.8%	—
Scars (level 2)		
White depigmentation	72.7%	—
Venous lake (level 2)		
Homogenous purple/blue/red coloration ± globules/clods	93.9%	—
Psoriasis (level 2)		
Red or pink color with white scales/light-red background	75.8%	—
Dotted vessels in a regular distribution	72.7%	—

*% of panelists who indicated on a 5-point Likert scale that they "strongly agree" (5) or "agree" (4) with the feature being included in dermoscopy training for primary care providers.

melanoma screening and education in rural Texas. J Am Acad Dermatol. Forthcoming 2022.

11. Verhoeven EW, Kraaimaat FW, van Weel C, et al. Skin diseases in family medicine: prevalence and health care use. Ann Fam Med 2008;6:349–54.
12. Perera E, Xu C, Manoharan S. Real-life teledermatology cases. In: Soyer HP, Binder M, Smith AC, Wurm EMT, editors. Telemedicine in dermatology. Springer Science & Business Media; 2012. p. 123–9.
13. Westerhoff K, McCarthy WH, Menzies SW. Increase in the sensitivity for melanoma diagnosis by primary care physicians using skin surface microscopy. Br J Dermatol 2000;143:1016–20.
14. Argenziano G, Puig S, Zalaudek I, et al. Dermoscopy improves accuracy of primary care physicians to triage lesions suggestive of skin cancer. J Clin Oncol 2006;24:1877–82.
15. Menzies SW, Emery J, Staples M, et al. Impact of dermoscopy and short-term sequential digital dermoscopy imaging for the management of pigmented lesions in primary care: a sequential intervention trial. Br J Dermatol 2009;161:1270–7.
16. Koelink CJ, Vermeulen KM, Kollen BJ, et al. Diagnostic accuracy and cost-effectiveness of dermoscopy in primary care: a cluster randomized clinical trial. J Eur Acad Dermatol Venereol 2014;28:1442–9.
17. De Bedout V, Williams NM, Muñoz AM, et al. Skin cancer and dermoscopy training for primary care physicians: a pilot study. Dermatol Pract Concept 2021;11:e2021145.
18. Pokhrel PK, Helm MF, Greene A, Helm LA, Partin M. Dermoscopy in primary care. Prim Care 2022;49:99–118.
19. Posada EL, Lauck KC, Tran T, Krause KJ, Nelson KC. Educational interventions to support primary care provider performance of diagnostic skin cancer examinations: a systematic literature review. J Cancer Educ 2022;1–10.
20. Najmi M, Brown AE, Harrington SR, Farris D, Sepulveda S, Nelson KC. A systematic review and synthesis of qualitative and quantitative studies evaluating provider, patient, and health care system-related barriers to diagnostic skin cancer examinations. Arch Dermatol Res 2022; 314:329–40.
21. Fried LJ, Tan A, Berry EG, et al. Dermoscopy proficiency expectations for US dermatology resident physicians: results of a modified Delphi survey of pigmented lesion experts. JAMA Dermatol 2021; 157:189–97.

J Am Board Fam Med: first published as 10.3122/jabfm.2022.220143R1 on 9 February 2023. Downloaded from http://www.jabfm.org/ on 20 April 2024 by guest. Protected by copyright.

22. Dalkey NC, Helmer O. An experimental application of the DELPHI method to the use of experts. Manag Sci 1963;9:458–67.
23. Dalkey NC. The Delphi method: an experimental study of group opinion. RAND Corporation; 1969.
24. Rusticus S. Content validity. In: Michalos AC, ed. Encyclopedia of quality of life and well-being research. Springer Netherlands; 2014. p. 1261–2.
25. Dermoscopedia [Internet]. International Dermoscopy Society; 2021 [accessed 1 Nov 2021]. Available from: https://dermoscopedia.org/Main_Page.
26. Kittler H, Marghoob AA, Argenziano G, et al. Standardization of terminology in dermoscopy/dermatoscopy: results of the third consensus conference of the International Society of Dermoscopy. J Am Acad Dermatol 2016;74:1093–106.
27. Rogers T, Marino ML, Dusza SW, et al. A clinical aid for detecting skin cancer: the triage amalgamated dermoscopic algorithm (TADA). J Am Board Fam Med 2016;29:694–701.
28. Jaimes N, Marghoob AA. Triage amalgamated dermoscopic algorithm. J Am Acad Dermatol 2020; 82:1551–2.
29. Seiverling EV, Ahrns HT, Greene A, et al. Teaching benign skin lesions as a strategy to improve the triage amalgamated dermoscopic algorithm (TADA). J Am Board Fam Med 2019;32:96–102.
30. Sawyers EA, Wigle DT, Marghoob AA, Blum A. Dermoscopy training effect on diagnostic accuracy of skin lesions in Canadian family medicine physicians using the triage amalgamated dermoscopic algorithm. Dermatol Pract Concept 2020;10:e2020035.
31. Susong JR, Ahrns HT, Daugherty A, Marghoob AA, Seiverling EV. Evaluation of a virtual basic dermatology curriculum for dermoscopy by using the triage amalgamated dermoscopic algorithm for novice dermoscopists. J Am Acad Dermatol 2020;83:590–2.
32. Seiverling E, Ahrns H, Stevens K, et al. Dermoscopic lotus of learning: implementation and dissemination of a multimodal dermoscopy curriculum for primary care. J Med Educ Curric Dev 2021;8:2382120521989983–4.
33. Cyr PR, Craig W, Ahrns H, Stevens K, Wight C, Seiverling E. Teaching skin cancer detection to medical students using a dermoscopic algorithm. STFM PRiMER 2021;5:6.
34. Kellman PJ, Garrigan P. Perceptual learning and human expertise. Phys Life Rev 2009;6:53–84.
35. Gronchi G, Giovannelli F. Dual process theory of thought and default mode network: a possible neural foundation of fast thinking. Front Psychol 2018;9:1237.
36. Rimoin L, Altieri L, Craft N, Krasne S, Kellman PJ. Training pattern recognition of skin lesion morphology, configuration, and distribution. J Am Acad Dermatol 2015;72:489–95.
37. Ericsson KA. Acquisition and maintenance of medical expertise: a perspective from the expert-performance approach with deliberate practice. Acad Med 2015;90:1471–86.
38. Lallas A, Argenziano G. Dermatoscope—the dermatologist's stethoscope. Indian J Dermatol Venereol Leprol 2014;80:493–4.

J Am Board Fam Med: first published as 10.3122/jabfm.2022.220143R1 on 9 February 2023. Downloaded from http://www.jabfm.org/ on 20 April 2024 by guest. Protected by copyright.

Appendices.

Appendix A. Modified Delphi method survey instruments

Dermatologic Diagnoses Survey Series

Round 1

- Consent Statement
- Round 1: Survey Objective
- Section 1: Nonmelanocytic Lesions
- Section 2: Benign Melanocytic Lesions
- Section 3: Melanoma
- Section 4: Special Sites
- Section 5: Other
- Demographics Survey

Round 2

- Consent Statement
- Round 2: Survey Objective
- Section 1: Nonmelanocytic Lesions
- Section 2: Benign Melanocytic Lesions
- Section 3: Melanoma
- Section 4: Special Sites
- Section 5: Other

Round 3

- Consent Statement
- Round 3: Survey Objective
- Diagnoses: All Categories

Dermoscopic Features Survey Series

Round 1

- Consent Statement
- Round 1: Survey Objective
- Section 1: Nonmelanocytic Lesions
- Section 2: Benign Melanocytic Lesions
- Section 3: Melanoma
- Section 4: Special Sites
- Section 5: Other
- Miscellaneous

Round 2

- Consent Statement
- Round 2: Survey Objective
- Section 1: Nonmelanocytic Lesions
- Section 2: Benign Melanocytic Lesions
- Section 3: Melanoma
- Section 4: Special Sites
- Section 5: Other

J Am Board Fam Med: first published as 10.3122/jabfm.2022.220143R1 on 9 February 2023. Downloaded from http://www.jabfm.org/ on 20 April 2024 by guest. Protected by copyright.

Dermatologic Diagnoses: Round 1

Returning?

AAA

We appreciate your interest in participating in the PCP Dermoscopy Education Working Group.

About Us

We are a research team from The University of Texas MD Anderson Cancer Center, and we are conducting a research study supervised by Dr. Kelly Nelson.

Study Goal

The goal of this research study is the development and refinement of an expert consensus statement regarding key knowledge acquisition and self-efficacy learning aspects and assessment instruments for **Primary Care Provider (PCP)-targeted educational instruments seeking to improve skin cancer diagnosis**.

An initial consensus statement identifying key learning aspects was compiled using a systematic literature review and review of initial pilot instruments.

Study Details

If you agree to take part in this study, you will be asked to complete a series of electronic surveys listing potential learning aspects in which each participant will rate the appropriateness of inclusion for each objective. A modified Delphi process (a common iterative method used to obtain the consensus opinions of a group of authorities on a given topic) is being utilized for this effort. Feedback will be collected and assessed, and then a modified survey will be developed based on feedback and then re-administered to collect another round of feedback. This process will be repeated until consensus is reached.

You may complete the survey(s) either on paper or online using a web link sent by the study staff. Each survey should take up to 15 minutes to complete. The time between surveys will be about 1 month. Your total time or participation may be up to 3 months.

Study Participation

Your participation in this research is voluntary. If you choose not to take part, it will not affect your employment or traineeship at your institution in any way. If you do choose to take part in this research, your responses will also not affect your employment or trainee status.

There will be no compensation for your participation in this study.

Protection of Confidentiality

The research team is committed to protecting your confidentiality at all times and in all circumstances. Your response to the study evaluation and surveys will not be made public. Any study survey data will be de-identified and/or reported in aggregate form for analyses. No identifying information will be used in the publication of the findings.

All electronic study data will be stored in an institutional database indefinitely. Participants who choose to fill out a paper copy of the survey(s) will have their responses stored in a locked file cabinet within the research team's locked office.

Your personally identifying information will be stored in a password-protected database, and your information and responses will be labeled with a study-specific participant identification number (participant ID) that will de-identify you from your responses before the analyses. Only certain members of the study staff will have the key to link your study ID to your personal information. Your personal information (name, date of survey, and email address) will be used to merge multiple rounds of survey responses and will not be shared with other survey participants.

Consent Statement

You have read the description of the study and have decided to participate in the research project described here. You understand that you may refuse to answer any (or all) of the questions at this or any other time. You understand that there is a possibility that you might be contacted in the future about this but that you are free to refuse any further participation if you wish.

You may withdraw your authorization at any time, in writing, for any reason as long as that information can be connected to you. You can learn more about how to withdraw your authorization by calling [redacted] or by contacting the study chair Dr. Kelly Nelson.

1) By checking this box and proceeding to our Round 1 survey, I acknowledge the above statement and voluntarily consent to participate in the study. ☐ I consent

Submit

Save & Return Later

Powered by REDCap

J Am Board Fam Med: first published as 10.3122/jabfm.2022.220143R1 on 9 February 2023. Downloaded from http://www.jabfm.org/ on 20 April 2024 by guest. Protected by copyright.

Round 1: Survey Objective

AAA

You have been invited to participate in our study panel.

Survey Objective

The objective of this initial survey is to develop an expert-approved list of **common dermatologic diagnoses** to be included in dermoscopy education targeted towards PCPs.

Proficiency Levels

Given the diversity of interest, bandwidth, and engagement with dermoscopy across the PCP spectrum, we will ask you to sort diagnoses into three choices:

- **Level 1 (Foundational) —** PCPs who desire a basic yet practical understanding of dermoscopy and its applications for the detection of skin cancer should be able to recognize these diagnoses with appropriate training.
- **Level 2 (Intermediate) —** PCPs who are highly interested in dermoscopy and desire further training in dermoscopy beyond the Foundational Level should be able to recognize these diagnoses. With appropriate training, recognition of these "above and beyond" diagnoses would demonstrate an additional level of mastery beyond Level 1 (Foundational).
- **Not appropriate —** Dermoscopic identification of these diagnoses would not be reflective of either foundational- or intermediate-level proficiency for PCPs.

Survey Overview

This survey will be divided into 5 sections:

1. Non-melanocytic lesions
2. Benign melanocytic lesions
3. Melanoma
4. Special sites
5. Other (including skin infections & infestations)

Within each section, you will review a list of dermatologic diagnoses and consider whether each specific diagnosis should be included in the learning objectives for PCP-targeted dermoscopy education. You will then answer the following questions for each specific diagnosis:

1. Should the diagnosis be included in a **Level 1 (Foundational)** proficiency standard for PCPs?
2. Should the diagnosis be included in a **Level 2 (Intermediate)** proficiency standard for PCPs?
3. Should the diagnosis NOT be included at either level?

You will also be given the opportunity to write in suggestions for additional diagnoses that will then be voted on by the panel in a subsequent survey.

End of Survey

At the end of this survey, you will be asked to answer questions about your area of expertise and experience with dermoscopy training for PCPs.

Time Estimate

We estimate that this survey will take you 15 minutes or less to complete.

1) **By checking this box, I acknowledge that I have read the objective of this survey.** ☐ I acknowledge

Submit

Save & Return Later

Powered by REDCap

J Am Board Fam Med: first published as 10.3122/jabfm.2022.220143R1 on 9 February 2023. Downloaded from http://www.jabfm.org/ on 20 April 2024 by guest. Protected by copyright.

Section 1: Nonmelanocytic Lesions

AAA

We would like to identify the dermatologic diagnoses that should be included in dermoscopy education programs targeted towards PCPs.

Please rate how strongly you would agree or disagree with each of the following statements regarding a specific diagnosis. Given the diversity of interest, bandwidth, and engagement with dermoscopy across the PCP spectrum, we ask you to sort each diagnosis into three choices:

- **Level 1 (Foundational)** — PCPs who desire a basic yet practical understanding of dermoscopy and its applications for the detection of skin cancer should be able to recognize these diagnoses with appropriate training.
- **Level 2 (Intermediate)** — PCPs who are highly interested in dermoscopy and desire further training in dermoscopy beyond the Foundational Level should be able to recognize these diagnoses. With appropriate training, recognition of these "above and beyond" diagnoses would demonstrate an additional level of mastery beyond Level 1 (Foundational).
- **Not appropriate** — Dermoscopic identification of these diagnoses would not be reflective of either foundational- or intermediate-level proficiency for PCPs.

Please note that a "Neutral" vote will not contribute towards a consensus on the inclusion or exclusion of that specific diagnosis.

Basal Cell Carcinoma

	Strongly disagree	Disagree	Neutral	Agree	Strongly agree
1) Basal Cell Carcinoma should be included in Level 1 (Foundational)	○	○	○	○	○
2) Basal Cell Carcinoma should be included in Level 2 (Intermediate)	○	○	○	○	○
3) Basal Cell Carcinoma should NOT be included at either level	○	○	○	○	○

Actinic Keratosis

	Strongly disagree	Disagree	Neutral	Agree	Strongly agree
4) Actinic Keratosis should be included in Level 1 (Foundational)	○	○	○	○	○
5) Actinic Keratosis should be included in Level 2 (Intermediate)	○	○	○	○	○
6) Actinic Keratosis should NOT be included at either level	○	○	○	○	○

Pigmented Actinic Keratosis

	Strongly disagree	Disagree	Neutral	Agree	Strongly agree
7) Pigmented Actinic Keratosis should be included in Level 1 (Foundational)	○	○	○	○	○
8) Pigmented Actinic Keratosis should be included in Level 2 (Intermediate)	○	○	○	○	○
9) Pigmented Actinic Keratosis should NOT be included at either level	○	○	○	○	○

Squamous Cell Carcinoma in situ (Bowen's disease)

	Strongly disagree	Disagree	Neutral	Agree	Strongly agree
10) Squamous Cell Carcinoma in situ should be included in Level 1 (Foundational)	○	○	○	○	○
11) Squamous Cell Carcinoma in situ should be included in Level 2 (Intermediate)	○	○	○	○	○
12) Squamous Cell Carcinoma in situ should NOT be included at either level	○	○	○	○	○

J Am Board Fam Med: first published as 10.3122/jabfm.2022.220143R1 on 9 February 2023. Downloaded from http://www.jabfm.org/ on 20 April 2024 by guest. Protected by copyright.

Keratoacanthoma

	Strongly disagree	Disagree	Neutral	Agree	Strongly agree
13) Keratoacanthoma should be included in Level 1 (Foundational)	○	○	○	○	○
14) Keratoacanthoma should be included in Level 2 (Intermediate)	○	○	○	○	○
15) Keratoacanthoma should be NOT be included at either level	○	○	○	○	○

Squamous Cell Carcinoma

	Strongly disagree	Disagree	Neutral	Agree	Strongly agree
16) Squamous Cell Carcinoma should be included in Level 1 (Foundational)	○	○	○	○	○
17) Squamous Cell Carcinoma should be included in Level 2 (Intermediate)	○	○	○	○	○
18) Squamous Cell Carcinoma should NOT be included at either level	○	○	○	○	○

Simple Lentigo

	Strongly disagree	Disagree	Neutral	Agree	Strongly agree
19) Simple Lentigo should be included in Level 1 (Foundational)	○	○	○	○	○
20) Simple Lentigo should be included in Level 2 (Intermediate)	○	○	○	○	○
21) Simple Lentigo should NOT be included at either level	○	○	○	○	○

Solar Lentigo

	Strongly disagree	Disagree	Neutral	Agree	Strongly agree
22) Solar Lentigo should be included in Level 1 (Foundational)	○	○	○	○	○
23) Solar Lentigo should be included in Level 2 (Intermediate)	○	○	○	○	○
24) Solar Lentigo should NOT be included at either level	○	○	○	○	○

Seborrheic Keratosis

	Strongly disagree	Disagree	Neutral	Agree	Strongly agree
25) Seborrheic Keratosis should be included in Level 1 (Foundational)	○	○	○	○	○
26) Seborrheic Keratosis should be included in Level 2 (Intermediate)	○	○	○	○	○
27) Seborrheic Keratosis should NOT be included at either level	○	○	○	○	○

J Am Board Fam Med: first published as 10.3122/jabfm.2022.220143R1 on 9 February 2023. Downloaded from http://www.jabfm.org/ on 20 April 2024 by guest. Protected by copyright.

Lichen Planus-Like Keratosis (Benign Lichenoid Keratosis)

	Strongly disagree	Disagree	Neutral	Agree	Strongly agree
28) Lichen Planus-Like Keratosis should be included in Level 1 (Foundational)	○	○	○	○	○
29) Lichen Planus-Like Keratosis should be included in Level 2 (Intermediate)	○	○	○	○	○
30) Lichen Planus-Like Keratosis should NOT be included at either level	○	○	○	○	○

Angioma

	Strongly disagree	Disagree	Neutral	Agree	Strongly agree
31) Angioma should be included in Level 1 (Foundational)	○	○	○	○	○
32) Angioma should be included in Level 2 (Intermediate)	○	○	○	○	○
33) Angioma should NOT be included at either level	○	○	○	○	○

Angiokeratoma

	Strongly disagree	Disagree	Neutral	Agree	Strongly agree
34) Angiokeratoma should be included in Level 1 (Foundational)	○	○	○	○	○
35) Angiokeratoma should be included in Level 2 (Intermediate)	○	○	○	○	○
36) Angiokeratoma should NOT be included at either level	○	○	○	○	○

Dermatofibroma

	Strongly disagree	Disagree	Neutral	Agree	Strongly agree
37) Dermatofibroma should be included in Level 1 (Foundational)	○	○	○	○	○
38) Dermatofibroma should be included in Level 2 (Intermediate)	○	○	○	○	○
39) Dermatofibroma should NOT be included at either level	○	○	○	○	○

Clear Cell Acanthoma

	Strongly disagree	Disagree	Neutral	Agree	Strongly agree
40) Clear Cell Acanthoma should be included in Level 1 (Foundational)	○	○	○	○	○
41) Clear Cell Acanthoma should be included in Level 2 (Intermediate)	○	○	○	○	○
42) Clear Cell Acanthoma should NOT be included at either level	○	○	○	○	○

Sebaceous Hyperplasia

	Strongly disagree	Disagree	Neutral	Agree	Strongly agree
43) Sebaceous Hyperplasia should be included in Level 1 (Foundational)	○	○	○	○	○
44) Sebaceous Hyperplasia should be included in Level 2 (Intermediate)	○	○	○	○	○
45) Sebaceous Hyperplasia should NOT be included at either level	○	○	○	○	○

46) Please include your suggestions for additional diagnoses and any comments here: [ ] Optional

Submit

Save & Return Later

Powered by REDCap

J Am Board Fam Med: first published as 10.3122/jabfm.2022.220143R1 on 9 February 2023. Downloaded from http://www.jabfm.org/ on 20 April 2024 by guest. Protected by copyright.

Section 2: Benign Melanocytic Lesions

AAA

We would like to identify the dermatologic diagnoses that should be included in dermoscopy education programs targeted towards PCPs.

Please rate how strongly you would agree or disagree with each of the following statements regarding a specific diagnosis. Given the diversity of interest, bandwidth, and engagement with dermoscopy across the PCP spectrum, we ask you to sort each diagnosis into three choices:

- **Level 1 (Foundational)** — PCPs who desire a basic yet practical understanding of dermoscopy and its applications for the detection of skin cancer should be able to recognize these diagnoses with appropriate training.
- **Level 2 (Intermediate)** — PCPs who are highly interested in dermoscopy and desire further training in dermoscopy beyond the Foundational Level should be able to recognize these diagnoses. With appropriate training, recognition of these "above and beyond" diagnoses would demonstrate an additional level of mastery beyond Level 1 (Foundational).
- **Not appropriate** — Dermoscopic identification of these diagnoses would not be reflective of either foundational- or intermediate-level proficiency for PCPs.

Please note that a "Neutral" vote will not contribute towards a consensus on the inclusion or exclusion of that specific diagnosis.

Overview of Benign Nevi Patterns (e.g., globular pattern, reticular network)

	Strongly disagree	Disagree	Neutral	Agree	Strongly agree
1) An overview of benign nevi patterns should be included in Level 1 (Foundational)	○	○	○	○	○
2) An overview of benign nevi patterns should be included in Level 2 (Intermediate)	○	○	○	○	○
3) An overview of benign nevi patterns should NOT be included at either level	○	○	○	○	○

Congenital Melanocytic Nevi

	Strongly disagree	Disagree	Neutral	Agree	Strongly agree
4) Congenital Melanocytic Nevi should be included in Level 1 (Foundational)	○	○	○	○	○
5) Congenital Melanocytic Nevi should be included in Level 2 (Intermediate)	○	○	○	○	○
6) Congenital Melanocytic Nevi should NOT be included at either level	○	○	○	○	○

J Am Board Fam Med: first published as 10.3122/jabfm.2022.220143R1 on 9 February 2023. Downloaded from http://www.jabfm.org/ on 20 April 2024 by guest. Protected by copyright.

Intradermal Nevi

	Strongly disagree	Disagree	Neutral	Agree	Strongly agree
7) Intradermal Nevi should be included in Level 1 (Foundational)	○	○	○	○	○
8) Intradermal Nevi should be included in Level 2 (Intermediate)	○	○	○	○	○
9) Intradermal Nevi should NOT be included at either level	○	○	○	○	○

Blue Nevi

	Strongly disagree	Disagree	Neutral	Agree	Strongly agree
10) Blue Nevi should be included in Level 1 (Foundational)	○	○	○	○	○
11) Blue Nevi should be included in Level 2 (Intermediate)	○	○	○	○	○
12) Blue Nevi should NOT be included at either level	○	○	○	○	○

Spitz Nevi

	Strongly disagree	Disagree	Neutral	Agree	Strongly agree
13) Spitz Nevi should be included in Level 1 (Foundational)	○	○	○	○	○
14) Spitz Nevi should be included in Level 2 (Intermediate)	○	○	○	○	○
15) Spitz Nevi should NOT be included at either level	○	○	○	○	○

Recurrent Nevi (Persistent Nevi)

	Strongly disagree	Disagree	Neutral	Agree	Strongly agree
16) Recurrent Nevi should be included in Level 1 (Foundational)	○	○	○	○	○
17) Recurrent Nevi should be included in Level 2 (Intermediate)	○	○	○	○	○
18) Recurrent Nevi should NOT be included at either level	○	○	○	○	○

19) Please include your suggestions for additional diagnoses and any comments here: [ ] Optional

Submit

Save & Return Later

Powered by REDCap

J Am Board Fam Med: first published as 10.3122/jabfm.2022.220143R1 on 9 February 2023. Downloaded from http://www.jabfm.org/ on 20 April 2024 by guest. Protected by copyright.

Section 3: Melanoma

We would like to identify the dermatologic diagnoses that should be included in dermoscopy education programs targeted towards PCPs.

Please rate how strongly you would agree or disagree with each of the following statements regarding a specific diagnosis. Given the diversity of interest, bandwidth, and engagement with dermoscopy across the PCP spectrum, we ask you to sort each diagnosis into three choices:

- **Level 1 (Foundational)** — PCPs who desire a basic yet practical understanding of dermoscopy and its applications for the detection of skin cancer should be able to recognize these diagnoses with appropriate training.
- **Level 2 (Intermediate)** — PCPs who are highly interested in dermoscopy and desire further training in dermoscopy beyond the Foundational Level should be able to recognize these diagnoses. With appropriate training, recognition of these "above and beyond" diagnoses would demonstrate an additional level of mastery beyond Level 1 (Foundational).
- **Not appropriate** — Dermoscopic identification of these diagnoses would not be reflective of either foundational- or intermediate-level proficiency for PCPs.

Please note that a "Neutral" vote will not contribute towards a consensus on the inclusion or exclusion of that specific diagnosis.

Overview of Melanoma Patterns (e.g., blue-white veil, regression structures)

	Strongly disagree	Disagree	Neutral	Agree	Strongly agree
1) An overview of melanoma patterns should be included in Level 1 (Foundational)	○	○	○	○	○
2) An overview of melanoma patterns should be included in Level 2 (Intermediate)	○	○	○	○	○
3) An overview of melanoma patterns should NOT be included at either level	○	○	○	○	○

Acral Lentiginous Melanoma

	Strongly disagree	Disagree	Neutral	Agree	Strongly agree
4) Acral Lentiginous Melanoma should be included in Level 1 (Foundational)	○	○	○	○	○
5) Acral Lentiginous Melanoma should be included in Level 2 (Intermediate)	○	○	○	○	○
6) Acral Lentiginous Melanoma should NOT be included at either level	○	○	○	○	○

Lentigo Maligna Melanoma (melanoma on chronically sun-damaged skin of the head/neck)

	Strongly disagree	Disagree	Neutral	Agree	Strongly agree
7) Lentigo Maligna Melanoma should be included in Level 1 (Foundational)	○	○	○	○	○
8) Lentigo Maligna Melanoma should be included in Level 2 (Intermediate)	○	○	○	○	○
9) Lentigo Maligna Melanoma should NOT be included at either level	○	○	○	○	○

Amelanotic/Hypomelanotic Melanoma

	Strongly disagree	Disagree	Neutral	Agree	Strongly agree
10) Amelanotic/Hypomelanotic Melanoma should be included in Level 1 (Foundational)	○	○	○	○	○
11) Amelanotic/Hypomelanotic Melanoma should be included in Level 2 (Intermediate)	○	○	○	○	○
12) Amelanotic/Hypomelanotic Melanoma should NOT be included at either level	○	○	○	○	○

13) Please include your suggestions for additional diagnoses and any comments here: _____ Optional

Submit

Save & Return Later

Powered by REDCap

J Am Board Fam Med: first published as 10.3122/jabfm.2022.220143R1 on 9 February 2023. Downloaded from http://www.jabfm.org/ on 20 April 2024 by guest. Protected by copyright.

Section 4: Special Sites

A A A

We would like to identify the dermatologic diagnoses that should be included in dermoscopy education programs targeted towards PCPs.

Please rate how strongly you would agree or disagree with each of the following statements regarding a specific diagnosis. Given the diversity of interest, bandwidth, and engagement with dermoscopy across the PCP spectrum, we ask you to sort each diagnosis into three choices:

- **Level 1 (Foundational)** — PCPs who desire a basic yet practical understanding of dermoscopy and its applications for the detection of skin cancer should be able to recognize these diagnoses with appropriate training.
- **Level 2 (Intermediate)** — PCPs who are highly interested in dermoscopy and desire further training in dermoscopy beyond the Foundational Level should be able to recognize these diagnoses. With appropriate training, recognition of these "above and beyond" diagnoses would demonstrate an additional level of mastery beyond Level 1 (Foundational).
- **Not appropriate** — Dermoscopic identification of these diagnoses would not be reflective of either foundational- or intermediate-level proficiency for PCPs.

Please note that a "Neutral" vote will not contribute towards a consensus on the inclusion or exclusion of that specific diagnosis.

Facial Sites: Dermoscopic Features of the Face (i.e., pseudonetwork)

	Strongly disagree	Disagree	Neutral	Agree	Strongly agree
1) Dermoscopic features of the face should be included in Level 1 (Foundational)	○	○	○	○	○
2) Dermoscopic features of the face should be included in Level 2 (Intermediate)	○	○	○	○	○
3) Dermoscopic features of the face should NOT be included at either level	○	○	○	○	○

Acral Sites: Benign Patterns of Acral Nevi

	Strongly disagree	Disagree	Neutral	Agree	Strongly agree
4) Benign patterns of acral nevi should be included in Level 1 (Foundational)	○	○	○	○	○
5) Benign patterns of acral nevi should be included in Level 2 (Intermediate)	○	○	○	○	○
6) Benign patterns of acral nevi should NOT be included at either level	○	○	○	○	○

Nails: Lentigo of the Nail (melanotic macule of the nail)

	Strongly disagree	Disagree	Neutral	Agree	Strongly agree
7) Lentigo of the Nail should be included in Level 1 (Foundational)	○	○	○	○	○
8) Lentigo of the Nail should be included in Level 2 (Intermediate)	○	○	○	○	○
9) Lentigo of the Nail should NOT be included at either level	○	○	○	○	○

Nails: Melanoma of the Nail

	Strongly disagree	Disagree	Neutral	Agree	Strongly agree
10) Melanoma of the Nail should be included in Level 1 (Foundational)	○	○	○	○	○
11) Melanoma of the Nail should be included in Level 2 (Intermediate)	○	○	○	○	○
12) Melanoma of the Nail should NOT be included at either level	○	○	○	○	○

Nails: Subungual Hemorrhage

	Strongly disagree	Disagree	Neutral	Agree	Strongly agree
13) Subungual Hemorrhage should be included in Level 1 (Foundational)	○	○	○	○	○
14) Subungual Hemorrhage should be included in Level 2 (Intermediate)	○	○	○	○	○
15) Subungual Hemorrhage should NOT be included at either level	○	○	○	○	○

16) Please include your suggestions for additional diagnoses and any comments here: _____ Optional

Submit

Save & Return Later

Powered by REDCap

J Am Board Fam Med: first published as 10.3122/jabfm.2022.220143R1 on 9 February 2023. Downloaded from http://www.jabfm.org/ on 20 April 2024 by guest. Protected by copyright.

Section 5: Other (including skin infections & infestations)

AAA

We would like to identify the dermatologic diagnoses that should be included in dermoscopy education programs targeted towards PCPs.

Please rate how strongly you would agree or disagree with each of the following statements regarding a specific diagnosis. Given the diversity of interest, bandwidth, and engagement with dermoscopy across the PCP spectrum, we ask you to sort each diagnosis into three choices:

- **Level 1 (Foundational)** — PCPs who desire a basic yet practical understanding of dermoscopy and its applications for the detection of skin cancer should be able to recognize these diagnoses with appropriate training.
- **Level 2 (Intermediate)** — PCPs who are highly interested in dermoscopy and desire further training in dermoscopy beyond the Foundational Level should be able to recognize these diagnoses. With appropriate training, recognition of these "above and beyond" diagnoses would demonstrate an additional level of mastery beyond Level 1 (Foundational).
- **Not appropriate** — Dermoscopic identification of these diagnoses would not be reflective of either foundational- or intermediate-level proficiency for PCPs.

Please note that a "Neutral" vote will not contribute towards a consensus on the inclusion or exclusion of that specific diagnosis.

Scabies

	Strongly disagree	Disagree	Neutral	Agree	Strongly agree
1) Scabies should be included in Level 1 (Foundational)	○	○	○	○	○
2) Scabies should be included in Level 2 (Intermediate)	○	○	○	○	○
3) Scabies should NOT be included at either level	○	○	○	○	○

Molluscum Contagiosum

	Strongly disagree	Disagree	Neutral	Agree	Strongly agree
4) Molluscum Contagiosum should be included in Level 1 (Foundational)	○	○	○	○	○
5) Molluscum Contagiosum should be included in Level 2 (Intermediate)	○	○	○	○	○
6) Molluscum Contagiosum should NOT be included at either level	○	○	○	○	○

Verruca (Warts)

	Strongly disagree	Disagree	Neutral	Agree	Strongly agree
7) Verruca should be included in Level 1 (Foundational)	○	○	○	○	○
8) Verruca should be included in Level 2 (Intermediate)	○	○	○	○	○
9) Verruca should NOT be included at either level	○	○	○	○	○

J Am Board Fam Med: first published as 10.3122/jabfm.2022.220143R1 on 9 February 2023. Downloaded from http://www.jabfm.org/ on 20 April 2024 by guest. Protected by copyright.

Venous Lake

	Strongly disagree	Disagree	Neutral	Agree	Strongly agree
10) Venous Lake should be included in Level 1 (Foundational)	○	○	○	○	○
11) Venous Lake should be included in Level 2 (Intermediate)	○	○	○	○	○
12) Venous Lake should NOT be included at either level	○	○	○	○	○

Radiation Tattoo

	Strongly disagree	Disagree	Neutral	Agree	Strongly agree
13) Radiation Tattoo should be included in Level 1 (Foundational)	○	○	○	○	○
14) Radiation Tattoo should be included in Level 2 (Intermediate)	○	○	○	○	○
15) Radiation Tattoo should NOT be included at either level	○	○	○	○	○

Dermoscopic Features of Scars

	Strongly disagree	Disagree	Neutral	Agree	Strongly agree
16) Dermoscopic features of scars should be included in Level 1	○	○	○	○	○
17) Dermoscopic features of scars should be included in Level 2	○	○	○	○	○
18) Dermoscopic features of scars should NOT be included at either level	○	○	○	○	○

19) Please include your suggestions for additional diagnoses and any comments here: _____ Optional

Submit

Save & Return Later

Powered by REDCap

J Am Board Fam Med: first published as 10.3122/jabfm.2022.220143R1 on 9 February 2023. Downloaded from http://www.jabfm.org/ on 20 April 2024 by guest. Protected by copyright.

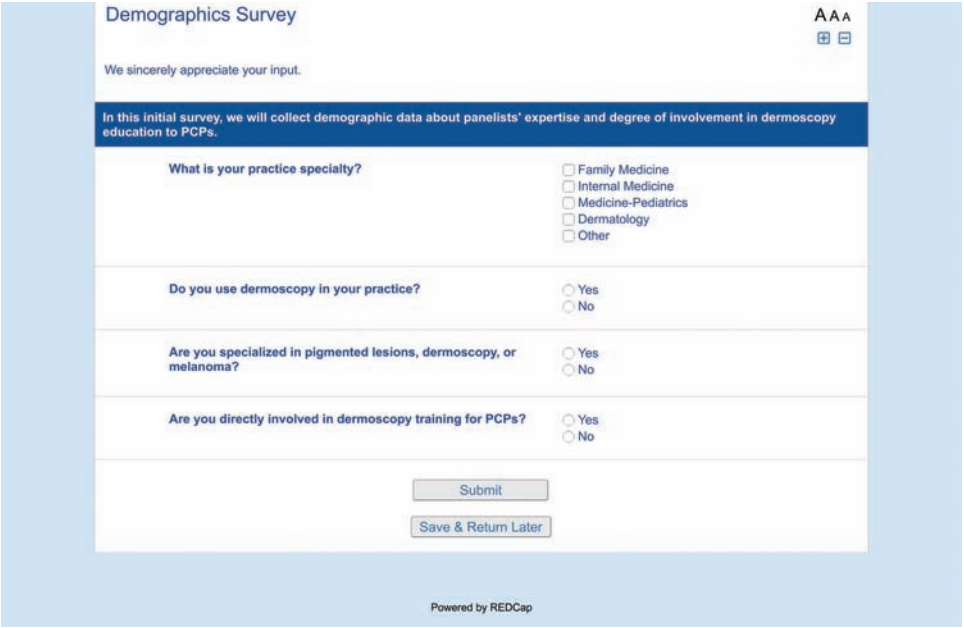

Demographics Survey

We sincerely appreciate your input.

In this initial survey, we will collect demographic data about panelists' expertise and degree of involvement in dermoscopy education to PCPs.

What is your practice specialty?
- Family Medicine
- Internal Medicine
- Medicine-Pediatrics
- Dermatology
- Other

Do you use dermoscopy in your practice?
- Yes
- No

Are you specialized in pigmented lesions, dermoscopy, or melanoma?
- Yes
- No

Are you directly involved in dermoscopy training for PCPs?
- Yes
- No

Submit

Save & Return Later

Powered by REDCap

J Am Board Fam Med: first published as 10.3122/jabfm.2022.220143R1 on 9 February 2023. Downloaded from http://www.jabfm.org/ on 20 April 2024 by guest. Protected by copyright.

Dermatologic Diagnoses: Round 2

Returning?

AAA

We appreciate your continued interest in participating in the PCP Dermoscopy Education Working Group.

About Us

We are a research team from The University of Texas MD Anderson Cancer Center, and we are conducting a research study supervised by Dr. Kelly Nelson.

Study Goal

The goal of this research study is the development and refinement of an expert consensus statement regarding key knowledge acquisition and self-efficacy learning aspects and assessment instruments for **Primary Care Provider (PCP)-targeted educational instruments seeking to improve skin cancer diagnosis**.

An initial consensus statement identifying key learning aspects was compiled using a systematic literature review and review of initial pilot instruments.

Study Details

If you agree to take part in this study, you will be asked to complete a series of electronic surveys listing potential learning aspects in which each participant will rate the appropriateness of inclusion for each objective. A modified Delphi process (a common iterative method used to obtain the consensus opinions of a group of authorities on a given topic) is being utilized for this effort. Feedback will be collected and assessed, and then a modified survey will be developed based on feedback and then re-administered to collect another round of feedback. This process will be repeated until consensus is reached.

You may complete the survey(s) either on paper or online using a web link sent by the study staff. Each survey should take up to 15 minutes to complete. The time between surveys will be about 1 month. Your total time or participation may be up to 3 months.

Study Participation

Your participation in this research is voluntary. If you choose not to take part, it will not affect your employment or traineeship at your institution in any way. If you do choose to take part in this research, your responses will also not affect your employment or trainee status.

There will be no compensation for your participation in this study.

Protection of Confidentiality

The research team is committed to protecting your confidentiality at all times and in all circumstances. Your response to the study evaluation and surveys will not be made public. Any study survey data will be de-identified and/or reported in aggregate form for analyses. No identifying information will be used in the publication of the findings.

All electronic study data will be stored in an institutional database indefinitely. Participants who choose to fill out a paper copy of the survey(s) will have their responses stored in a locked file cabinet within the research team's locked office.

Your personally identifying information will be stored in a password-protected database, and your information and responses will be labeled with a study-specific participant identification number (participant ID) that will de-identify you from your responses before the analyses. Only certain members of the study staff will have the key to link your study ID to your personal information. Your personal information (name, date of survey, and email address) will be used to merge multiple rounds of survey responses and will not be shared with other survey participants.

Consent Statement

You have read the description of the study and have decided to participate in the research project described here. You understand that you may refuse to answer any (or all) of the questions at this or any other time. You understand that there is a possibility that you might be contacted in the future about this but that you are free to refuse any further participation if you wish.

You may withdraw your authorization at any time, in writing, for any reason as long as that information can be connected to you. You can learn more about how to withdraw your authorization by calling [redacted] or by contacting the study chair Dr. Kelly Nelson.

1) **By checking this box and proceeding to the Round 2 survey, I acknowledge the above statement and voluntarily consent to participate in the study.** ☐ I consent

Submit

Save & Return Later

Powered by REDCap

J Am Board Fam Med: first published as 10.3122/jabfm.2022.220143R1 on 9 February 2023. Downloaded from http://www.jabfm.org/ on 20 April 2024 by guest. Protected by copyright.

Round 2: Survey Objective

Thank you for your continued interest in participating in this study. Please read this page carefully.

Dermatologic Diagnoses Survey Series

The objective of this "Dermatologic Diagnoses" survey series is to develop an expert-approved list of common dermatologic diagnoses to be included in dermoscopy education targeted towards PCPs.

Given the diversity of interest in, bandwidth for, and engagement with dermoscopy across the PCP spectrum, we are developing two different levels of proficiency standards for PCPs :

- **Level 1 (Foundational) —** PCPs who desire a basic yet practical understanding of dermoscopy and its applications for the detection of skin cancer should be able to recognize these diagnoses with appropriate training.
- **Level 2 (Intermediate) —** PCPs who are highly interested in dermoscopy and desire further training in dermoscopy beyond the Foundational Level should be able to recognize these diagnoses. With appropriate training, recognition of these "above and beyond" diagnoses would demonstrate an additional level of mastery beyond Level 1 (Foundational).

Important Clarification for Panelists: The diagnoses in Level 2 are conceptualized as adding onto those in Level 1. Only learners who complete Level 1 *and* who desire further training in dermoscopy would progress to Level 2. The diagnoses taught in Level 2 should be considered "in addition to" the diagnoses taught in Level 1.

Round 2 Survey Objective

The objective of **Round 2** of the "Dermatologic Diagnoses" survey series is to re-vote on diagnoses that did not reach a clear consensus for inclusion in Level 1 or 2 (>50% but < 70% agreement) and to vote on new suggestions for additional diagnoses that were written in by panelists.

Round 2 Survey Overview

This survey will be divided into 5 sections:

1. Non-melanocytic lesions
2. Benign melanocytic lesions
3. Melanoma
4. Special sites
5. Other (including skin infections & infestations)

We will ask you to re-vote on survey items that reached >50% agreement but not >70% agreement in Round 1. As before, you will consider whether the specific diagnosis should be included in the learning objectives for PCP-targeted dermoscopy education, and you will then answer the following questions:

1. Should the diagnosis be included in a **Level 1 (Foundational)** proficiency standard for PCPs?
2. Should the diagnosis be included in a **Level 2 (Intermediate)** proficiency standard for PCPs if not included in Level 1?
3. Should the diagnosis NOT be included at either level?

You will also be given the opportunity to write in suggestions for additional diagnoses that will then be voted on by the panel in a subsequent survey.

Important Clarification for Panelists: We appreciate that there may be subtleties in presentations for the specific diagnoses introduced in Level 1 that could be further explored in Level 2 (e.g., nodular BCC could be taught in Level 1, but superficial BCC could be taught in Level 2). In the interest of reaching a consensus, we would like you to consider the "gold standard" for each diagnostic category (e.g., for BCC, we would like you to consider whether the most *classic* presentation of BCC should belong in Level 1, Level 2, or neither.)

Time Estimate

We estimate that this survey will take you 10 minutes or less to complete.

1) **By checking this box, I acknowledge that I have read the objective of this survey.** ☐ I acknowledge

Submit

Save & Return Later

Powered by REDCap

J Am Board Fam Med: first published as 10.3122/jabfm.2022.220143R1 on 9 February 2023. Downloaded from http://www.jabfm.org/ on 20 April 2024 by guest. Protected by copyright.

Section 1: Nonmelanocytic Lesions

AAA

We would like to identify the dermatologic diagnoses that should be included in dermoscopy training programs targeted towards PCPs. The panel has reached a consensus on a number of diagnoses. For those diagnoses that did not reach a consensus, we ask you to re-vote.

As in Round 1, we ask you to rate how strongly you would agree or disagree with each of the following statements regarding a specific diagnosis for a particular level of proficiency:

- **Level 1 (Foundational)** — PCPs who desire a basic yet practical understanding of dermoscopy and its applications for the detection of skin cancer should be able to recognize these diagnoses with appropriate training.
- **Level 2 (Intermediate)** — PCPs who are highly interested in dermoscopy and desire further training in dermoscopy beyond the Foundational Level should be able to recognize these diagnoses. With appropriate training, recognition of these "above and beyond" diagnoses would demonstrate an additional level of mastery beyond Level 1 (Foundational).

Please note that a "Neutral" vote will not contribute towards a consensus on the inclusion or exclusion of that specific diagnosis.

Basal Cell Carcinoma
Consensus: Basal Cell Carcinoma should be included in Level 1 (Foundational)

Actinic Keratosis
Consensus: Actinic Keratosis should be included in Level 1 (Foundational)

Squamous Cell Carcinoma
Consensus: Squamous Cell Carcinoma should be included in Level 1 (Foundational)

Simple Lentigo
Consensus: Simple Lentigo should be included in Level 1 (Foundational)

Solar Lentigo
Consensus: Solar Lentigo should be included in Level 1 (Foundational)

Seborrheic Keratosis
Consensus: Seborrheic Keratosis should be included in Level 1 (Foundational)

Angioma
Consensus: Angioma should be included in Level 1 (Foundational)

Dermatofibroma
Consensus: Dermatofibroma should be included in Level 1 (Foundational)

Sebaceous Hyperplasia
Consensus: Sebaceous Hyperplasia should at least be included in Level 2 (Intermediate) if not included in Level 1 (Foundational)

Should Sebaceous Hyperplasia be included in Level 1 (Foundational) or Level 2 (Intermediate)?

	Strongly disagree	Disagree	Neutral	Agree	Strongly agree
1) Sebaceous Hyperplasia should be included in Level 1 (Foundational)	○	○	○	○	○
2) Sebaceous Hyperplasia should be included in Level 2 (Intermediate)	○	○	○	○	○

Pigmented Actinic Keratosis

J Am Board Fam Med: first published as 10.3122/jabfm.2022.220143R1 on 9 February 2023. Downloaded from http://www.jabfm.org/ on 20 April 2024 by guest. Protected by copyright.

Consensus: Pigmented Actinic Keratosis should NOT be included in Level 1 (Foundational)

What about Level 2 (Intermediate)?

	Strongly disagree	Disagree	Neutral	Agree	Strongly agree
3) Pigmented Actinic Keratosis should be included in Level 2 (Intermediate)	○	○	○	○	○
4) Pigmented Actinic Keratosis should NOT be included at either level	○	○	○	○	○

Lichen Planus-Like Keratosis (Benign Lichenoid Keratosis)
Consensus: Lichen Planus-Like Keratosis should NOT be included in Level 1 (Foundational)

What about Level 2 (Intermediate)?

	Strongly disagree	Disagree	Neutral	Agree	Strongly agree
5) Lichen Planus-Like Keratosis should be included in Level 2 (Intermediate)	○	○	○	○	○
6) Lichen Planus-Like Keratosis should NOT be included at either level	○	○	○	○	○

Angiokeratoma
Consensus: Angiokeratoma should NOT be included in Level 1 (Foundational)

What about Level 2 (Intermediate)?

	Strongly disagree	Disagree	Neutral	Agree	Strongly agree
7) Angiokeratoma should be included in Level 2 (Intermediate)	○	○	○	○	○
8) Angiokeratoma should NOT be included at either level	○	○	○	○	○

Clear Cell Acanthoma
Consensus: Clear Cell Acanthoma should NOT be included in Level 1 (Foundational)

What about Level 2 (Intermediate)?

	Strongly disagree	Disagree	Neutral	Agree	Strongly agree
9) Clear Cell Acanthoma should be included in Level 2 (Intermediate)	○	○	○	○	○
10) Clear Cell Acanthoma should NOT be included at either level	○	○	○	○	○

Squamous Cell Carcinoma in situ (Bowen's disease)
Consensus: none

	Strongly disagree	Disagree	Neutral	Agree	Strongly agree
11) Squamous Cell Carcinoma in situ should be included in Level 1 (Foundational)	○	○	○	○	○
12) If Squamous Cell Carcinoma in situ does not reach consensus for inclusion in Level 1 (Foundational), it should be included in Level 2 (Intermediate)	○	○	○	○	○
13) Squamous Cell Carcinoma in situ should NOT be included at either level	○	○	○	○	○

J Am Board Fam Med: first published as 10.3122/jabfm.2022.220143R1 on 9 February 2023. Downloaded from http://www.jabfm.org/ on 20 April 2024 by guest. Protected by copyright.

Keratoacanthoma
Consensus: none

	Strongly disagree	Disagree	Neutral	Agree	Strongly agree
14) Keratoacanthoma should be included in Level 1 (Foundational)	○	○	○	○	○
15) If Keratoacanthoma does not reach consensus for inclusion in Level 1 (Foundational), it should be included in Level 2 (Intermediate)	○	○	○	○	○
16) Keratoacanthoma should be NOT be included at either level	○	○	○	○	○

Merkel Cell Carcinoma (NEW)

	Strongly disagree	Disagree	Neutral	Agree	Strongly agree
17) Merkel Cell Carcinoma should be included in Level 1 (Foundational)	○	○	○	○	○
18) If Merkel Cell Carcinoma does not reach consensus for inclusion in Level 1 (Foundational), it should be included in Level 2 (Intermediate)	○	○	○	○	○
19) Merkel Cell Carcinoma should NOT be included at either level	○	○	○	○	○

Porokeratosis (NEW)

	Strongly disagree	Disagree	Neutral	Agree	Strongly agree
20) Porokeratosis should included in Level 1 (Foundational)	○	○	○	○	○
21) If Porokeratosis does not reach consensus for inclusion in Level 1 (Foundational), it should included in Level 2 (Intermediate)	○	○	○	○	○
22) Porokeratosis should NOT be included at either level	○	○	○	○	○

23) Please include your suggestions for additional diagnoses and any comments here: [ ] Optional

Submit

Save & Return Later

Powered by REDCap

J Am Board Fam Med: first published as 10.3122/jabfm.2022.220143R1 on 9 February 2023. Downloaded from http://www.jabfm.org/ on 20 April 2024 by guest. Protected by copyright.

Section 2: Benign Melanocytic Lesions

AAA

We would like to identify the dermatologic diagnoses that should be included in dermoscopy training programs targeted towards PCPs. The panel has reached a consensus on a number of diagnoses. For those diagnoses that did not reach a consensus, we ask you to re-vote.

As in Round 1, we ask you to rate how strongly you would agree or disagree with each of the following statements regarding a specific diagnosis for a particular level of proficiency:

- **Level 1 (Foundational)** — PCPs who desire a basic yet practical understanding of dermoscopy and its applications for the detection of skin cancer should be able to recognize these diagnoses with appropriate training.
- **Level 2 (Intermediate)** — PCPs who are highly interested in dermoscopy and desire further training in dermoscopy beyond the Foundational Level should be able to recognize these diagnoses. With appropriate training, recognition of these "above and beyond" diagnoses would demonstrate an additional level of mastery beyond Level 1 (Foundational).

Please note that a "Neutral" vote will not contribute towards a consensus on the inclusion or exclusion of that specific diagnosis.

Overview of benign nevi patterns (e.g., globular pattern, reticular network)
Consensus: An overview of benign nevi patterns should be included in Level 1 (Foundational)

Intradermal Nevi
Consensus: Intradermal Nevi should be included in Level 1 (Foundational)

Congenital Melanocytic Nevi
Consensus: Congenital Melanocytic Nevi should NOT be included in Level 1 (Foundational)
Consensus: Congenital Melanocytic Nevi should be included in Level 2 (Intermediate)

Spitz Nevi
Consensus: Spitz Nevi should NOT be included in Level 1 (Foundational)
Consensus: Spitz Nevi should be included in Level 2 (Intermediate)

Blue Nevi
Consensus: Blue Nevi should at least be included in Level 2 (Intermediate) if not included in Level 1 (Foundational)

Should Blue Nevi be included in Level 1 (Foundational) or Level 2 (Intermediate)?

	Strongly disagree	Disagree	Neutral	Agree	Strongly agree
1) Blue Nevi should be included in Level 1 (Foundational)	○	○	○	○	○
2) Blue Nevi should be included in Level 2 (Intermediate)	○	○	○	○	○

Recurrent Nevi (Persistent Nevi)
Consensus: Recurrent Nevi should NOT be included in Level 1 (Foundational)

What about Level 2 (Intermediate)?

	Strongly disagree	Disagree	Neutral	Agree	Strongly agree
3) Recurrent Nevi should be included in Level 2 (Intermediate)	○	○	○	○	○
4) Recurrent Nevi should NOT be included at either level	○	○	○	○	○

Halo Nevi (NEW)

J Am Board Fam Med: first published as 10.3122/jabfm.2022.220143R1 on 9 February 2023. Downloaded from http://www.jabfm.org/ on 20 April 2024 by guest. Protected by copyright.

	Strongly disagree	Disagree	Neutral	Agree	Strongly agree
5) Halo Nevi should be included in Level 1 (Foundational)	○	○	○	○	○
6) If Halo Nevi do not reach consensus for Level 1 (Foundational), they should be included in Level 2 (Intermediate)	○	○	○	○	○
7) Halo Nevi should NOT be included in either level	○	○	○	○	○

Combined Nevi (NEW)

	Strongly disagree	Disagree	Neutral	Agree	Strongly agree
8) Combined Nevi should be included in Level 1 (Foundational)	○	○	○	○	○
9) If Combined Nevi do not reach consensus for Level 1, they should be included in Level 2 (Intermediate)	○	○	○	○	○
10) Combined Nevi should be NOT included at either level	○	○	○	○	○

Ink Spot Lentigo (Reticulated Black Solar Lentigo) (NEW)

	Strongly disagree	Disagree	Neutral	Agree	Strongly agree
11) Ink Spot Lentigo should be included in Level 1 (Foundational)	○	○	○	○	○
12) If Ink Spot Lentigo does not reach consensus for Level 1 (Foundational), it should be included in Level 2 (Intermediate)	○	○	○	○	○
13) Ink Spot Lentigo should NOT be included at either level	○	○	○	○	○

14) Please include your suggestions for additional diagnoses and any comments here: [ ] Optional

Submit

Save & Return Later

Powered by REDCap

J Am Board Fam Med: first published as 10.3122/jabfm.2022.220143R1 on 9 February 2023. Downloaded from http://www.jabfm.org/ on 20 April 2024 by guest. Protected by copyright.

Section 3: Melanoma

AAA

We would like to identify the dermatologic diagnoses that should be included in dermoscopy training programs targeted towards PCPs. The panel has reached a consensus on a number of diagnoses. For those diagnoses that did not reach a consensus, we ask you to re-vote.

As in Round 1, we ask you to rate how strongly you would agree or disagree with each of the following statements regarding a specific diagnosis for a particular level of proficiency:

- **Level 1 (Foundational)** — PCPs who desire a basic yet practical understanding of dermoscopy and its applications for the detection of skin cancer should be able to recognize these diagnoses with appropriate training.
- **Level 2 (Intermediate)** — PCPs who are highly interested in dermoscopy and desire further training in dermoscopy beyond the Foundational Level should be able to recognize these diagnoses. With appropriate training, recognition of these "above and beyond" diagnoses would demonstrate an additional level of mastery beyond Level 1 (Foundational).

Please note that a "Neutral" vote will not contribute towards a consensus on the inclusion or exclusion of that specific diagnosis.

Overview of melanoma patterns (e.g., blue-white veil, regression structures)
Consensus: An overview of melanoma patterns should be included in Level 1 (Foundational)

Acral Lentiginous Melanoma
Consensus: Acral Lentiginous Melanoma should NOT be included in Level 1 (Foundational)
Consensus: Acral Lentiginous Melanoma should be included in Level 2 (Intermediate)

Lentigo Maligna Melanoma (melanoma on chronically sun-damaged skin of the head/neck)
Consensus: Lentigo Maligna Melanoma should NOT be included in Level 1 (Foundational)
Consensus: Lentigo Maligna Melanoma should be included in Level 2 (Intermediate)

Amelanotic/Hypomelanotic Melanoma
Consensus: Amelanotic/Hypomelanotic Melanoma should NOT be included in Level 1 (Foundational)

What about Level 2?

	Strongly disagree	Disagree	Neutral	Agree	Strongly agree
1) Amelanotic/Hypomelanotic Melanoma should be included in Level 2 (Intermediate)	○	○	○	○	○
2) Amelanotic/Hypomelanotic Melanoma should NOT be included at either level	○	○	○	○	○

Nevoid Melanoma (NEW)

	Strongly disagree	Disagree	Neutral	Agree	Strongly agree
3) Nevoid Melanoma should be included in Level 1 (Foundational)	○	○	○	○	○
4) If Nevoid Melanoma does not reach consensus for inclusion in Level 1 (Foundational), it should be included in Level 2 (Intermediate)	○	○	○	○	○
5) Nevoid Melanoma should NOT be included at either level	○	○	○	○	○

Desmoplastic Melanoma (NEW)

J Am Board Fam Med: first published as 10.3122/jabfm.2022.220143R1 on 9 February 2023. Downloaded from http://www.jabfm.org/ on 20 April 2024 by guest. Protected by copyright.

	Strongly disagree	Disagree	Neutral	Agree	Strongly agree
6) Desmoplastic Melanoma should be included in Level 1 (Foundational)	○	○	○	○	○
7) If Desmoplastic Melanoma does not reach consensus for inclusion in Level 1 (Foundational), it should be included in Level 2 (Intermediate)	○	○	○	○	○
8) Desmoplastic Melanoma should NOT be included at either level	○	○	○	○	○

Verrucous Melanoma (NEW)

	Strongly disagree	Disagree	Neutral	Agree	Strongly agree
9) Verrucous Melanoma should be included in Level 1 (Foundational)	○	○	○	○	○
10) If Verrucous Melanoma does not reach consensus for inclusion in Level 1 (Foundational), it should be included in Level 2 (Intermediate)	○	○	○	○	○
11) Verrucous Melanoma should NOT be included at either level	○	○	○	○	○

12) Please include your suggestions for additional diagnoses and any comments here: [ ] Optional

Submit

Save & Return Later

Powered by REDCap

J Am Board Fam Med: first published as 10.3122/jabfm.2022.220143R1 on 9 February 2023. Downloaded from http://www.jabfm.org/ on 20 April 2024 by guest. Protected by copyright.

Section 4: Special Sites

AAA

We would like to identify the dermatologic diagnoses that should be included in dermoscopy training programs targeted towards PCPs. The panel has reached a consensus on a number of diagnoses. For those diagnoses that did not reach a consensus, we ask you to re-vote.

As in Round 1, we ask you to rate how strongly you would agree or disagree with each of the following statements regarding a specific diagnosis for a particular level of proficiency:

- **Level 1 (Foundational)** — PCPs who desire a basic yet practical understanding of dermoscopy and its applications for the detection of skin cancer should be able to recognize these diagnoses with appropriate training.
- **Level 2 (Intermediate)** — PCPs who are highly interested in dermoscopy and desire further training in dermoscopy beyond the Foundational Level should be able to recognize these diagnoses. With appropriate training, recognition of these "above and beyond" diagnoses would demonstrate an additional level of mastery beyond Level 1 (Foundational).

Please note that a "Neutral" vote will not contribute towards a consensus on the inclusion or exclusion of that specific diagnosis.

Subungual Hemorrhage
Consensus: Subungual Hemorrhage should be included in Level 1 (Foundational)

Facial Sites: Dermoscopic features of the face (i.e., pseudonetwork)
Consensus: Dermoscopic features of the face should NOT be included in Level 1 (Foundational)
Consensus: Dermoscopic features of the face should be included in Level 2 (Intermediate)

Acral: Benign patterns of acral nevi
Consensus: Benign patterns of acral nevi should at least be included in Level 2 (Intermediate) if not included in Level 1 (Foundational)

Should benign patterns of acral nevi be included in Level 1 (Foundational) or Level 2 (Intermediate)?

	Strongly disagree	Disagree	Neutral	Agree	Strongly agree
1) Benign patterns of acral nevi should be included in Level 1 (Foundational)	○	○	○	○	○
2) Benign patterns of acral nevi should be included in Level 2 (Intermediate)	○	○	○	○	○

Nails: Lentigo of the Nail (melanotic macule of the nail)
Consensus: Lentigo of the Nail should NOT be included in Level 1 (Foundational)

What about Level 2 (Intermediate)?

	Strongly disagree	Disagree	Neutral	Agree	Strongly agree
3) Lentigo of the Nail should be included in Level 2 (Intermediate)	○	○	○	○	○
4) Lentigo of the Nail should NOT be included at either level	○	○	○	○	○

Nails: Melanoma of the Nail
Consensus: Melanoma of the Nail should NOT be included in Level 1 (Foundational)

What about Level 2 (Intermediate)?

	Strongly disagree	Disagree	Neutral	Agree	Strongly agree
5) Melanoma of the Nail should be included in Level 2 (Intermediate)	○	○	○	○	○
6) Melanoma of the Nail should NOT be included at either level	○	○	○	○	○

J Am Board Fam Med: first published as 10.3122/jabfm.2022.220143R1 on 9 February 2023. Downloaded from http://www.jabfm.org/ on 20 April 2024 by guest. Protected by copyright.

Acral: Talon Noir (NEW)

	Strongly disagree	Disagree	Neutral	Agree	Strongly agree
7) Talon Noir should be included in Level 1 (Foundational)	○	○	○	○	○
8) If Talon Noir does not reach consensus for inclusion in Level 1 (Foundational), it should be included in Level 2 (Intermediate)	○	○	○	○	○
9) Talon Noir should NOT be included at either level	○	○	○	○	○

Mucous Membranes: Nevi of the mucosa (NEW)

	Strongly disagree	Disagree	Neutral	Agree	Strongly agree
10) Nevi of the mucosa should be included in Level 1 (Foundational)	○	○	○	○	○
11) If nevi of the mucosa do not reach consensus for inclusion in Level 1 (Foundational), they should be included in Level 2 (Intermediate)	○	○	○	○	○
12) Nevi of the mucosa should NOT be included at either level	○	○	○	○	○

Mucocutaneous junction: Nevi of the mucocutaneous junction (NEW)

	Strongly disagree	Disagree	Neutral	Agree	Strongly agree
13) Nevi of the mucocutaneous junction should be included in Level 1 (Foundational)	○	○	○	○	○
14) If nevi of the mucocutaneous junction do not reach consensus for inclusion in Level 1 (Foundational), they should be included in Level 2 (Intermediate)	○	○	○	○	○
15) Nevi of the mucocutaneous junction should NOT be included at either level	○	○	○	○	○

16) Please include your suggestions for additional diagnoses and any comments here: [ ] Optional

Submit

Save & Return Later

Powered by REDCap

J Am Board Fam Med: first published as 10.3122/jabfm.2022.220143R1 on 9 February 2023. Downloaded from http://www.jabfm.org/ on 20 April 2024 by guest. Protected by copyright.

Section 5: Other (including skin infections & infestations)

We would like to identify the dermatologic diagnoses that should be included in dermoscopy training programs targeted towards PCPs. The panel has reached a consensus on a number of diagnoses. For those diagnoses that did not reach a consensus, we ask you to re-vote.

As in Round 1, we ask you to rate how strongly you would agree or disagree with each of the following statements regarding a specific diagnosis for a particular level of proficiency:

- **Level 1 (Foundational)** — PCPs who desire a basic yet practical understanding of dermoscopy and its applications for the detection of skin cancer should be able to recognize these diagnoses with appropriate training.
- **Level 2 (Intermediate)** — PCPs who are highly interested in dermoscopy and desire further training in dermoscopy beyond the Foundational Level should be able to recognize these diagnoses. With appropriate training, recognition of these "above and beyond" diagnoses would demonstrate an additional level of mastery beyond Level 1 (Foundational).

Please note that a "Neutral" vote will not contribute towards a consensus on the inclusion or exclusion of that specific diagnosis.

Verruca (Warts)
Consensus: Verruca should be included in Level 1 (Foundational)

Radiation Tattoo
Consensus: Radiation Tattoo should NOT be included in Level 1 (Foundational)

What about Level 2 (Intermediate)?

	Strongly disagree	Disagree	Neutral	Agree	Strongly agree
1) Radiation Tattoo should be included in Level 2 (Intermediate)	○	○	○	○	○
2) Radiation Tattoo should NOT be included at either level	○	○	○	○	○

Dermoscopic Features of Scars
Consensus: Dermoscopic features of scars should NOT be included in Level 1 (Foundational)

What about Level 2 (Intermediate)?

	Strongly disagree	Disagree	Neutral	Agree	Strongly agree
3) Dermoscopic features of scars should be included in Level 2	○	○	○	○	○
4) Dermoscopic features of scars should NOT be included at either level	○	○	○	○	○

Scabies
Consensus: none

	Strongly disagree	Disagree	Neutral	Agree	Strongly agree
5) Scabies should be included in Level 1 (Foundational)	○	○	○	○	○
6) If Scabies does not reach consensus for inclusion in Level 1 (Foundational), it should be included in Level 2 (Intermediate)	○	○	○	○	○
7) Scabies should NOT be included at either level	○	○	○	○	○

J Am Board Fam Med: first published as 10.3122/jabfm.2022.220143R1 on 9 February 2023. Downloaded from http://www.jabfm.org/ on 20 April 2024 by guest. Protected by copyright.

Molluscum Contagiosum
Consensus: none

	Strongly disagree	Disagree	Neutral	Agree	Strongly agree
8) Molluscum Contagiosum should be included in Level 1 (Foundational)	○	○	○	○	○
9) If Molluscum Contagiosum does not reach consensus for inclusion in Level 1 (Foundational), it should be included in Level 2 (Intermediate)	○	○	○	○	○
10) Molluscum Contagiosum should NOT be included at either level	○	○	○	○	○

Venous Lake (example of a nonmelanocytic lesion on mucocutaneous junction)

	Strongly disagree	Disagree	Neutral	Agree	Strongly agree
11) Venous Lake should be included in Level 1 (Foundational)	○	○	○	○	○
12) If Venous Lake does not reach consensus for inclusion in Level 1 (Foundational), it should be included in Level 2 (Intermediate)	○	○	○	○	○
13) Venous Lake should NOT be included at either level	○	○	○	○	○

Psoriasis (NEW)

	Strongly disagree	Disagree	Neutral	Agree	Strongly agree
14) Psoriasis should be included in Level 1 (Foundational)	○	○	○	○	○
15) If Psoriasis does not reach consensus for inclusion in Level 1 (Foundational), it should be included in Level 2 (Intermediate)	○	○	○	○	○
16) Psoriasis should NOT be included at either level	○	○	○	○	○

Atopic Dermatitis (Eczema) (NEW)

	Strongly disagree	Disagree	Neutral	Agree	Strongly agree
17) Atopic Dermatitis should be included in Level 1 (Foundational)	○	○	○	○	○
18) If Atopic Dermatitis does not reach consensus for inclusion in Level 1 (Foundational), it should be included in Level 2 (Intermediate)	○	○	○	○	○
19) Atopic Dermatitis should NOT be included at either level	○	○	○	○	○

20) Please include your suggestions for additional diagnoses and any comments here: [ ] Optional

Submit

Save & Return Later

Powered by REDCap

J Am Board Fam Med: first published as 10.3122/jabfm.2022.220143R1 on 9 February 2023. Downloaded from http://www.jabfm.org/ on 20 April 2024 by guest. Protected by copyright.

Dermatologic Diagnoses: Round 3

Returning?

AAA

We appreciate your continued interest in participating in the PCP Dermoscopy Education Working Group.

About Us

We are a research team from The University of Texas MD Anderson Cancer Center, and we are conducting a research study supervised by Dr. Kelly Nelson.

Study Goal

The goal of this research study is the development and refinement of an expert consensus statement regarding key knowledge acquisition and self-efficacy learning aspects and assessment instruments for **Primary Care Provider (PCP)-targeted educational instruments seeking to improve skin cancer diagnosis**.

An initial consensus statement identifying key learning aspects was compiled using a systematic literature review and review of initial pilot instruments.

Study Details

If you agree to take part in this study, you will be asked to complete a series of electronic surveys listing potential learning aspects in which each participant will rate the appropriateness of inclusion for each objective. A modified Delphi process (a common iterative method used to obtain the consensus opinions of a group of authorities on a given topic) is being utilized for this effort. Feedback will be collected and assessed, and then a modified survey will be developed based on feedback and then re-administered to collect another round of feedback. This process will be repeated until consensus is reached.

You may complete the survey(s) either on paper or online using a web link sent by the study staff. Each survey should take up to 15 minutes to complete. The time between surveys will be about 1 month. Your total time or participation may be up to 3 months.

Study Participation

Your participation in this research is voluntary. If you choose not to take part, it will not affect your employment or traineeship at your institution in any way. If you do choose to take part in this research, your responses will also not affect your employment or trainee status.

There will be no compensation for your participation in this study.

Protection of Confidentiality

The research team is committed to protecting your confidentiality at all times and in all circumstances. Your response to the study evaluation and surveys will not be made public. Any study survey data will be de-identified and/or reported in aggregate form for analyses. No identifying information will be used in the publication of the findings.

All electronic study data will be stored in an institutional database indefinitely. Participants who choose to fill out a paper copy of the survey(s) will have their responses stored in a locked file cabinet within the research team's locked office.

Your personally identifying information will be stored in a password-protected database, and your information and responses will be labeled with a study-specific participant identification number (participant ID) that will de-identify you from your responses before the analyses. Only certain members of the study staff will have the key to link your study ID to your personal information. Your personal information (name, date of survey, and email address) will be used to merge multiple rounds of survey responses and will not be shared with other survey participants.

Consent Statement

You have read the description of the study and have decided to participate in the research project described here. You understand that you may refuse to answer any (or all) of the questions at this or any other time. You understand that there is a possibility that you might be contacted in the future about this but that you are free to refuse any further participation if you wish.

You may withdraw your authorization at any time, in writing, for any reason as long as that information can be connected to you. You can learn more about how to withdraw your authorization by calling [redacted] or by contacting the study chair Dr. Kelly Nelson.

1) **By checking this box and proceeding to the Round 3 survey, I acknowledge the above statement and voluntarily consent to participate in the study.** ☐ I consent

Submit

Save & Return Later

Powered by REDCap

J Am Board Fam Med: first published as 10.3122/jabfm.2022.220143R1 on 9 February 2023. Downloaded from http://www.jabfm.org/ on 20 April 2024 by guest. Protected by copyright.

Round 3: Survey Objective

AAA

Thank you for your continued interest in participating in this study.

Round 3 Survey Objective

The objective of **Round 3** of the "Dermatologic Diagnoses" survey series is to re-vote on diagnoses that did not reach a clear consensus for inclusion in Level 1 or 2 and to vote on suggestions for additional diagnoses written in by panelists.

Round 3 Survey Overview

We will ask you to re-vote on survey items that reached **>60%** agreement but **< 70%** agreement in Round 2. As before, you will consider whether the specific diagnosis should be included in the learning objectives for PCP-targeted dermoscopy education, and you will answer the following questions:

1. Should the diagnosis be included in **Level 1 (Foundational)**?
2. Should the diagnosis be included in **Level 2 (Intermediate)** if not included in Level 1?

We will not be taking suggestions for additional diagnoses at this time.

Important Clarification for Panelists: The diagnoses in Level 2 are conceptualized as adding onto those in Level 1. Only learners who complete Level 1 *and* who desire further training in dermoscopy would progress to Level 2. The diagnoses taught in Level 2 should be considered "in addition to" the diagnoses taught in Level 1.

Time Estimate

We estimate that this survey will take you 5 minutes or less to complete.

1) **By checking this box, I acknowledge that I have read the objective of this survey.** ☐ I acknowledge

Submit

Save & Return Later

Powered by REDCap

J Am Board Fam Med: first published as 10.3122/jabfm.2022.220143R1 on 9 February 2023. Downloaded from http://www.jabfm.org/ on 20 April 2024 by guest. Protected by copyright.

Diagnoses: All Categories

AAA

We would like to identify the dermatologic diagnoses that should be included in dermoscopy training programs targeted towards PCPs.

As in Round 2, we ask you to vote whether you agree/disagree with each of the following statements regarding a specific diagnosis for a particular level of proficiency:

- **Level 1 (Foundational)** — PCPs who desire a basic yet practical understanding of dermoscopy and its applications for the detection of skin cancer should be able to recognize these diagnoses with appropriate training.
- **Level 2 (Intermediate)** — PCPs who are highly interested in dermoscopy and desire further training in dermoscopy beyond the Foundational Level should be able to recognize these diagnoses. With appropriate training, recognition of these "above and beyond" diagnoses would demonstrate an additional level of mastery beyond Level 1 (Foundational).

For all diagnoses from earlier rounds that did not reach a clear consensus, we will now conduct a majority vote in the interest of reaching a final consensus.

SECTION 1

Majority Vote:
- Level 1 (Foundational)
- Level 2 (Intermediate)

Benign patterns of acral nevi
Consensus: Benign patterns of acral nevi should be included in Level 2 if not included in Level 1.

	Level 1 (Foundational)	Level 2 (Intermediate)
1) Should benign patterns of acral nevi be included in Level 1 or 2?	○	○

Mollsucum Contagiosum
Consensus: Molluscum Contagiosum should be included in Level 2 if not included in Level 1.

	Level 1 (Foundational)	Level 2 (Intermediate)
2) Should Molluscum Contagiosum be included in Level 1 or 2?	○	○

SECTION 2

Majority Vote:
- Level 2 (Intermediate)
- Neither Level 1 nor 2

Lichen Planus-Like Keratosis (Benign Lichenoid Keratosis)
Consensus: Lichen Planus-Like Keratosis should NOT be included in Level 1 (Foundational)

What about Level 2?

	Level 2 (Intermediate)	Neither Level 1 nor 2
3) Should Lichen Planus-Like Keratosis be included in Level 2 (Intermediate) or neither Level 1 nor 2?	○	○

Talon Noir
Consensus: Talon Noir should NOT be included in Level 1 Foundational)

What about Level 2?

	Level 2 (Intermediate)	Neither Level 1 nor 2
4) Should Talon Noir should be included in Level 2 (Intermediate) or neither Level 1 nor 2?	○	○

J Am Board Fam Med: first published as 10.3122/jabfm.2022.220143R1 on 9 February 2023. Downloaded from http://www.jabfm.org/ on 20 April 2024 by guest. Protected by copyright.

Radiation Tattoo
Consensus: Radiation Tattoo should NOT be included in Level 1 Foundational)

What about Level 2?

	Level 2 (Intermediate)	Neither Level 1 nor 2
5) Should Radiation Tattoo be included in Level 2 (Intermediate) or neither Level 1 nor 2?	○	○

Dermoscopic features of scars
Consensus: Dermoscopic features of scars should NOT be included in Level 1

What about Level 2?

	Level 2 (Intermediate)	Neither Level 1 nor 2
6) Should Dermoscopic features of scars be included in Level 2 (Intermediate) or neither Level 1 nor 2?	○	○

SECTION 3

New Suggestions:
- Level 1 (Foundational)
- Level 2 (Intermediate)
- Neither Level 1 nor Level 2

	Strongly disagree	Disagree	Neutral	Agree	Strongly agree
7) Poroma should be included in Level 1 (Foundational)	○	○	○	○	○
8) If Poroma does not reach consensus for inclusion in Level 1 (Foundational), it should be included in Level 2 (Intermediate)	○	○	○	○	○
9) Poroma should NOT be included at either level	○	○	○	○	○

Xanthogranuloma (NEW)

	Strongly disagree	Disagree	Neutral	Agree	Strongly agree
10) Xanthogranuloma should included in Level 1 (Foundational)	○	○	○	○	○
11) If Xanthogranuloma does not reach consensus for inclusion in Level 1 (Foundational), it should included in Level 2 (Intermediate)	○	○	○	○	○
12) Xanthogranuloma should NOT be included at either level	○	○	○	○	○

13) Please include any comments here:

We will not be taking suggestions for additional diagnoses at this time.

Submit

Save & Return Later

Powered by REDCap

J Am Board Fam Med: first published as 10.3122/jabfm.2022.220143R1 on 9 February 2023. Downloaded from http://www.jabfm.org/ on 20 April 2024 by guest. Protected by copyright.

Dermoscopic Features: Round 1

Returning?

AAA

We appreciate your interest in participating in the PCP Dermoscopy Education Working Group.

About Us

We are a research team from The University of Texas MD Anderson Cancer Center, and we are conducting a research study supervised by Dr. Kelly Nelson.

Study Goal

The goal of this research study is the development and refinement of an expert consensus statement regarding key knowledge acquisition and self-efficacy learning aspects and assessment instruments for **Primary Care Provider (PCP)-targeted educational instruments seeking to improve skin cancer diagnosis**.

An initial consensus statement identifying key learning aspects was compiled using a systematic literature review and review of initial pilot instruments.

Study Details

If you agree to take part in this study, you will be asked to complete a series of electronic surveys listing potential learning aspects in which each participant will rate the appropriateness of inclusion for each objective. A modified Delphi process (a common iterative method used to obtain the consensus opinions of a group of authorities on a given topic) is being utilized for this effort. Feedback will be collected and assessed, and then a modified survey will be developed based on feedback and then re-administered to collect another round of feedback. This process will be repeated until consensus is reached.

You may complete the survey(s) either on paper or online using a web link sent by the study staff. Each survey should take up to 15 minutes to complete. The time between surveys will be about 1 month. Your total time or participation may be up to 3 months.

Study Participation

Your participation in this research is voluntary. If you choose not to take part, it will not affect your employment or traineeship at your institution in any way. If you do choose to take part in this research, your responses will also not affect your employment or trainee status.

There will be no compensation for your participation in this study.

Protection of Confidentiality

The research team is committed to protecting your confidentiality at all times and in all circumstances. Your response to the study evaluation and surveys will not be made public. Any study survey data will be de-identified and/or reported in aggregate form for analyses. No identifying information will be used in the publication of the findings.

All electronic study data will be stored in an institutional database indefinitely. Participants who choose to fill out a paper copy of the survey(s) will have their responses stored in a locked file cabinet within the research team's locked office.

Your personally identifying information will be stored in a password-protected database, and your information and responses will be labeled with a study-specific participant identification number (participant ID) that will de-identify you from your responses before the analyses. Only certain members of the study staff will have the key to link your study ID to your personal information. Your personal information (name, date of survey, and email address) will be used to merge multiple rounds of survey responses and will not be shared with other survey participants.

Consent Statement

You have read the description of the study and have decided to participate in the research project described here. You understand that you may refuse to answer any (or all) of the questions at this or any other time. You understand that there is a possibility that you might be contacted in the future about this but that you are free to refuse any further participation if you wish.

You may withdraw your authorization at any time, in writing, for any reason as long as that information can be connected to you. You can learn more about how to withdraw your authorization by calling [redacted] or by contacting the study chair Dr. Kelly Nelson.

1) **By checking this box and proceeding to our Round 1 survey, I acknowledge the above statement and voluntarily consent to participate in the study.** ☐ I consent

Submit

Save & Return Later

Powered by REDCap

J Am Board Fam Med: first published as 10.3122/jabfm.2022.220143R1 on 9 February 2023. Downloaded from http://www.jabfm.org/ on 20 April 2024 by guest. Protected by copyright.

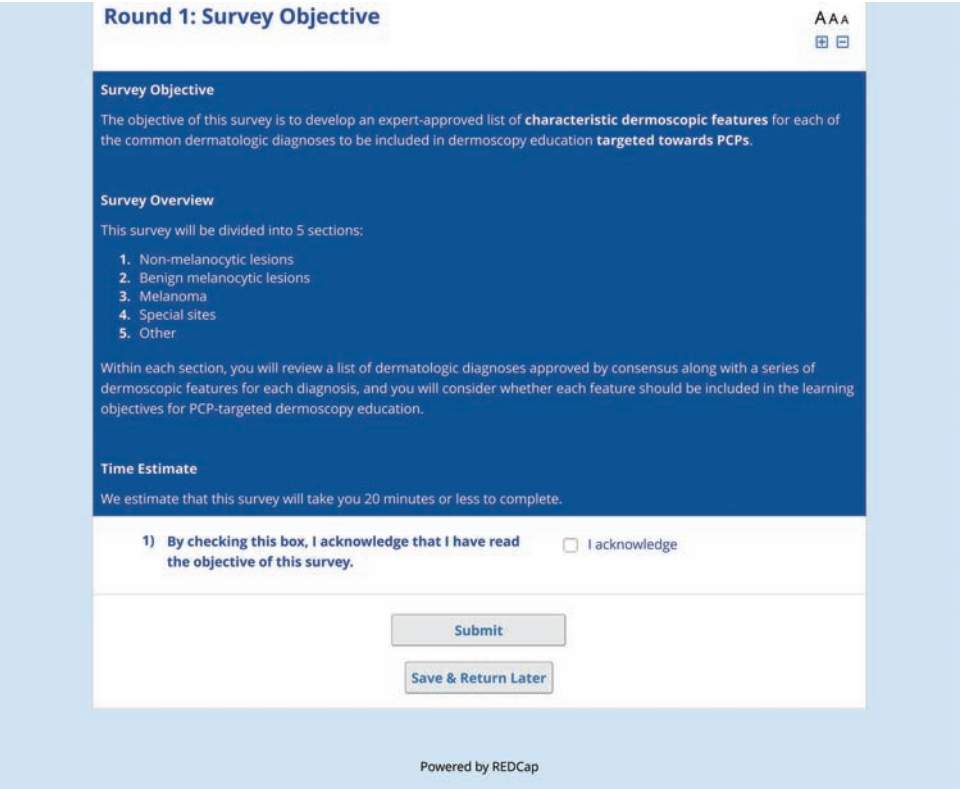

Round 1: Survey Objective

AAA

Survey Objective

The objective of this survey is to develop an expert-approved list of **characteristic dermoscopic features** for each of the common dermatologic diagnoses to be included in dermoscopy education **targeted towards PCPs**.

Survey Overview

This survey will be divided into 5 sections:

1. Non-melanocytic lesions
2. Benign melanocytic lesions
3. Melanoma
4. Special sites
5. Other

Within each section, you will review a list of dermatologic diagnoses approved by consensus along with a series of dermoscopic features for each diagnosis, and you will consider whether each feature should be included in the learning objectives for PCP-targeted dermoscopy education.

Time Estimate

We estimate that this survey will take you 20 minutes or less to complete.

1) **By checking this box, I acknowledge that I have read the objective of this survey.** ☐ I acknowledge

Submit

Save & Return Later

Powered by REDCap

J Am Board Fam Med: first published as 10.3122/jabfm.2022.220143R1 on 9 February 2023. Downloaded from http://www.jabfm.org/ on 20 April 2024 by guest. Protected by copyright.

Section 1: Nonmelanocytic Lesions

AAA

For each of the following dermatologic diagnoses, we would like to identify characteristic dermoscopic structures that should be included in dermoscopy education targeted towards PCPs. Please rate how strongly you would agree or disagree regarding the inclusion of each of the following features.

Level 1: Angioma

	Strongly disagree	Disagree	Neutral	Agree	Strongly agree
1) Red, blue-red, red-purple, or maroon lacunae/lagoons with white septae	○	○	○	○	○
2) Blue-black coloring (when thrombosed)	○	○	○	○	○

3) Please include any comments here: _____ Optional

Level 1: Dermatofibroma

	Strongly disagree	Disagree	Neutral	Agree	Strongly agree
4) Central scar-like white patch/depigmentation	○	○	○	○	○
5) Fine/delicate surrounding/peripheral network-like structures	○	○	○	○	○
6) Ring-like globules	○	○	○	○	○
7) Central shiny white lines/streaks	○	○	○	○	○
8) Dotted vessels	○	○	○	○	○
9) Central pink blush	○	○	○	○	○

10) Please include any comments here: _____ Optional

Level 1: Seborrheic Keratosis

	Strongly disagree	Disagree	Neutral	Agree	Strongly agree
11) Milia-like cysts, cloudy or starry	○	○	○	○	○
12) Comedo-like openings	○	○	○	○	○
13) Moth-eaten (sharply demarcated) borders	○	○	○	○	○
14) "Fissures and ridges" / "gyri and sulci" / cerebriform pattern	○	○	○	○	○
15) Fat fingers	○	○	○	○	○
16) Fingerprint-like structures/pattern (parallel lines)	○	○	○	○	○
17) Hairpin (looped) vessels, usually with whitish halo	○	○	○	○	○

18) Please include any comments here: _____ Optional

J Am Board Fam Med: first published as 10.3122/jabfm.2022.220143R1 on 9 February 2023. Downloaded from http://www.jabfm.org/ on 20 April 2024 by guest. Protected by copyright.

Level 1: Solar Lentigo

	Strongly disagree	Disagree	Neutral	Agree	Strongly agree
19) Moth-eaten (sharply demarcated) borders	○	○	○	○	○
20) Homogenous light brown pigmentation	○	○	○	○	○
21) Network-like structures	○	○	○	○	○
22) Fingerprint-like structures (parallel lines)	○	○	○	○	○
23) Uniform brown perifollicular pigmentation	○	○	○	○	○
~~24) Fingerprint-like structures/pattern (parallel lines)~~ *duplicate question*	○	○	○	○	○

25) Please include any comments here: _____ Optional

Level 1: Basal Cell Carcinoma (BCC)

	Strongly disagree	Disagree	Neutral	Agree	Strongly agree
26) Leaf-like structures/areas	○	○	○	○	○
27) Blue-gray ovoid nests	○	○	○	○	○
28) Multiple blue-gray dots and globules (buckshot scatter)	○	○	○	○	○
29) Spoke-wheel-like structures/areas / concentric structures	○	○	○	○	○
30) Ulceration / erosion	○	○	○	○	○
31) Shiny white blotches and strands / structures	○	○	○	○	○
32) Arborizing vessels	○	○	○	○	○
33) Short fine telangiectasias (superficial BCC)	○	○	○	○	○

34) Please include any comments here: _____ Optional

Level 1: Actinic Keratosis

	Strongly disagree	Disagree	Neutral	Agree	Strongly agree
35) Rosettes	○	○	○	○	○
36) Surface scale	○	○	○	○	○
37) Strawberry pattern (pink-red pseudonetwork +/- fine wavy vessels [straight or coiled] surrounding hair follicles +/- white circles with central yellow clod [targetoid hair follicles])	○	○	○	○	○

38) Please include any comments here: _____ Optional

J Am Board Fam Med: first published as 10.3122/jabfm.2022.220143R1 on 9 February 2023. Downloaded from http://www.jabfm.org/ on 20 April 2024 by guest. Protected by copyright.

Level 1: Squamous Cell Carcinoma

	Strongly disagree	Disagree	Neutral	Agree	Strongly agree
39) Yellow keratin mass / scale-crust	○	○	○	○	○
40) Ulceration / blood spots / hemorrhage	○	○	○	○	○
41) White circles ("keratin pearls")	○	○	○	○	○
42) Rosettes sign	○	○	○	○	○
43) Glomerular (coiled) vessels	○	○	○	○	○
44) Hairpin vessels, usually with whitish halo	○	○	○	○	○

45) Please include any comments here: [ ] Optional

Level 2: Sebaceous Hyperplasia

	Strongly disagree	Disagree	Neutral	Agree	Strongly agree
46) Pale yellow lobules (popcorn-like structures) around a central follicular opening	○	○	○	○	○
47) Crown vessels	○	○	○	○	○

48) Please include any comments here: [ ] Optional

Level 2: Ink Spot Lentigo (Reticulated Black Solar Lentigo)

	Strongly disagree	Disagree	Neutral	Agree	Strongly agree
49) Prominent dark reticular network	○	○	○	○	○
50) Chicken-wire fence	○	○	○	○	○

51) Please include any comments here: [ ] Optional

Level 2: Pigmented Actinic Keratosis

	Strongly disagree	Disagree	Neutral	Agree	Strongly agree
52) Gray dots	○	○	○	○	○
53) Annular-granular pattern (gray dots around follicular openings)	○	○	○	○	○
54) Rosette sign	○	○	○	○	○
55) Surface scale	○	○	○	○	○
56) Red pseudonetwork	○	○	○	○	○
57) White circles	○	○	○	○	○
58) Patent/evident follicles	○	○	○	○	○

59) Please include any comments here: [ ] Optional

J Am Board Fam Med: first published as 10.3122/jabfm.2022.220143R1 on 9 February 2023. Downloaded from http://www.jabfm.org/ on 20 April 2024 by guest. Protected by copyright.

Level 2: Squamous Cell Carcinoma in situ (Bowen's disease)

	Strongly disagree	Disagree	Neutral	Agree	Strongly agree
60) Surface scale	○	○	○	○	○
61) Peripheral brown/gray dots arranged linearly (pigmented SCCIS)	○	○	○	○	○
62) Glomerular (coiled) / dotted vessels	○	○	○	○	○

63) Please include any comments here: _____ Optional

Level 2: Keratoacanthoma

	Strongly disagree	Disagree	Neutral	Agree	Strongly agree
64) Central keratin mass	○	○	○	○	○
65) Hairpin (looped) or serpentine (linear-irregular) vessels, usually at the periphery, with white-yellow halo	○	○	○	○	○

66) Please include any comments here: _____ Optional

Level 2: Angiokeratoma

	Strongly disagree	Disagree	Neutral	Agree	Strongly agree
67) Red/purple/black ("dark") lacunae	○	○	○	○	○
68) Hemorrhagic crust	○	○	○	○	○

69) Please include any comments here: _____ Optional

Level 2: Lichen Planus-Like Keratosis (Benign Lichenoid Keratosis)

	Strongly disagree	Disagree	Neutral	Agree	Strongly agree
70) Coarse gray granularity	○	○	○	○	○
71) Peppering (evenly spaced gray dots)	○	○	○	○	○
72) Sharp cut-off borders (scalloped/moth-eaten)	○	○	○	○	○
73) Features of a lentigo or a seborrheic keratosis in an area	○	○	○	○	○

74) Please include any comments here: _____ Optional

Submit

Save & Return Later

Powered by REDCap

J Am Board Fam Med: first published as 10.3122/jabfm.2022.220143R1 on 9 February 2023. Downloaded from http://www.jabfm.org/ on 20 April 2024 by guest. Protected by copyright.

Section 2: Benign Melanocytic Lesions

AAA

For each of the following dermatologic diagnoses, we would like to identify characteristic dermoscopic structures that should be included in dermoscopy education targeted towards PCPs. Please rate how strongly you would agree or disagree regarding the inclusion of each of the following features.

Level 1: Overview of Benign Nevi Patterns

	Strongly disagree	Disagree	Neutral	Agree	Strongly agree
1) Diffuse reticular network	○	○	○	○	○
2) Patchy reticular network	○	○	○	○	○
3) Peripheral reticular network with central hypopigmentation	○	○	○	○	○
4) Peripheral reticular network with central hyperpigmentation	○	○	○	○	○
5) Peripheral reticular network with central globules	○	○	○	○	○
6) Homogenous (tan, brown, blue, or pink)	○	○	○	○	○
7) Central network with evenly distributed peripheral globules	○	○	○	○	○
8) Globular pattern	○	○	○	○	○
9) Two-component pattern	○	○	○	○	○
10) Symmetric multicomponent pattern	○	○	○	○	○

11) Please include any comments here: Optional

Level 1: Intradermal Nevi

	Strongly disagree	Disagree	Neutral	Agree	Strongly agree
12) Comma-shaped (curved) vessels	○	○	○	○	○
13) Homogenous (structureless) brown/tan/pink pigmentation	○	○	○	○	○
14) Peripheral network	○	○	○	○	○
15) Globules	○	○	○	○	○

16) Please include any comments here: Optional

Level 2: Congenital Melanocytic Nevi

	Strongly disagree	Disagree	Neutral	Agree	Strongly agree
17) Cobblestone pattern/globular pattern	○	○	○	○	○
18) Reticular network	○	○	○	○	○
19) Homogenous background pigmentation	○	○	○	○	○
20) Hypertrichosis	○	○	○	○	○
21) Perifollicular hyper-/hypo-pigmentation	○	○	○	○	○

22) Please include any comments here: Optional

J Am Board Fam Med: first published as 10.3122/jabfm.2022.220143R1 on 9 February 2023. Downloaded from http://www.jabfm.org/ on 20 April 2024 by guest. Protected by copyright.

Level 2: Blue Nevi

	Strongly disagree	Disagree	Neutral	Agree	Strongly agree
23) Homogenous blue/blue-gray pigmentation	○	○	○	○	○
24) Well-circumscribed	○	○	○	○	○

25) Please include any comments here: _____ Optional

Level 2: Spitz Nevi

	Strongly disagree	Disagree	Neutral	Agree	Strongly agree
26) Vascular pattern (pink homogenous with dotted vessels)	○	○	○	○	○
27) Starburst pattern (with tiered globules/streaks) (radial streaming)	○	○	○	○	○
28) Negative pigment network (reticular depigmentation)	○	○	○	○	○
29) Shiny white lines (crystalline structures)	○	○	○	○	○
30) Globular with negative network or blue-white veil	○	○	○	○	○

31) Please include any comments here: _____ Optional

Level 2: Recurrent Nevi (Persistent Nevi)

	Strongly disagree	Disagree	Neutral	Agree	Strongly agree
32) Pigment within the scar, not extending beyond	○	○	○	○	○

33) Please include any comments here: _____ Optional

Level 2: Halo Nevi

	Strongly disagree	Disagree	Neutral	Agree	Strongly agree
34) Encircling/surrounding depigmentation/pallor	○	○	○	○	○
35) Central reticulation with peripheral white depigmentation	○	○	○	○	○
36) Benign nevi patterns	○	○	○	○	○

37) Please include any comments here: _____ Optional

Submit

Save & Return Later

Powered by REDCap

J Am Board Fam Med: first published as 10.3122/jabfm.2022.220143R1 on 9 February 2023. Downloaded from http://www.jabfm.org/ on 20 April 2024 by guest. Protected by copyright.

Section 3: Melanoma

AAA

For each of the following dermatologic diagnoses, we would like to identify characteristic dermoscopic structures that should be included in dermoscopy education targeted towards PCPs. Please rate how strongly you would agree or disagree regarding the inclusion of each of the following features.

Level 1: Overview of Melanoma Patterns

	Strongly disagree	Disagree	Neutral	Agree	Strongly agree
1) Atypical pigment network	○	○	○	○	○
2) Blue structures (blue-white veil, blue-gray structures)	○	○	○	○	○
3) Shiny white lines/structures (crystalline structures)	○	○	○	○	○
4) Negative pigment network	○	○	○	○	○
5) Atypical/irregular dots/globules	○	○	○	○	○
6) Atypical/irregular streaks (radial streaming, pseudopods)	○	○	○	○	○
7) Regression structures (white scar-like area and/or peppering)	○	○	○	○	○
8) Peripheral brown/tan structureless area	○	○	○	○	○
9) Angulated lines (extrafacial) / polygons / zig-zag pattern	○	○	○	○	○
10) Atypical vascular pattern/structures, polymorphous vessels (2+ types of blood vessels)	○	○	○	○	○
11) Atypical blotch	○	○	○	○	○

12) Please include any comments here: Optional

Level 2: Acral Melanoma

	Strongly disagree	Disagree	Neutral	Agree	Strongly agree
13) Parallel ridge pattern	○	○	○	○	○
14) Irregular diffuse pigmentation	○	○	○	○	○
15) Multicomponent pattern	○	○	○	○	○
16) Atypical fibrillar pattern	○	○	○	○	○
17) Ulceration	○	○	○	○	○
18) Neo-vascularization	○	○	○	○	○

19) Please include any comments here: Optional

J Am Board Fam Med: first published as 10.3122/jabfm.2022.220143R1 on 9 February 2023. Downloaded from http://www.jabfm.org/ on 20 April 2024 by guest. Protected by copyright.

Level 2: Lentigo Maligna Melanoma (melanoma on chronically sun-damaged skin of the head/neck)

	Strongly disagree	Disagree	Neutral	Agree	Strongly agree
20) Annular-granular pattern (gray dots around follicular openings)	○	○	○	○	○
21) Asymmetric pigmentation around follicular openings / asymmetrical follicular openings	○	○	○	○	○
22) Rhomboidal structures (angulated lines) / zig-zag pattern	○	○	○	○	○
23) Circle within a circle (isobar)	○	○	○	○	○
24) Dark blotches +/- obliterated hair follicles	○	○	○	○	○

25) Please include any comments here: _____ Optional

Level 2: Amelanotic/Hypomelanotic Melanoma

	Strongly disagree	Disagree	Neutral	Agree	Strongly agree
26) Scar-like depigmentation	○	○	○	○	○
27) Milky red areas	○	○	○	○	○
28) Shiny white lines (crystalline structures)	○	○	○	○	○
29) Atypical vascular pattern, polymorphous vessels (2+ types of blood vessels)	○	○	○	○	○

30) Please include any comments here: _____ Optional

Submit

Save & Return Later

Powered by REDCap

J Am Board Fam Med: first published as 10.3122/jabfm.2022.220143R1 on 9 February 2023. Downloaded from http://www.jabfm.org/ on 20 April 2024 by guest. Protected by copyright.

Section 4: Special Sites

AAA

For each of the following dermatologic diagnoses, we would like to identify characteristic dermoscopic structures that should be included in dermoscopy education targeted towards PCPs. Please rate how strongly you would agree or disagree regarding the inclusion of each of the following features.

Level 1: Subungual Hemorrhage

	Strongly disagree	Disagree	Neutral	Agree	Strongly agree
1) Well-circumscribed red-black dots or blotches / blood spots	○	○	○	○	○
2) Distal streaks of red-brown coloration ("filamentous" distal end)	○	○	○	○	○
3) Homogenous red/purple/black coloration without melanin granules	○	○	○	○	○
4) Discontiguous with the cuticle	○	○	○	○	○

5) Please include any comments here: _____ Optional

Level 2: Dermoscopic Features of the Face

	Strongly disagree	Disagree	Neutral	Agree	Strongly agree
6) Pseudonetwork	○	○	○	○	○

7) Please include any comments here: _____ Optional

Level 2: Benign Patterns of Acral Nevi

	Strongly disagree	Disagree	Neutral	Agree	Strongly agree
8) Parallel furrow pattern (with pattern variations including single line, double line, single dotted line, double-dotted line)	○	○	○	○	○
9) Lattice-like pattern	○	○	○	○	○
10) Fibrillar pattern (soles only)	○	○	○	○	○
11) Homogenous pattern	○	○	○	○	○
12) Peas in a pod pattern (parallel furrow + globules on ridges) (congenital nevi)	○	○	○	○	○

13) Please include any comments here: _____ Optional

J Am Board Fam Med: first published as 10.3122/jabfm.2022.220143R1 on 9 February 2023. Downloaded from http://www.jabfm.org/ on 20 April 2024 by guest. Protected by copyright.

Level 2: Lentigo of the Nail (melanotic macule of the nail)

	Strongly disagree	Disagree	Neutral	Agree	Strongly agree
14) Multiple thin homogenous gray lines (or single gray band) +/- gray background	○	○	○	○	○

15) Please include any comments here: _____ Optional

Level 2: Melanoma of the Nail

	Strongly disagree	Disagree	Neutral	Agree	Strongly agree
16) Triangular shape of pigment band (band diameter wider at proximal end)	○	○	○	○	○
17) Pigmentation of periungual skin (micro-Hutchinson's sign)	○	○	○	○	○
18) Brown to black dots/globules associated with longitudinal lines	○	○	○	○	○
19) Longitudinal brown/black lines with irregular spacing, width, coloration, or parallelism	○	○	○	○	○
20) Band width >3 mm or 2/3 of nail plate width	○	○	○	○	○

21) Please include any comments here: _____ Optional

Level 2: Talon Noir

	Strongly disagree	Disagree	Neutral	Agree	Strongly agree
22) Homogenous or parallel-ridge red-brown coloration	○	○	○	○	○
23) Peripheral red-brown dots/globules	○	○	○	○	○
24) Cracks (lightning bolt sign)	○	○	○	○	○

25) Please include any comments here: _____ Optional

Submit

Save & Return Later

Powered by REDCap

J Am Board Fam Med: first published as 10.3122/jabfm.2022.220143R1 on 9 February 2023. Downloaded from http://www.jabfm.org/ on 20 April 2024 by guest. Protected by copyright.

Section 5: Other

AAA

For each of the following dermatologic diagnoses, we would like to identify characteristic dermoscopic structures that should be included in dermoscopy education targeted towards PCPs. Please rate how strongly you would agree or disagree regarding the inclusion of each of the following features.

Level 1: Scabies

	Strongly disagree	Disagree	Neutral	Agree	Strongly agree
1) Delta-wing jet with contrail sign (small dark brown triangular structure located at the end of whitish structureless curved/wavy lines)	○	○	○	○	○

2) Please include any comments here: _____ Optional

Level 1: Verruca (Warts)

	Strongly disagree	Disagree	Neutral	Agree	Strongly agree
3) Papilliform structures	○	○	○	○	○
4) Tiny red-black dots (papillary capillaries)	○	○	○	○	○

5) Please include any comments here: _____ Optional

Level 2: Molluscum Contagiosum

	Strongly disagree	Disagree	Neutral	Agree	Strongly agree
6) Central pore or umbilication	○	○	○	○	○
7) Polylobular white-yellow amorphous structures	○	○	○	○	○
8) Linear or branched vessels (red corona) / crown vessels	○	○	○	○	○

9) Please include any comments here: _____ Optional

J Am Board Fam Med: first published as 10.3122/jabfm.2022.220143R1 on 9 February 2023. Downloaded from http://www.jabfm.org/ on 20 April 2024 by guest. Protected by copyright.

Level 2: Venous Lake

	Strongly disagree	Disagree	Neutral	Agree	Strongly agree
10) Homogenous purple/blue/red coloration +/- globule/clods	○	○	○	○	○

11) Please include any comments here: _____ Optional

Level 2: Psoriasis

	Strongly disagree	Disagree	Neutral	Agree	Strongly agree
12) Red or pink color with white-yellow scales / light red background	○	○	○	○	○
13) Dotted vessels in a regular distribution	○	○	○	○	○
14) Twisted red loops in a homogenous distribution	○	○	○	○	○
15) Glomerular vessels	○	○	○	○	○

16) Please include any comments here: _____ Optional

Level 2: Radiation Tattoo

	Strongly disagree	Disagree	Neutral	Agree	Strongly agree
17) Homogenous blue or black coloration	○	○	○	○	○

18) Please include any comments here: _____ Optional

Level 2: Dermoscopic Features of Scars

	Strongly disagree	Disagree	Neutral	Agree	Strongly agree
19) Arborizing, linear irregular, or comma vessels in keloids	○	○	○	○	○
20) White depigmentation	○	○	○	○	○

21) Please include any comments here: _____ Optional

Submit

Powered by REDCap

J Am Board Fam Med: first published as 10.3122/jabfm.2022.220143R1 on 9 February 2023. Downloaded from http://www.jabfm.org/ on 20 April 2024 by guest. Protected by copyright.

Miscellaneous

AAA

The following diagnosis was inadvertently left off on prior surveys. Please rate how strongly you would agree or disagree with each of the following statements regarding this diagnosis. Given the diversity of interest, bandwidth, and engagement with dermoscopy across the PCP spectrum, we ask you to sort this diagnosis into three choices:

- **Level 1 (Foundational)** — PCPs who desire a basic yet practical understanding of dermoscopy and its applications for the detection of skin cancer should be able to recognize these diagnoses with appropriate training.
- **Level 2 (Intermediate)** — PCPs who are highly interested in dermoscopy and desire further training in dermoscopy beyond the Foundational Level should be able to recognize these diagnoses. With appropriate training, recognition of these "above and beyond" diagnoses would demonstrate an additional level of mastery beyond Level 1 (Foundational).
- **Not appropriate** — Dermoscopic identification of these diagnoses would not be reflective of either foundational- or intermediate-level proficiency for PCPs.

Please note that a "Neutral" vote will not contribute towards a consensus on the inclusion or exclusion of that specific diagnosis.

If this diagnosis is included, please also rate how strongly you agree or disagree with the inclusion of the following dermoscopic features.

Dermatologic Diagnosis: Nevus of the Nail

	Strongly disagree	Disagree	Neutral	Agree	Strongly agree
1) Nevus of the Nail should be included in Level 1 (Foundational)	○	○	○	○	○
2) Nevus of the Nail should be included in Level 2 (Intermediate)	○	○	○	○	○
3) Nevus of the Nail should NOT be included at either level	○	○	○	○	○

Dermoscopic Features: Nevus of the Nail

	Strongly disagree	Disagree	Neutral	Agree	Strongly agree
4) Homogenous brown background coloration	○	○	○	○	○
5) Uniform band thickness, color (including blue), and spacing with parallel band configuration	○	○	○	○	○

6) Please include any comments here: _____ Optional

Submit

Powered by REDCap

J Am Board Fam Med: first published as 10.3122/jabfm.2022.220143R1 on 9 February 2023. Downloaded from http://www.jabfm.org/ on 20 April 2024 by guest. Protected by copyright.

Dermoscopic Features: Round 2

Returning?

AAA

We appreciate your interest in participating in the PCP Dermoscopy Education Working Group.

About Us

We are a research team from The University of Texas MD Anderson Cancer Center, and we are conducting a research study supervised by Dr. Kelly Nelson.

Study Goal

The goal of this research study is the development and refinement of an expert consensus statement regarding key knowledge acquisition and self-efficacy learning aspects and assessment instruments for **Primary Care Provider (PCP)-targeted educational instruments seeking to improve skin cancer diagnosis**.

An initial consensus statement identifying key learning aspects was compiled using a systematic literature review and review of initial pilot instruments.

Study Details

If you agree to take part in this study, you will be asked to complete a series of electronic surveys listing potential learning aspects in which each participant will rate the appropriateness of inclusion for each objective. A modified Delphi process (a common iterative method used to obtain the consensus opinions of a group of authorities on a given topic) is being utilized for this effort. Feedback will be collected and assessed, and then a modified survey will be developed based on feedback and then re-administered to collect another round of feedback. This process will be repeated until consensus is reached.

You may complete the survey(s) either on paper or online using a web link sent by the study staff. Each survey should take up to 15 minutes to complete. The time between surveys will be about 1 month. Your total time or participation may be up to 3 months.

Study Participation

Your participation in this research is voluntary. If you choose not to take part, it will not affect your employment or traineeship at your institution in any way. If you do choose to take part in this research, your responses will also not affect your employment or trainee status.

There will be no compensation for your participation in this study.

Protection of Confidentiality

The research team is committed to protecting your confidentiality at all times and in all circumstances. Your response to the study evaluation and surveys will not be made public. Any study survey data will be de-identified and/or reported in aggregate form for analyses. No identifying information will be used in the publication of the findings.

All electronic study data will be stored in an institutional database indefinitely. Participants who choose to fill out a paper copy of the survey(s) will have their responses stored in a locked file cabinet within the research team's locked office.

Your personally identifying information will be stored in a password-protected database, and your information and responses will be labeled with a study-specific participant identification number (participant ID) that will de-identify you from your responses before the analyses. Only certain members of the study staff will have the key to link your study ID to your personal information. Your personal information (name, date of survey, and email address) will be used to merge multiple rounds of survey responses and will not be shared with other survey participants.

Consent Statement

You have read the description of the study and have decided to participate in the research project described here. You understand that you may refuse to answer any (or all) of the questions at this or any other time. You understand that there is a possibility that you might be contacted in the future about this but that you are free to refuse any further participation if you wish.

You may withdraw your authorization at any time, in writing, for any reason as long as that information can be connected to you. You can learn more about how to withdraw your authorization by calling [redacted] or by contacting the study chair Dr. Kelly Nelson.

1) **By checking this box and proceeding to our Round 2 survey, I acknowledge the above statement and voluntarily consent to participate in the study.** ☐ I consent

Submit

Save & Return Later

Powered by REDCap

J Am Board Fam Med: first published as 10.3122/jabfm.2022.220143R1 on 9 February 2023. Downloaded from http://www.jabfm.org/ on 20 April 2024 by guest. Protected by copyright.

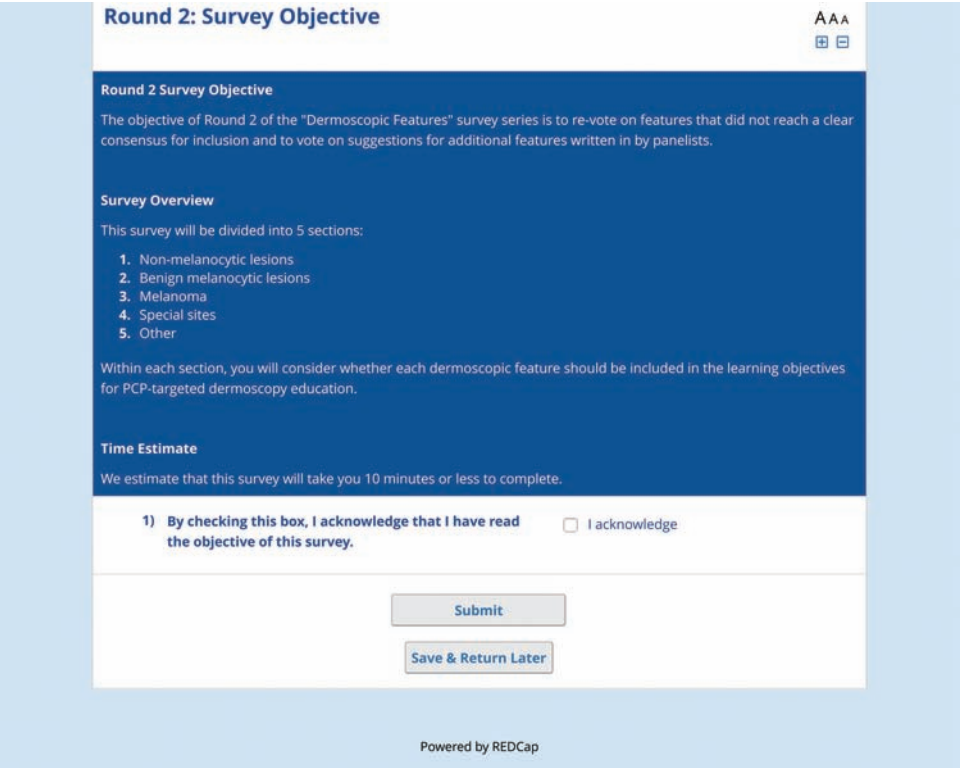

Round 2: Survey Objective

AAA

Round 2 Survey Objective

The objective of Round 2 of the "Dermoscopic Features" survey series is to re-vote on features that did not reach a clear consensus for inclusion and to vote on suggestions for additional features written in by panelists.

Survey Overview

This survey will be divided into 5 sections:

1. Non-melanocytic lesions
2. Benign melanocytic lesions
3. Melanoma
4. Special sites
5. Other

Within each section, you will consider whether each dermoscopic feature should be included in the learning objectives for PCP-targeted dermoscopy education.

Time Estimate

We estimate that this survey will take you 10 minutes or less to complete.

1) **By checking this box, I acknowledge that I have read the objective of this survey.** ☐ I acknowledge

Submit

Save & Return Later

Powered by REDCap

J Am Board Fam Med: first published as 10.3122/jabfm.2022.220143R1 on 9 February 2023. Downloaded from http://www.jabfm.org/ on 20 April 2024 by guest. Protected by copyright.

Section 1: Nonmelanocytic Lesions

AAA

For each of the following dermatologic diagnoses, we would like to identify characteristic dermoscopic structures that should be included in dermoscopy education targeted towards PCPs. Please rate how strongly you would agree or disagree regarding the inclusion of each of the following features.

Level 1: Angioma
Consensus:
- Red, blue-red, red-purple, or maroon lacunae/lagoons with white septae

Should the following feature(s) also be included in PCP-targeted dermoscopy education?

	Strongly disagree	Disagree	Neutral	Agree	Strongly agree
1) Blue-black coloring in lacunae (when thrombosed) in the absence of other structures	○	○	○	○	○

2) Please include any comments here: _____ Optional

Level 1: Dermatofibroma
Consensus:
- Central scar-like white patch/depigmentation
- Fine/delicate surrounding/peripheral network-like structures
- Central shiny white lines/streaks under polarized dermoscopy

Should the following feature(s) also be included in PCP-targeted dermoscopy education?

	Strongly disagree	Disagree	Neutral	Agree	Strongly agree
3) Ring-like globules	○	○	○	○	○

4) Please include any comments here: _____ Optional

Level 1: Solar Lentigo
Consensus:
- Moth-eaten (sharply demarcated) borders
- Homogenous light brown pigmentation
- Fingerprint-like structures (parallel lines)
- Uniform brown perifollicular pigmentation

Should the following feature(s) also be included in PCP-targeted dermoscopy education?

	Strongly disagree	Disagree	Neutral	Agree	Strongly agree
5) Network-like structures	○	○	○	○	○

6) Please include any comments here: _____ Optional

Level 1: Basal Cell Carcinoma (BCC)
Consensus:
- Leaf-like structures/areas
- Blue-gray ovoid nests

J Am Board Fam Med: first published as 10.3122/jabfm.2022.220143R1 on 9 February 2023. Downloaded from http://www.jabfm.org/ on 20 April 2024 by guest. Protected by copyright.

- Multiple blue-gray dots and globules (buckshot scatter)
- Spoke-wheel-like structures/areas / concentric structures
- Ulceration / erosion
- Arborizing vessels

Should the following feature(s) also be included in PCP-targeted dermoscopy education?

	Strongly disagree	Disagree	Neutral	Agree	Strongly agree
7) Shiny white blotches and strands / structures	○	○	○	○	○
8) Short fine telangiectasias (superficial BCC)	○	○	○	○	○

9) Please include any comments here: _____ Optional

Level 2: Ink Spot Lentigo (Reticulated Black Solar Lentigo)
Consensus:
- Prominent dark homogenous (uniform) reticular network

Should the following feature(s) also be included in PCP-targeted dermoscopy education?

	Strongly disagree	Disagree	Neutral	Agree	Strongly agree
10) Chicken-wire fence	○	○	○	○	○

11) Please include any comments here: _____ Optional

Level 2: Pigmented Actinic Keratosis
Consensus:
- Rosette sign
- Surface scale

Should the following feature(s) also be included in PCP-targeted dermoscopy education?

	Strongly disagree	Disagree	Neutral	Agree	Strongly agree
12) Gray dots	○	○	○	○	○
13) Annular-granular pattern (gray dots around follicular openings)	○	○	○	○	○

14) Please include any comments here: _____ Optional

Level 2: Squamous Cell Carcinoma in situ (Bowen's disease)
Consensus:
- Surface scale
- Irregularly arranged glomerular (coiled) / dotted vessels

Should the following feature(s) also be included in PCP-targeted dermoscopy education?

	Strongly disagree	Disagree	Neutral	Agree	Strongly agree
15) Peripheral brown/gray dots arranged linearly (pigmented SCCIS)	○	○	○	○	○

16) Please include any comments here: _____ Optional

J Am Board Fam Med: first published as 10.3122/jabfm.2022.220143R1 on 9 February 2023. Downloaded from http://www.jabfm.org/ on 20 April 2024 by guest. Protected by copyright.

Level 2: Lichen Planus-Like Keratosis (Benign Lichenoid Keratosis)
Consensus:
- Features of a lentigo or a seborrheic keratosis in an area

Should the following feature(s) also be included in PCP-targeted dermoscopy education?

	Strongly disagree	Disagree	Neutral	Agree	Strongly agree
17) Coarse gray granularity	○	○	○	○	○
18) Peppering (evenly spaced gray dots)	○	○	○	○	○
19) Sharp cut-off borders (scalloped/moth-eaten)	○	○	○	○	○
20) Blue-gray/blue-white structures (NEW)	○	○	○	○	○

21) Please include any comments here: [ ] Optional

Submit

Save & Return Later

Powered by REDCap

J Am Board Fam Med: first published as 10.3122/jabfm.2022.220143R1 on 9 February 2023. Downloaded from http://www.jabfm.org/ on 20 April 2024 by guest. Protected by copyright.

Section 2: Benign Melanocytic Lesions

For each of the following dermatologic diagnoses, we would like to identify characteristic dermoscopic structures that should be included in dermoscopy education targeted towards PCPs. Please rate how strongly you would agree or disagree regarding the inclusion of each of the following features.

Level 1: Overview of Benign Nevi Patterns
Consensus:
- Diffuse reticular network
- Patchy reticular network
- Peripheral reticular network with central hypopigmentation
- Peripheral reticular network with central hyperpigmentation
- Peripheral reticular network with central globules
- Homogenous (tan, brown, blue, or pink)
- Central network with evenly distributed peripheral globules
- Globular pattern
- Symmetric multicomponent pattern

Should the following feature(s) also be included in PCP-targeted dermoscopy education?

	Strongly disagree	Disagree	Neutral	Agree	Strongly agree
1) Two-component pattern	○	○	○	○	○
2) Please include any comments here:	Optional				

Level 2: Congenital Melanocytic Nevi
Consensus:
- Cobblestone pattern/globular pattern
- Reticular network
- Homogenous background pigmentation
- Hypertrichosis

Should the following feature(s) also be included in PCP-targeted dermoscopy education?

	Strongly disagree	Disagree	Neutral	Agree	Strongly agree
3) Perifollicular hyper-/hypo-pigmentation	○	○	○	○	○
4) Central hypopigmentation (NEW)	○	○	○	○	○
5) Please include any comments here:	Optional				

Level 2: Spitz Nevi
Consensus:
- Vascular pattern (pink homogenous with dotted vessels)
- Starburst pattern with tiered globules/streaks and regularly spaced pseudopods at the periphery (radial streaming)

Should the following feature(s) also be included in PCP-targeted dermoscopy education?

	Strongly disagree	Disagree	Neutral	Agree	Strongly agree
6) Negative pigment network (reticular depigmentation)	○	○	○	○	○
7) Shiny white lines (crystalline structures)	○	○	○	○	○
8) Globular with negative network or blue-white veil	○	○	○	○	○
9) Please include any comments here:	Optional				

Level 2: Recurrent Nevi (Persistent Nevi)
Consensus:
- Pigment within the scar, not extending beyond

Should the following feature(s) also be included in PCP-targeted dermoscopy education?

	Strongly disagree	Disagree	Neutral	Agree	Strongly agree
10) Starburst pattern (radial streaming) (NEW)	○	○	○	○	○
11) Please include any comments here:	Optional				

Submit

Save & Return Later

Powered by REDCap

J Am Board Fam Med: first published as 10.3122/jabfm.2022.220143R1 on 9 February 2023. Downloaded from http://www.jabfm.org/ on 20 April 2024 by guest. Protected by copyright.

Section 3: Melanoma

For each of the following dermatologic diagnoses, we would like to identify characteristic dermoscopic structures that should be included in dermoscopy education targeted towards PCPs. Please rate how strongly you would agree or disagree regarding the inclusion of each of the following features.

Level 1: Overview of Melanoma Patterns
Consensus:
- Atypical pigment network
- Blue structures (blue-white veil, blue-gray structures)
- Shiny white lines/structures (crystalline structures)
- Negative pigment network
- Atypical/irregular dots/globules
- Atypical/irregular streaks (radial streaming, pseudopods)
- Regression structures (white scar-like area and/or peppering)
- Peripheral brown/tan structureless area
- Angulated lines (extrafacial) / polygons / zig-zag pattern
- Atypical vascular pattern/structures, polymorphous vessels (2+ types of blood vessels)

Should the following feature(s) also be included in PCP-targeted dermoscopy education?

	Strongly disagree	Disagree	Neutral	Agree	Strongly agree
1) Atypical/off-center blotch	○	○	○	○	○

2) Please include any comments here: _____ Optional

Level 2: Acral Melanoma
Consensus:
- Parallel ridge pattern
- Irregular diffuse pigmentation or blotch
- Multicomponent pattern, asymmetry of structures/colors
- Atypical fibrillar pattern
- Ulceration
- Neo-vascularization, milky red

Should the following feature(s) also be included in PCP-targeted dermoscopy education?

	Strongly disagree	Disagree	Neutral	Agree	Strongly agree
3) Pigment crossing normal ridge pattern (NEW)	○	○	○	○	○

4) Please include any comments here: _____ Optional

Level 2: Lentigo Maligna Melanoma (melanoma on chronically sun-damaged skin of the head/neck)
Consensus:
- Annular-granular pattern (gray dots around follicular openings)
- Asymmetric pigmentation around follicular openings / asymmetrical follicular openings
- Rhomboidal structures (angulated lines) / zig-zag pattern
- Dark blotches +/- obliterated hair follicles

Should the following feature(s) also be included in PCP-targeted dermoscopy education?

	Strongly disagree	Disagree	Neutral	Agree	Strongly agree
5) Circle within a circle (isobar)	○	○	○	○	○

6) Please include any comments here: _____ Optional

Submit

Save & Return Later

Powered by REDCap

J Am Board Fam Med: first published as 10.3122/jabfm.2022.220143R1 on 9 February 2023. Downloaded from http://www.jabfm.org/ on 20 April 2024 by guest. Protected by copyright.

Section 4: Special Sites

AAA

For each of the following dermatologic diagnoses, we would like to identify characteristic dermoscopic structures that should be included in dermoscopy education targeted towards PCPs. Please rate how strongly you would agree or disagree regarding the inclusion of each of the following features.

Level 1: Subungual Hemorrhage
Consensus:
- Well-circumscribed red-black dots or blotches / blood spots
- Distal streaks of red-brown coloration ("filamentous" distal end)
- Discontiguous with the cuticle (not connected to the proximal nailfold or edge of nail)

Should the following feature(s) also be included in PCP-targeted dermoscopy education?

	Strongly disagree	Disagree	Neutral	Agree	Strongly agree
1) Homogenous red/purple/black coloration without melanin granules	○	○	○	○	○
2) Lightning sign or white streaks (NEW)	○	○	○	○	○

3) Please include any comments here: [ ] Optional

Level 2: Benign Patterns of Acral Nevi
Consensus:
- Parallel furrow pattern (with pattern variations including single line, double line, single dotted line, double-dotted line)
- Lattice-like pattern
- Fibrillar pattern (soles only
- Homogenous pattern

Should the following feature(s) also be included in PCP-targeted dermoscopy education?

	Strongly disagree	Disagree	Neutral	Agree	Strongly agree
4) Peas in a pod pattern (parallel furrow + globules on ridges) (congenital nevi)	○	○	○	○	○

5) Please include any comments here: [ ] Optional

Level 2: Lentigo of the Nail (melanotic macule of the nail)
Consensus:
- Homogenous gray band or lines +/- gray background

Should the following feature(s) also be included in PCP-targeted dermoscopy education?

	Strongly disagree	Disagree	Neutral	Agree	Strongly agree
6) Regular brown lines (NEW)	○	○	○	○	○

7) Please include any comments here: [ ] Optional

J Am Board Fam Med: first published as 10.3122/jabfm.2022.220143R1 on 9 February 2023. Downloaded from http://www.jabfm.org/ on 20 April 2024 by guest. Protected by copyright.

Level 2: Melanoma of the Nail
Consensus:
- Triangular shape of pigment band (band diameter wider at proximal end)
- Pigmentation of periungual skin (micro-Hutchinson's sign)
- Longitudinal brown/black broken lines with irregular spacing, width, coloration, or parallelism
- Band width >3 mm or 2/3 of nail plate width

Should the following feature(s) also be included in PCP-targeted dermoscopy education?

	Strongly disagree	Disagree	Neutral	Agree	Strongly agree
8) Brown to black dots/globules associated with longitudinal lines	○	○	○	○	○

9) Please include any comments here: _____ Optional

Level 2: Talon Noir
Consensus:
- Homogenous red-brown coloration

Should the following feature(s) also be included in PCP-targeted dermoscopy education?

	Strongly disagree	Disagree	Neutral	Agree	Strongly agree
10) Peripheral red-brown dots/globules	○	○	○	○	○

11) Please include any comments here: _____ Optional

Submit

Save & Return Later

Powered by REDCap

J Am Board Fam Med: first published as 10.3122/jabfm.2022.220143R1 on 9 February 2023. Downloaded from http://www.jabfm.org/ on 20 April 2024 by guest. Protected by copyright.

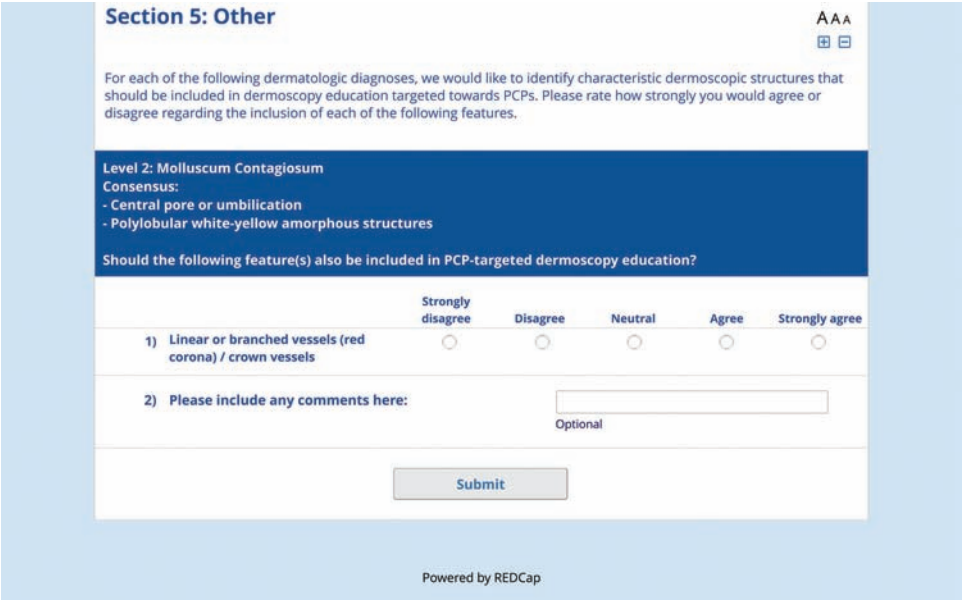

Section 5: Other

For each of the following dermatologic diagnoses, we would like to identify characteristic dermoscopic structures that should be included in dermoscopy education targeted towards PCPs. Please rate how strongly you would agree or disagree regarding the inclusion of each of the following features.

Level 2: Molluscum Contagiosum
Consensus:
- Central pore or umbilication
- Polylobular white-yellow amorphous structures

Should the following feature(s) also be included in PCP-targeted dermoscopy education?

	Strongly disagree	Disagree	Neutral	Agree	Strongly agree
1) Linear or branched vessels (red corona) / crown vessels	○	○	○	○	○

2) Please include any comments here: _____ Optional

Submit

Powered by REDCap

J Am Board Fam Med: first published as 10.3122/jabfm.2022.220143R1 on 9 February 2023. Downloaded from http://www.jabfm.org/ on 20 April 2024 by guest. Protected by copyright.

Demographics Survey

We sincerely appreciate your input.

In this initial survey, we will collect demographic data about panelists' expertise and degree of involvement in dermoscopy education to PCPs.	
What is your practice specialty?	☐ Family Medicine ☐ Internal Medicine ☐ Medicine-Pediatrics ☐ Dermatology ☐ Other
If you answered "Other" above, please describe:	_____
Do you use dermoscopy in your practice?	○ Yes ○ No
How long have you used dermoscopy in your practice for?	○ < 1 year ○ 1-5 years ○ 6-10 years ○ 11-15 years ○ >15 years
Are you specialized in pigmented lesions, dermoscopy, or melanoma?	○ Yes ○ No
How long have you specialized in pigmented lesions and melanoma for (as an attending physician)?	○ < 1 year ○ 1-5 years ○ 6-10 years ○ 11-15 years ○ >15 years
Are you directly involved in dermoscopy training for PCPs?	○ Yes ○ No
Do you provide dermoscopy training for PCPs in the clinic and/or through the lecture format?	☐ In the clinic ☐ Lectures ☐ Other (Please check all that apply.)
If you answered "Other" above, please describe:	_____

J Am Board Fam Med: first published as 10.3122/jabfm.2022.220143R1 on 9 February 2023. Downloaded from http://www.jabfm.org/ on 20 April 2024 by guest. Protected by copyright.

Appendix C. Dictionary of dermoscopic features for included diagnoses with annotations and references

Sections

1. Nonmelanocytic Lesions — Page 2
2. Benign Melanocytic Lesions — Page 5
3. Melanoma — Page 7
4. Special Sites — Page 8
5. Other (including skin infections & infestations) — Page 9

J Am Board Fam Med: first published as 10.3122/jabfm.2022.220143R1 on 9 February 2023. Downloaded from http://www.jabfm.org/ on 20 April 2024 by guest. Protected by copyright.

Section 1: Nonmelanocytic Lesions

Diagnosis (Level)	**Dermoscopic Features**	**References**
Hemangioma (Level 1)	Red, blue-red, red-purple, or maroon lacunae/lagoons with white septae Blue-black coloring (when thrombosed)	Wolf IH. Dermoscopic diagnosis of vascular lesions. *Clin Dermatol*. 2002;20(3):273-275.
Seborrheic keratosis (Level 1)	Milia-like cysts (cloudy or starry) and comedo-like openings "Fissures and ridges" / "gyri and sulci" / cerebriform pattern Moth-eaten (sharply demarcated) borders Fat fingers Fingerprint-like structures (parallel lines) Hairpin (looped) vessels~~, usually with whitish halo~~	Braun RP, Rabinovitz HS, Krischer J, Kreusch J, Oliviero M, Naldi L, Kopf AW, Saurat JH. Dermoscopy of pigmented seborrheic keratosis: a morphological study. *Arch Dermatol*. 2002;138(12):1556-1560.
Dermatofibroma (Level 1)	Central scar-like white patch/depigmentation Fine/delicate surrounding/peripheral network-like structures Central shiny white lines/streaks *(optional to include)* Ring-like globules ~~Central pink blush~~ ~~Dotted vessels~~	Agero AL, Taliercio S, Dusza SW, Salaro C, Chu P, Marghoob AA. Conventional and polarized dermoscopy features of dermatofibroma. *Arch Dermatol*. 2006;142(11):1431-1437. Zaballos P, Puig S, Llambrich A, Malvehy J. Dermoscopy of dermatofibromas: a prospective morphological study of 412 cases. *Arch Dermatol*. 2008;144(1):75–83.
Solar lentigo (Level 1)	Moth-eaten (sharply demarcated) borders Fingerprint-like structures (parallel lines) Homogenous light brown pigmentation Uniform brown perifollicular pigmentation *(optional to include)* Network-like structures	Bollea-Garlatti LA, Galimberti GN, Galimberti RL. Lentigo maligna: keys to dermoscopic diagnosis. *Actas Dermo-Sifiliogr.* 2016;107(6):489-497.
Basal cell carcinoma (Level 1)	Arborizing vessels Ulceration / erosion Leaf-like structures/areas Blue-gray ovoid nests Spoke-wheel-like structures/areas / concentric structures Multiple blue-gray dots and globules (buckshot scatter) Shiny white blotches and strands / structures Short fine telangiectasias (superficial BCC)	Balagula Y, Braun RP, Rabinovitz HS, et al. The significance of crystalline/chrysalis structures in the diagnosis of melanocytic and nonmelanocytic lesions. *J Am Acad Dermatol*. 2012;67(2):194.e1-194.e1948.

Key: black, from the dermatology resident Delphi study; **purple**, from ISIC database; **green**, from *An Atlas of Dermoscopy*; **yellow**, from Dermoscopedia; **red**, from other literature; **blue**, feature or text added by steering committee; yellow highlight, feature or text added by panel; ~~strikethrough~~, text removed by panel or feature excluded by panel consensus

J Am Board Fam Med: first published as 10.3122/jabfm.2022.220143R1 on 9 February 2023. Downloaded from http://www.jabfm.org/ on 20 April 2024 by guest. Protected by copyright.

Diagnosis (Level)	**Dermoscopic Features**	**References**
Squamous cell carcinoma (Level 1)	Yellow keratin mass / scale-crust Ulceration / blood spots / hemorrhage White circles ("keratin pearls") Glomerular (coiled) vessels Rosettes ~~sign~~ Hairpin vessels~~, usually with whitish halo~~	
Actinic keratosis (Level 1)	Surface scale Rosettes ~~sign~~ Strawberry pattern (pink-red pseudonetwork +/- fine wavy vessels [straight or coiled] surrounding hair follicles +/- white circles with central yellow clod [targetoid hair follicles])	Zalaudek I, Giacomel J, Argenziano G, et al. Dermoscopy of facial nonpigmented actinic keratosis. *Br J Dermatol*. 2006;155(5):951-956.
Sebaceous hyperplasia (Level 2)	Pale yellow lobules (popcorn-like structures) around a central follicular opening Crown vessels, out of focus	
Pigmented actinic keratosis (Level 2)	Surface scale Rosettes ~~sign~~ *(optional to include)* Annular-granular pattern (gray dots around follicular openings) *(optional to include)* Red pseudonetwork *(optional to include)* Patent/evident follicles ~~Gray dots~~ White circles	Casari A, Chester J, Pellacani G. Actinic keratosis and non-invasive diagnostic techniques: an update. *Biomedicines*. 2018;6(1):8. Kelati A, Baybay H, Moscarella E, Argenziano G, Gallouj S, Mernissi FZ. Dermoscopy of pigmented actinic keratosis of the face: a study of 232 cases. *Actas Dermo-Sifiliogr*. 2017;108(9):844-851.
Squamous cell carcinoma *in situ* (Level 2)	Irregularly arranged glomerular (coiled) / dotted vessels Surface scale ~~Peripheral brown/gray dots arranged linearly (pigmented squamous cell carcinoma *in situ*)~~	
Keratoacanthoma (Level 2)	Central keratin mass Hairpin (looped) or serpentine (linear-irregular) vessels, usually at the periphery, with white-yellow halo	
Angiokeratoma (Level 2)	Red/purple/black ("dark") lacunae Hemorrhagic crust	Wolf IH. Dermoscopic diagnosis of vascular lesions. *Clin Dermatol*. 2002;20(3):273-275.

Key: black, from the dermatology resident Delphi study; **purple**, from ISIC database; **green**, from *An Atlas of Dermoscopy*; **yellow**, from Dermoscopedia; **red**, from other literature; **blue**, feature or text added by steering committee; yellow highlight, feature or text added by panel; ~~strikethrough~~, text removed by panel or feature excluded by panel consensus

J Am Board Fam Med: first published as 10.3122/jabfm.2022.220143R1 on 9 February 2023. Downloaded from http://www.jabfm.org/ on 20 April 2024 by guest. Protected by copyright.

Diagnosis (Level)	**Dermoscopic Features**	**References**
Lichen planus-like keratosis (Level 2)	Features of a lentigo or a seborrheic keratosis in an area	
	(optional to include) Peppering (evenly spaced gray dots)	
	(optional to include) Sharp cut-off borders (scalloped/moth-eaten)	
	(optional to include) Coarse gray granularity	
Ink spot lentigo* (Level 2)	Prominent dark homogenous (uniform) reticular network	
	(optional to include) Chicken-wire fence	

* Diagnosis suggested by a panelist during Round 1 of the Dermatologic Diagnoses survey series

Key: black, from the dermatology resident Delphi study; **purple**, from ISIC database; **green**, from *An Atlas of Dermoscopy*; **yellow**, from Dermoscopedia; **red**, from other literature; **blue**, feature or text added by steering committee; yellow highlight, feature or text added by panel; ~~strikethrough~~, text removed by panel or feature excluded by panel consensus

J Am Board Fam Med: first published as 10.3122/jabfm.2022.220143R1 on 9 February 2023. Downloaded from http://www.jabfm.org/ on 20 April 2024 by guest. Protected by copyright.

Section 2: Benign Melanocytic Lesions

Diagnosis (Level)	**Dermoscopic Features**	**References**
Overview of benign nevi patterns (Level 1)	Diffuse reticular network Peripheral reticular network with central hypopigmentation Peripheral reticular network with central hyperpigmentation Globular pattern Patchy reticular network Homogenous (tan, brown, blue, or pink) Peripheral reticular network with central globules Central network with evenly distributed peripheral globules Symmetric two-component pattern *(optional to include)* Symmetric multicomponent pattern	
Intradermal nevi (Level 1)	Comma-shaped (curved) vessels Homogenous (structureless) brown/tan/pink pigmentation Peripheral network Globules	
Blue nevi (Level 2)	Homogenous blue/blue-gray pigmentation Well-circumscribed lesion	
Spitz nevi (Level 2)	Starburst pattern with tiered globules/streaks and regularly spaced pseudopods at the periphery (radial streaming) Vascular pattern (pink homogenous with dotted vessels) ~~Negative pigment network (reticular depigmentation)~~ ~~Shiny white lines (crystalline structures)~~ ~~Globular with negative network or blue-white veil~~	Zalaudek I, Kittler H, Hofmann-Wellenhof R, et al. "White" network in Spitz nevi and early melanomas lacking significant pigmentation. *J Am Acad Dermatol*. 2013;69(1):56-60. Marchell R, Marghoob AA, Braun RP, Argenziano G. Dermoscopy of Pigmented Spitz and Reed Nevi: The Starburst Pattern. Arch Dermatol. 2005;141(8):1060.
Congenital melanocytic nevi (Level 2)	Cobblestone pattern/globular pattern Reticular network Homogenous/~~diffuse~~ background pigmentation Hypertrichosis *(optional to include)* Perifollicular hyper-/hypo-pigmentation	

Key: black, from the dermatology resident Delphi study; **purple**, from ISIC database; **green**, from *An Atlas of Dermoscopy*; **yellow**, from Dermoscopedia; **red**, from other literature; **blue**, feature or text added by steering committee; yellow highlight, feature or text added by panel; ~~strikethrough~~, text removed by panel or feature excluded by panel consensus

J Am Board Fam Med: first published as 10.3122/jabfm.2022.220143R1 on 9 February 2023. Downloaded from http://www.jabfm.org/ on 20 April 2024 by guest. Protected by copyright.

Diagnosis (Level)	**Dermoscopic Features**	**References**
Recurrent/persistent nevi (Level 2)	Pigment within the scar, not extending beyond	
Halo nevi* (Level 2)	Encircling/surrounding depigmentation/pallor Central reticulation with peripheral white depigmentation Benign nevi patterns, globular, homogenous	Kolm I, Di Stefani A, Hofmann-Wellenhof R, et al. Dermoscopy patterns of halo nevi. Arch Dermatol. 2006;142(12):1627-1632.

* Diagnosis suggested by a panelist during Round 1 of the Dermatologic Diagnoses survey series

Key: black, from the dermatology resident Delphi study; **purple**, from ISIC database; **green**, from *An Atlas of Dermoscopy*; **yellow**, from Dermoscopedia; **red**, from other literature; **blue**, feature or text added by steering committee; yellow highlight, feature or text added by panel; ~~strikethrough~~, text removed by panel or feature excluded by panel consensus

J Am Board Fam Med: first published as 10.3122/jabfm.2022.220143R1 on 9 February 2023. Downloaded from http://www.jabfm.org/ on 20 April 2024 by guest. Protected by copyright.

Section 3: Melanoma

Diagnosis (Level)	**Dermoscopic Features**	**References**
Overview of melanoma patterns (Level 1)	Blue structures (blue-white veil, blue-gray structures) Shiny white lines/structures (crystalline structures) Atypical pigment network Atypical/irregular streaks (radial streaming, pseudopods) Atypical/irregular dots/globules Regression structures (white scar-like area and/or peppering) Negative pigment network Atypical vascular pattern/structures, polymorphous vessels (2+ types of blood vessels) Peripheral brown/tan structureless area Angulated lines (extrafacial) / polygons / zig-zag pattern Atypical off-center blotch(es)	Balagula Y, Braun RP, Rabinovitz HS, et al. The significance of crystalline/chrysalis structures in the diagnosis of melanocytic and nonmelanocytic lesions. J Am Acad Dermatol. 2012;67(2):194.e1-194.e1948. Marghoob NG, Liopyris K, Jaimes N. Dermoscopy: A Review of the Structures That Facilitate Melanoma Detection. *J Am Osteopath Assoc*. 2019;119(6):380-390.
Acral melanoma (Level 2)	Parallel ridge pattern Ulceration Irregular diffuse pigmentation or blotch Multicomponent pattern, asymmetry of structures/colors Atypical fibrillar pattern Neo-vascularization, milky red	Popa A, Dumitraş cu MC, Sandru F. Acral Melanoma mimicking a non-healing arterial ulcer. *Medical Image Database*. 2022;4(1):11-12.
Lentigo maligna melanoma (Level 2)	Annular-granular pattern (gray dots around follicular openings) Asymmetric pigmentation around follicular openings / asymmetrical follicular openings Rhomboidal structures (angulated lines) / zig-zag pattern Dark blotches +/- obliterated hair follicles *(optional to include)* Circle within a circle (isobar)	Schiffner R, Schiffner-Rohe J, Vogt T, et al. Improvement of early recognition of lentigo maligna using dermatoscopy. *J Am Acad Dermatol*. 2000;42(1 Pt 1):25-32. Slutsky JB, Marghoob AA. The Zig-Zag Pattern of Lentigo Maligna. *Arch Dermatol*. 2010;146(12):1444.
Melanoma of the nail (Level 2)	Pigmentation of periungual skin (micro-Hutchinson's sign) Triangular shape of pigment band (band diameter wider at proximal end) Longitudinal brown/black lines with irregular spacing, width, coloration, or parallelism Band width >3 mm or $^{2}/_{3}$ of nail plate width *(optional to include)* Brown to black dots/globules associated with longitudinal lines	

Key: black, from the dermatology resident Delphi study; **purple**, from ISIC database; **green**, from *An Atlas of Dermoscopy*; **yellow**, from Dermoscopedia; **red**, from other literature; **blue**, feature or text added by steering committee; yellow highlight, feature or text added by panel; ~~strikethrough~~, text removed by panel or feature excluded by panel consensus

J Am Board Fam Med: first published as 10.3122/jabfm.2022.220143R1 on 9 February 2023. Downloaded from http://www.jabfm.org/ on 20 April 2024 by guest. Protected by copyright.

Amelanotic/hypomelanotic melanoma (Level 2)	Milky red areas Shiny white lines (crystalline structures) Atypical vascular pattern, polymorphous vessels (2+ types of blood vessels) Scar-like depigmentation	Balagula Y, Braun RP, Rabinovitz HS, et al. The significance of crystalline/chrysalis structures in the diagnosis of melanocytic and nonmelanocytic lesions. J Am Acad Dermatol. 2012;67(2):194.e1-194.e1948.

Key: black, from the dermatology resident Delphi study; **purple**, from ISIC database; **green**, from *An Atlas of Dermoscopy*; **yellow**, from Dermoscopedia; **red**, from other literature; **blue**, feature or text added by steering committee; yellow highlight, feature or text added by panel; ~~strikethrough~~, text removed by panel or feature excluded by panel consensus

J Am Board Fam Med: first published as 10.3122/jabfm.2022.220143R1 on 9 February 2023. Downloaded from http://www.jabfm.org/ on 20 April 2024 by guest. Protected by copyright.

Section 4: Special Sites

Diagnosis (Level)	**Dermoscopic Features**	**References**
Subungual hemorrhage (Level 1)	Well-circumscribed red-black dots or blotches / blood spots Discontiguous with the cuticle (not connected to the proximal nailfold or edge of nail) Distal streaks of red-brown coloration ("filamentous" distal end) *(optional to include)* Homogenous red/purple/black coloration without melanin granules	
Dermoscopic features of the face (Level 2)	Pseudonetwork	
Benign patterns of acral nevi (Level 2)	Parallel furrow pattern (with pattern variations including single line, double line, single dotted line, double-dotted line) Lattice-like pattern Fibrillar pattern (soles only) Homogenous pattern *(optional to include)* Peas in a pod pattern (parallel furrow + globules on ridges) (acral congenital melanocytic nevi)	
Nevus of the nail (Level 2)	Homogenous brown background coloration Uniform band thickness, color (including blue), and spacing with parallel band configuration	
Lentigo of the nail (Level 2)	~~Multiple thin~~ homogenous gray lines (or ~~single gray~~ band) +/- gray background *(optional to include)* Regular light brown lines	
Talon noir* (Level 2)	Homogenous ~~or parallel-ridge~~ red-brown coloration *(optional to include)* Cracks (lightning bolt sign) ~~Peripheral red-brown dots/globules~~	Zalaudek I, Argenziano G, Soyer HP, Saurat JH, Braun RP. Dermoscopy of subcorneal hematoma. *Dermatol Surg*. 2004;30(9):1229-1232.

* Diagnosis suggested by a panelist during Round 1 of the Dermatologic Diagnoses survey series

Key: black, from the dermatology resident Delphi study; **purple**, from ISIC database; **green**, from *An Atlas of Dermoscopy*; **yellow**, from Dermoscopedia; **red**, from other literature; **blue**, feature or text added by steering committee; yellow highlight, feature or text added by panel; ~~strikethrough~~, text removed by panel or feature excluded by panel consensus

J Am Board Fam Med: first published as 10.3122/jabfm.2022.220143R1 on 9 February 2023. Downloaded from http://www.jabfm.org/ on 20 April 2024 by guest. Protected by copyright.

Section 5: Other (including skin infections & infestations)

Diagnosis (Level)	**Dermoscopic Features**	**References**
Verruca (Level 1)	Papilliform structures Tiny red-black dots (papillary capillaries)	Al Rudaisat M, Cheng H. Dermoscopy features of cutaneous warts. *Int J Gen Med*. 2021;14:9903-9912.
Scabies (Level 1)	Delta-wing jet with contrail sign (small dark brown triangular structure located at the end of whitish structureless curved/wavy lines)	Park JH, Kim CW, Kim SS. The diagnostic accuracy of dermoscopy for scabies. *Ann Dermatol*. 2012;24(2):194-199. doi:10.5021/ad.2012.24.2.194
Molluscum contagiosum (Level 2)	Central pore or umbilication Polylobular white-yellow amorphous structures *(optional to include)* Linear or branched vessels (red corona) / crown vessels	Ianhez M, Cestari Sda C, Enokihara MY, Seize MB. Dermoscopic patterns of molluscum contagiosum: a study of 211 lesions confirmed by histopathology. *An Bras Dermatol*. 2011;86(1):74-79.
Radiation tattoo (Level 2)	Homogenous blue or black coloration	Nazarian RS, Amin B, Papalezova K, Ohri N, McLellan BN. Radiation tattoos mimicking melanoma: a clinical observation. *Acta Oncologica*. 2019;58(9):1283-1285.
Scars (Level 2)	White depigmentation ~~Arborizing, linear irregular, or comma vessels in keloids~~	Yoo MG, Kim IH. Keloids and hypertrophic scars: characteristic vascular structures visualized by using dermoscopy. *Ann Dermatol*. 2014;26(5):603-609.
Venous lake (Level 2)	Homogenous purple/blue/red coloration +/- globule/clods	Lee JS, Mun JH. Dermoscopy of venous lake on the lips: A comparative study with labial melanotic macule. *PLoS One*. 2018;13(10):e0206768.
Psoriasis* (Level 2)	Red or pink color with white-yellow scales / light red background Dotted vessels in a regular distribution ~~Twisted red loops in a homogenous distribution~~ ~~Glomerular vessels~~	Golińska J, Sar-Pomian M, Rudnicka. Dermoscopic features of psoriasis of the skin, scalp and nails – a systematic review. *J Eur Acad Dermatol Venereol*. 2019;33(4):648-660.

* Diagnosis suggested by a panelist during Round 1 of the Dermatologic Diagnoses survey series

Key: black, from the dermatology resident Delphi study; **purple**, from ISIC database; **green**, from *An Atlas of Dermoscopy*; **yellow**, from Dermoscopedia; **red**, from other literature; **blue**, feature or text added by steering committee; yellow highlight, feature or text added by panel; ~~strikethrough~~, text removed by panel or feature excluded by panel consensus

J Am Board Fam Med: first published as 10.3122/jabfm.2022.220143R1 on 9 February 2023. Downloaded from http://www.jabfm.org/ on 20 April 2024 by guest. Protected by copyright.

Additional References

Braun RP LA, Marghoob AA, et al, eds. Dermoscopedia. International Dermoscopy Society. Accessed December 2021. https://dermoscopedia.org/Main_Page

Fried LJ, Tan A, Berry EG, et al. Dermoscopy proficiency expectations for US dermatology resident physicians: results of a modified Delphi survey of pigmented lesion experts. *JAMA Dermatol*. 2021;157(2):189-197.

Kittler H, Marghoob AA, Argenziano G, Carrera C, Curiel-Lewandrowski C, Hofmann-Wellenhof R, et al. Standardization of terminology in dermoscopy/dermatoscopy: Results of the third consensus conference of the International Society of Dermoscopy. *J Am Acad Dermatol*. 2016;74(6):1093–106.

Marghoob AA, Malvehy J, Braun RP, eds. *An Atlas of Dermoscopy*. 2nd ed. CRC Press. 2012.

J Am Board Fam Med: first published as 10.3122/jabfm.2022.220143R1 on 9 February 2023. Downloaded from http://www.jabfm.org/ on 20 April 2024 by guest. Protected by copyright.

Appendix D. Results summaries for the diagnoses survey series (3 rounds) and features survey series (2 rounds)

Dermatologic Diagnoses Survey Series

Round 1	Page 2
Round 2	Page 14
Round 3	Page 24

Dermoscopic Features Survey Series

Round 1	Page 29
Round 2	Page 42

J Am Board Fam Med: first published as 10.3122/jabfm.2022.220143R1 on 9 February 2023. Downloaded from http://www.jabfm.org/ on 20 April 2024 by guest. Protected by copyright.

Development of an Expert Consensus on Core Dermoscopy Proficiencies for PCPs Who Use Dermoscopy

Dermatologic Diagnoses: Round 1

Preliminary Results

October 20, 2021

J Am Board Fam Med: first published as 10.3122/jabfm.2022.220143R1 on 9 February 2023. Downloaded from http://www.jabfm.org/ on 20 April 2024 by guest. Protected by copyright.

I. Study Objective

The objective of this study is to develop and refine an expert consensus statement regarding key learning objectives deemed appropriate for dermoscopy educational interventions targeted towards primary care providers (PCPs). These interventions seek to support early skin cancer detection and accurate skin cancer diagnosis by PCPs.

By reaching a consensus on the dermoscopic diagnoses and features that PCPs who use dermoscopy should know, we can develop effective educational interventions that meet the needs of practicing physicians and advanced practice providers.

II. Survey Overview

The objective of this initial diagnoses survey series is to develop an expert-approved list of common dermatologic diagnoses with characteristic dermoscopic features that should be included in dermoscopy training programs for PCPs.

In Round 1, panelists reviewed a list of diagnoses and considered whether each specific diagnosis should be included in the learning objectives for PCP-targeted dermoscopy education. The list of diagnoses in Round 1 was largely derived from a consensus-based list of dermoscopic diagnoses considered reflective of an appropriate foundational proficiency for dermatology residents.[1]

Given the diversity of interest in and engagement with dermoscopy across the PCP spectrum, panelists were also instructed to sort each diagnosis into three choices:

- **Level 1** (Foundational) — PCPs who desire a basic yet practical understanding of dermoscopy and its applications for the detection of skin cancer should be able to recognize these diagnoses with sufficient training.
- **Level 2** (Intermediate) — PCPs who are highly interested in dermoscopy and desire further training in dermoscopy beyond Level 1 should be able to recognize these diagnoses. With sufficient training, recognition of these "above and beyond" diagnoses would demonstrate an additional level of mastery beyond Level 1.
- **Not appropriate** — Dermoscopic identification of these diagnoses would not be reflective of either foundational- or intermediate-level proficiency for PCPs.

III. Survey Methods

This study protocol follows the two-phase modified Delphi method. In the first phase, a steering committee develops a statement (i.e., list of dermoscopic diagnoses) to present to the panel, and in the second phase, an expert panel refines this statement through sequential rounds of voting. In each round, panelists may propose changes to the statement, which are then presented to and voted on by the panel in a subsequent round.

J Am Board Fam Med: first published as 10.3122/jabfm.2022.220143R1 on 9 February 2023. Downloaded from http://www.jabfm.org/ on 20 April 2024 by guest. Protected by copyright.

By using a web-based platform, panelists' responses, suggestions, and comments remain anonymous. This process is intended to ensure that the outcomes most closely represent the collective viewpoints of the panelists.

For the diagnoses survey series, a steering committee (comprised of 3 PCPs who use dermoscopy and 2 dermatologists who are highly engaged in dermoscopy education for PCPs) approved a list of diagnoses and provided input on the design of the survey instrument, which was subsequently developed on REDCap. In recruiting panelists for the second phase, the steering committee drafted a list of potential candidates consisting of PCPs known to use dermoscopy and dermatologists known to be directly involved in dermoscopy education for PCPs.

On October 1, 2021, the Round 1 survey was distributed via e-mail to panel invitees. The survey instrument included a consent statement and a list of diagnoses divided into 5 sections:

1. Non-melanocytic lesions
2. Benign melanocytic lesions
3. Melanoma
4. Special sites
5. Other (including skin infections & infestations)

For each specific diagnosis, panelists considered the following questions:

- Should the diagnosis be included in a **Level 1** (Foundational) proficiency standard for PCPs?
- Should the diagnosis be included in a **Level 2** (Intermediate) proficiency standard for PCPs?
- Should the diagnosis not be included at either Level 1 or Level 2?

Panelists also had the opportunity to write in suggestions for additional diagnoses that will be voted on by the panel in Round 2 per the modified Delphi method.

Of the 40 colleagues invited to join the panel, 35 (85.7%) voluntarily consented to participate and completed the survey instrument. In this initial round, panelists also completed a demographics survey that asked about their area of expertise, use of dermoscopy, and experience with dermoscopy training for PCPs.

The collection of completed surveys ended on October 19, 2021. Responses were de-identified, and data analyses were performed using REDCap and Excel. Incomplete survey responses were excluded from data analyses.

IV. Results Preview

The dermoscopic diagnoses that achieved consensus, or >70% agreement (defined as selection of "strongly agree" or "agree" on the Likert scale), are listed below. **Tables 1 and 2** includes the diagnoses that panelists agreed should be included in Levels 1 and 2, respectively. **Table 3** includes the diagnoses that panelists agreed should not be included in either Level 1 or Level 2.

J Am Board Fam Med: first published as 10.3122/jabfm.2022.220143R1 on 9 February 2023. Downloaded from http://www.jabfm.org/ on 20 April 2024 by guest. Protected by copyright.

Table 1. Dermoscopic diagnoses that >70% panelists agreed should be included in Level 1.

Nonmelanocytic lesions	Benign melanocytic lesions	Melanoma	Special sites	Other
• Basal cell carcinoma • Actinic keratosis • Squamous cell carcinoma • Simple lentigo • Solar lentigo • Seborrheic keratosis • Angioma • Dermatofibroma	• Overview of benign nevi patterns • Intradermal nevi	• Overview of melanoma patterns	• Subungual hemorrhage	• Verruca

Table 2. Dermoscopic diagnoses that >70% panelists agreed should be included in Level 2.

Nonmelanocytic lesions	Benign melanocytic lesions	Melanoma	Special sites	Other
• Pigmented actinic keratosis • Sebaceous hyperplasia	• Congenital melanocytic nevi • Blue nevi • Spitz nevi	• Acral melanoma • Lentigo maligna melanoma	• Dermoscopic features of the face • Benign patterns of acral nevi • Melanoma of the nail	(none)

Table 3. Dermoscopic diagnoses that >70% panelists agreed should not be included in either Level 1 or Level 2.

Nonmelanocytic lesions	Benign melanocytic lesions	Melanoma	Special sites	Other
(none)	(none)	(none)	(none)	(none)

J Am Board Fam Med: first published as 10.3122/jabfm.2022.220143R1 on 9 February 2023. Downloaded from http://www.jabfm.org/ on 20 April 2024 by guest. Protected by copyright.

V. Results

For Round 1, panelists were instructed to rate on a Likert scale whether they agree that a diagnosis should be included in Level 1 (Foundational), should be included in Level 2 (Intermediate), or should not be included at either level. For each survey item, the options for the Likert scale were:

1. Strongly disagree
2. Disagree
3. Neutral
4. Agree
5. Strongly agree

Panelists' responses on the Likert scale were converted to a numerical format with 1 representing "strongly disagree" and 5 representing "strongly agree," as above. The selection of strongly agree" (5) or "agree" (4) was considered a "positive response" and contributed towards a survey item reaching consensus.

Tables 4-8, corresponding to the 5 different sections, summarize the results of Round 1. Panelists' suggestions for additional diagnoses and comments are also included. Panelists will vote on these suggested diagnoses in Round 2.

Suggestions that were addressed in a subsequent section on the survey (e.g., "intradermal nevus," "verruca," etc.) were excluded from this report, and suggestions that were more applicable to a different section (e.g., "talon noir," "mucous membranes," etc.) were moved to the appropriate section.

For each diagnosis, the aggregate of panelists' responses resulted in one of the following designations for the "next step":

- "include in Level 1" as a learning objective
  - The diagnosis reached a clear consensus for inclusion in Level 1 with >70% of panelists voting "strongly agree" (5) or "agree" (4).
  - The diagnosis is deemed appropriate for PCPs who desire a basic yet practical understanding of dermoscopy.

- "exclude from Level 1" / "include in Level 2" as a learning objective
  - The diagnosis did not reach a clear consensus for inclusion in Level 1. However, the diagnosis reached a clear consensus for inclusion in Level 2.
  - The diagnosis is deemed appropriate for PCPs who are highly interested in dermoscopy and desire further training beyond Level 1.

- "exclude from Level 2" as a learning objective
  - The diagnosis is not deemed appropriate for either Level 1 or Level 2.

- "re-vote in round 2"
  - The diagnosis did not reach a clear consensus for a particular level with >50% of panelists voting "strongly agree" (5) or "agree" (4).

J Am Board Fam Med: first published as 10.3122/jabfm.2022.220143R1 on 9 February 2023. Downloaded from http://www.jabfm.org/ on 20 April 2024 by guest. Protected by copyright.

Table 4. Results for diagnoses representing nonmelanocytic lesions (n=35 panelists). Responses were converted to a numerical scale with a minimum of 1, representing "strongly disagree," and a maximum of 5, representing "strongly agree."

Diagnosis Level	**Round 1: response average**	**Round 1: % positive responses***	**Next step**	**Comments**
Basal cell carcinoma				
Level 1	4.77	94.3%	include in Level 1	(none)
Level 2	—	—		
Neither	—	—		
Actinic keratosis				
Level 1	3.97	71.4%	include in Level 1	(none)
Level 2	—	—		
Neither	—	—		
Pigmented actinic keratosis				
Level 1	2.69	25.7%	exclude from Level 1	(none)
Level 2	3.97	77.1%	include in Level 2	
Neither	—	—		
Squamous cell carcinoma in situ				
Level 1	3.97	65.7%	re-vote in Round 2	(none)
Level 2	3.80	68.6%	re-vote in Round 2	
Neither	1.34	0%		
Keratoacanthoma				
Level 1	3.49	51.4%	re-vote in Round 2	(none)
Level 2	3.74	65.7%	re-vote in Round 2	
Neither	1.49	0%		
Squamous cell carcinoma				
Level 1	4.23	74.3%	include in Level 1	(none)
Level 2	—	—		
Neither	—	—		
~~*Simple Lentigo*~~				
~~Level 1~~	~~4.17~~	~~80.0%~~		*diagnosis later removed by steering committee due to overlap with solar lentigo*
~~Level 2~~	—	—		
~~Neither~~	—	—		
Solar lentigo				
Level 1	4.26	85.7%	include in Level 1	(none)
Level 2	—	—		
Neither	—	—		
Seborrheic keratosis				
Level 1	4.94	100.0%	include in Level 1	(none)
Level 2	—	—		
Neither	—	—		
Lichen planus-like keratosis				
Level 1	2.40	14.3%	exclude from Level 1	"LPLK is a very tricky lesion that is even difficult for seasoned dermoscopists. It is often included discussions/ controversies at national dermoscopy meetings as the great masquerade lesion."
Level 2	3.63	57.1%	re-vote in Round 2	
Neither	1.97	17.1%		
Angioma				
Level 1	4.80	100.0%	include in Level 1	(none)
Level 2	—	—		
Neither	—	—		

J Am Board Fam Med: first published as 10.3122/jabfm.2022.220143R1 on 9 February 2023. Downloaded from http://www.jabfm.org/ on 20 April 2024 by guest. Protected by copyright.

Diagnosis Level	Round 1: response average	Round 1: % positive responses*	Next step	Comments
Angiokeratoma				
Level 1	3.11	37.1%	exclude from Level 1	(none)
Level 2	3.80	62.9%	re-vote in Round 2	
Neither	1.57	2.9%		
Dermatofibroma				
Level 1	4.71	94.3%	include in Level 1	(none)
Level 2	—	—		
Neither	—	—		
Clear cell acanthoma				
Level 1	2.17	11.4%	exclude from Level 1	(none)
Level 2	3.69	65.7%	re-vote in Round 2	
Neither	2.09	22.9%		
Sebaceous hyperplasia				
Level 1	3.66	54.3%	re-vote in Round 2	(none)
Level 2	4.03	77.1%	include in Level 2	
Neither	—	—	if not included in Level 1	

Suggestions
"Merkel cell carcinoma" → vote in Round 2
"porokeratosis" → vote in Round 2
"ink spot lentigo" → vote in Round 2

Additional Comments
"If a provider determines to use dermoscopy to aid in diagnosis, it should be essential that they can recognize common skin cancers and ailments."
"I feel that BCC, SCC, SK, etc., should be taught at a foundational level but can be taught in more detail in Level 1."
"Having much experience teaching medical students, residents, and practicing PCPs, I have found that triage of lesions for biopsy or not (instead of diagnosing the lesion) using the TADA (Triage Amalgamated Dermoscopy Algorithm where only dermatofibroma, angioma, and seborrheic keratosis are the only lesions truly diagnosed with TADA) to be vastly superior when teaching at the foundational level to PCP. Using TADA, I can rapidly (in an hour) teach learners to achieve demonstrable confidence and skill in lesion triage. Before TADA, my first attempts at teaching utilized modified pattern analysis to 'diagnose' lesions and skill and confidence acquisition with learners was very difficult in a short session. Thus, I think any dermoscopy curriculum should have the TADA algorithm as foundational work, and then select diagnoses at the intermediate level using modified pattern analysis."

* A positive response is defined as selection of "strongly agree" (5) or "agree" (4).

J Am Board Fam Med: first published as 10.3122/jabfm.2022.220143R1 on 9 February 2023. Downloaded from http://www.jabfm.org/ on 20 April 2024 by guest. Protected by copyright.

Table 5. Results for diagnoses representing benign melanocytic lesions (n=34-35 panelists). Responses were converted to a numerical scale with a minimum of 1, representing "strongly disagree," and a maximum of 5, representing "strongly agree."

Diagnosis Level	**Round 1: response average**	**Round 1: % positive responses***	**Next step**	**Comments**
Overview of benign nevi patterns (n=35)				
Level 1	4.43	91.4%	include in Level 1	(none)
Level 2	—	—		
Neither	—	—		
Congenital melanocytic nevi				
Level 1 (n=34)	3.34	45.7%	exclude from Level 1	(none)
Level 2 (n=35)	4.00	73.5%	include in Level 2	
Neither (n=34)	—	—		
Intradermal nevi (n=34)				
Level 1	3.94	70.6%	include in Level 1	(none)
Level 2	—	—		
Neither	—	—		
Blue nevi (n=34)				
Level 1	3.53	52.9%	re-vote in Round 2	(none)
Level 2	3.97	76.5%	include in Level 2	
Neither	—	—		
Spitz nevi (n=34)				
Level 1	2.44	17.6%	exclude from Level 1	(none)
Level 2	3.88	76.5%	include in Level 2	
Neither	—	—		
Recurrent/persistent nevi (n=34)				
Level 1	2.50	14.7%	exclude from Level 1	(none)
Level 2	3.82	64.7%	re-vote in Round 2	
Neither	2.00	2.9%		

Suggestions
"halo nevi" → vote in Round 2
"combined nevi" → vote in Round 2

Additional Comments
"I do not understand the category of persistent nevi."

* A positive response is defined as selection of "strongly agree" (5) or "agree" (4).

J Am Board Fam Med: first published as 10.3122/jabfm.2022.220143R1 on 9 February 2023. Downloaded from http://www.jabfm.org/ on 20 April 2024 by guest. Protected by copyright.

Table 6. Results for diagnoses representing melanoma (n=34-35 panelists). Responses were converted to a numerical scale with a minimum of 1, representing "strongly disagree," and a maximum of 5, representing "strongly agree."

Diagnosis Level	**Round 1: response average**	**Round 1: % positive responses***	**Next step**	**Comments**
Overview of melanoma patterns (n=35)				
Level 1	4.66	91.4%	include in Level 1	(none)
Level 2	—	—		
Neither	—	—		
Acral melanoma (n=35)				
Level 1	3.40	48.6%	exclude from Level 1	"I would be very hesitant to encourage someone who has a basic level of training in dermoscopy to manage and interpret acral lesions. They are difficult to interpret and high risk."
Level 2	3.94	80.0%	include in Level 2	
Neither	—	—		
Lentigo maligna melanoma (n=34)				
Level 1	3.26	45.7%	exclude from Level 1	(none)
Level 2	4.00	74.3%	include in Level 2	
Neither	—	—		
Amelanotic/hypomelanotic melanoma (n=34)				
Level 1	2.66	28.6%	exclude from Level 1	"Even for the most advanced physician that has a mastered dermoscopy, diagnosis of an amelanotic melanoma should always be confirmed with biopsy."
Level 2	3.71	65.7%	re-vote in Round 2	
Neither	1.97	8.6%		

Suggestions
"nevoid melanoma" → vote in Round 2
"desmoplastic melanoma" → vote in Round 2
"verrucous melanoma" → vote in Round 2

Additional Comments
(none)

* A positive response is defined as selection of "strongly agree" (5) or "agree" (4).

J Am Board Fam Med: first published as 10.3122/jabfm.2022.220143R1 on 9 February 2023. Downloaded from http://www.jabfm.org/ on 20 April 2024 by guest. Protected by copyright.

Table 7. Results for diagnoses related to special sites (n=35 panelists). Responses were converted to a numerical scale with a minimum of 1, representing "strongly disagree," and a maximum of 5, representing "strongly agree."

Diagnosis Level	**Round 1: response average**	**Round 1: % positive responses***	**Next step**	**Comments**
Dermoscopic features of the face				
Level 1	2.97	42.9%	exclude from Level 1	(none)
Level 2	3.91	77.1%	include in Level 2	
Neither	—	—		
Benign patterns of acral nevi				
Level 1	3.11	51.4%	re-vote in Round 2	(none)
Level 2	3.86	74.3%	include in Level 2	
Neither	—	—		
Lentigo of the nail				
Level 1	2.46	20.0%	exclude from Level 1	(none)
Level 2	3.71	62.9%	re-vote in Round 2	
Neither	2.11	8.6%		
Melanoma of the nail				
Level 1	2.89	31.4%	exclude from Level 1	(none)
Level 2	3.89	74.3%	include in Level 2	
Neither	—	—		
Subungual Hemorrhage				
Level 1	3.91	77.1%	include in Level 1	(none)
Level 2	—	—		
Neither	—	—		

Suggestions
"talon noir" → vote in Round 2
"mucous membranes" → vote in Round 2
"mucocutaneous junction (MCJ) nevi" → vote in Round 2

Additional Comments
"Except for subungual hemorrhage, distinguishing among the above in my opinion is not 'basic yet practical understanding of dermoscopy and its applications for the detection of skin cancer.'"

* A positive response is defined as selection of "strongly agree" (5) or "agree" (4).

J Am Board Fam Med: first published as 10.3122/jabfm.2022.220143R1 on 9 February 2023. Downloaded from http://www.jabfm.org/ on 20 April 2024 by guest. Protected by copyright.

Table 8. Results for other diagnoses, including skin infections and infestations (n=35 panelists). Responses were converted to a numerical scale with a minimum of 1, representing "strongly disagree," and a maximum of 5, representing "strongly agree."

Diagnosis Level	**Round 1: response average**	**Round 1: % positive responses***	**Next step**	**Comments**
Scabies				
Level 1	3.66	68.6%	re-vote in Round 2	(none)
Level 2	3.46	51.4%	re-vote in Round 2	
Neither	1.77	8.6%		
Molluscum contagiosum				
Level 1	3.59	52.9%	re-vote in Round 2	(none)
Level 2	3.59	58.8%	re-vote in Round 2	
Neither	1.71	2.9%		
Verruca				
Level 1	4.00	77.1%	include in Level 1	(none)
Level 2	—	—		
Neither	—	—		
Venous lake				
Level 1	3.34	51.4%	re-vote in Round 2	(none)
Level 2	3.51	51.4%	re-vote in Round 2	
Neither	1.80	2.9%		
Radiation tattoo				
Level 1	2.83	31.4%	exclude from Level 1	(none)
Level 2	3.60	54.3%	re-vote in Round 2	
Neither	2.11	5.7%		
Scars				
Level 1	2.74	25.7%	exclude from Level 1	(none)
Level 2	3.43	54.3%	re-vote in Round 2	
Neither	2.11	8.6%		

Suggestions → vote in Round 2
"psoriasis"
"atopic dermatitis"

Additional Comments
(none)

* A positive response is defined as selection of "strongly agree" (5) or "agree" (4).

J Am Board Fam Med: first published as 10.3122/jabfm.2022.220143R1 on 9 February 2023. Downloaded from http://www.jabfm.org/ on 20 April 2024 by guest. Protected by copyright.

VI. Next Steps for Panelists

All panelists who completed Round 1 will be invited to complete Round 2. The purpose of Round 2 will be to vote on diagnoses without a clear consensus for a particular level of proficiency (>50% but <70% "strongly agree" or "agree") and to vote on suggestions for additional diagnoses that were written in by panelists.

The deadline for the Round 2 survey is **Friday, November 5, 2021 5:00 PM CST**.

Following the conclusion of the diagnoses survey series, we will then poll panelists on the dermoscopic structures corresponding to each consensus-based diagnosis that would be appropriate for PCPs who use dermoscopy to recognize.

In closing, the research team greatly appreciates all panelists' time and effort in participating in this process. Panelists who complete all required survey instruments and who review the final study manuscript will be included as a co-author for publication.

VII. References

1. Fried LJ, Tan A, Berry EG, et al. Dermoscopy Proficiency Expectations for US Dermatology Resident Physicians: Results of a Modified Delphi Survey of Pigmented Lesion Experts. *JAMA Dermatol*. 2021;157(2):189-197. doi:10.1001/jamadermatol.2020.5213

If you have any questions or comments related to this study or your rights as a research participant, please e-mail Tiffaney Tran at [redacted].

J Am Board Fam Med: first published as 10.3122/jabfm.2022.220143R1 on 9 February 2023. Downloaded from http://www.jabfm.org/ on 20 April 2024 by guest. Protected by copyright.

Development of an Expert Consensus on Core Dermoscopy Proficiencies for PCPs Who Use Dermoscopy

Dermatologic Diagnoses: Round 2

Preliminary Results

November 15, 2021

J Am Board Fam Med: first published as 10.3122/jabfm.2022.220143R1 on 9 February 2023. Downloaded from http://www.jabfm.org/ on 20 April 2024 by guest. Protected by copyright.

I. Survey Objective

The objective of this survey series is to develop an expert-approved list of common dermosopic diagnoses plus characteristic dermoscopic features that should be included in dermoscopy training programs for PCPs.

Given the diversity of interest in and engagement with dermoscopy across the PCP spectrum, dermoscopic diagnoses will be sorted into the following two levels of dermoscopy proficiency:

- **Level 1** (Foundational) — PCPs who desire a basic yet practical understanding of dermoscopy and its applications for the detection of skin cancer should be able to recognize these diagnoses with sufficient training.

- **Level 2** (Intermediate) — PCPs who are highly interested in dermoscopy and desire further training in dermoscopy beyond Level 1 should be able to recognize these diagnoses. With sufficient training, recognition of these "above and beyond" diagnoses would demonstrate an additional level of mastery beyond Level 1.

In Round 1, panelists reviewed a list of diagnoses approved by the steering committee and considered whether each diagnosis should be included in the learning objectives for PCP-targeted dermoscopy education and, if so, in Level 1 or Level 2. The list of diagnoses in Round 1 was largely derived from a consensus-based list of dermoscopic diagnoses considered reflective of an appropriate foundational proficiency for dermatology residents.[1]

The purpose of Round 2 was to re-vote on diagnoses without a clear consensus for a particular level of proficiency (**>50%** but **<70%** "strongly agree" or "agree") and to vote on panelists' suggestions for additional diagnoses.

II. Survey Methods

On October 25, 2021, the Round 2 survey was distributed via e-mail to all panelists who completed Round 1. The survey instrument included a consent statement and a list of diagnoses divided into the following 5 sections:

1. Non-melanocytic lesions
2. Benign melanocytic lesions
3. Melanoma
4. Special sites
5. Other (including skin infections & infestations)

For each specific diagnosis, panelists considered the following questions:

- Should the diagnosis be included in **Level 1** (Foundational)?
- Should the diagnosis be included in **Level 2** (Intermediate) if not included in Level 1?
- Should the diagnosis <u>not</u> be included at <u>either</u> Level 1 or Level 2?

Panelists also had the opportunity to write in suggestions for additional diagnoses that will be voted on by the panel in Round 3 per the modified Delphi method.

Of the 35 colleagues who completed Round 1, 34 (97.1 %) voluntarily consented to continue to participate and completed the survey instrument. The collection of completed surveys ended on

J Am Board Fam Med: first published as 10.3122/jabfm.2022.220143R1 on 9 February 2023. Downloaded from http://www.jabfm.org/ on 20 April 2024 by guest. Protected by copyright.

November 12, 2021. Responses were de-identified, and data analyses were performed using REDCap and Excel.

III. Results Preview

The dermoscopic diagnoses that achieved consensus, or >70% agreement, are listed below. **Tables 1 and 2** include the diagnoses that panelists agreed should be included in **Levels 1 and 2**, respectively.

Table 1. Dermoscopic diagnoses that >70% panelists agreed should be included in Level 1. No new diagnoses were added in Round 2.

Nonmelanocytic lesions	Benign melanocytic lesions	Melanoma	Special sites	Other
• Basal cell carcinoma • Actinic keratosis • Squamous cell carcinoma • Simple lentigo • Solar lentigo • Seborrheic keratosis • Angioma • Dermatofibroma	• Overview of benign nevi patterns • Intradermal nevi	• Overview of melanoma patterns	• Subungual hemorrhage • Scabies	• Verruca

Table 2. Dermoscopic diagnoses that >70% panelists agreed should be included in Level 2. Diagnoses in **bold** are new additions to the list based on consensus outcomes from Round 2.

Nonmelanocytic lesions	Benign melanocytic lesions	Melanoma	Special sites	Other
• Pigmented actinic keratosis • Sebaceous hyperplasia • **Squamous cell carcinoma *in situ*** • **Keratoacanthoma** • **Angiokeratoma** • **Ink spot lentigo**	• Congenital melanocytic nevi • Blue nevi • Spitz nevi • **Recurrent/ persistent nevi** • **Halo nevi**	• Acral lentiginous melanoma • Lentigo maligna melanoma • **Amelanotic/ hypomelanotic melanoma**	• Dermoscopic features of the face • Benign patterns of acral nevi (if not included in Level 1) • Melanoma of the nail • **Lentigo of the nail**	• **Molluscum contagiosum** (if not included in Level 1) • **Venous lake** • **Psoriasis**

J Am Board Fam Med: first published as 10.3122/jabfm.2022.220143R1 on 9 February 2023. Downloaded from http://www.jabfm.org/ on 20 April 2024 by guest. Protected by copyright.

IV. Results

Panelists were instructed to rate on a Likert scale whether they agree that a diagnosis should be included in Level 1 (Foundational), included in Level 2 (Intermediate), or not be included at either level.

Panelists' responses on the Likert scale were converted to a numerical format with 1 representing "strongly disagree" and 5 representing "strongly agree." The selection of strongly agree" (5) or "agree" (4) was considered a "positive response" and contributed towards a survey item reaching consensus.

Tables 3-7, corresponding to the 5 different sections of the survey, summarize the results of Round 2. Panelists' suggestions for additional diagnoses and comments are also included. Panelists will vote on these suggested diagnoses in Round 3.

For each diagnosis, the aggregate of panelists' responses resulted in one of the following designations for the "next step":

- "include in Level 1" as a learning objective
  - The diagnosis reached a clear consensus for inclusion in Level 1 with >70% of panelists voting "strongly agree" (5) or "agree" (4).
  - The diagnosis is deemed appropriate for PCPs who desire a basic yet practical understanding of dermoscopy.

- "exclude from Level 1" / "include in Level 2" as a learning objective
  - The diagnosis did not reach a clear consensus for inclusion in Level 1. However, the diagnosis reached a clear consensus for inclusion in Level 2.
  - The diagnosis is deemed appropriate for PCPs who are highly interested in dermoscopy and desire further training beyond Level 1.

- "exclude from Level 1" / "exclude from Level 2" as a learning objective
  - The diagnosis is not deemed appropriate for either Level 1 or Level 2.

- "re-vote in Round 3"
  - The diagnosis did not reach a clear consensus for a particular level with >60% but <70% of panelists voting "strongly agree" (5) or "agree" (4).

J Am Board Fam Med: first published as 10.3122/jabfm.2022.220143R1 on 9 February 2023. Downloaded from http://www.jabfm.org/ on 20 April 2024 by guest. Protected by copyright.

Table 3. Results for diagnoses representing nonmelanocytic lesions (n=34 panelists). Responses were converted to a numerical scale with a minimum of 1, representing "strongly disagree," and a maximum of 5, representing "strongly agree."

Diagnosis Level	Round 1: response average	Round 1: % positive responses*	Round 2: response average	Round 2: % positive responses*	Next step
Squamous cell carcinoma in situ					
Level 1	3.97	65.7%	3.38	↓ 55.9%	exclude from Level 1
Level 2	3.80	68.6%	4.35	↑ 94.1%	include in Level 2
Neither	1.34	0%	—	—	
Keratoacanthoma					
Level 1	3.49	51.4%	3.09	↓ 44.1%	exclude from Level 1
Level 2	3.74	65.7%	4.15	↑ 82.4%	include in Level 2
Neither	1.49	0%	—	—	
Lichen planus-like keratosis					
Level 1	2.40	14.3%	—	—	exclude from Level 1
Level 2	3.63	57.1%	3.59	61.8%	re-vote in Round 3
Neither	1.97	17.1%	2.65	29.4%	
Angiokeratoma					
Level 1	3.11	37.1%	—	—	exclude from Level 1
Level 2	3.80	62.9%	3.74	↑ 73.5%	include in Level 2
Neither	1.57	2.9%	—	—	
Clear cell acanthoma					
Level 1	2.17	11.4%	—	—	exclude from Level 1
Level 2	3.69	65.7%	3.35	↓ 58.8%	exclude from Level 2
Neither	2.09	22.9%	—	—	
Sebaceous hyperplasia					
Level 1	3.66	54.3%	3.53	↓ 58.8%	exclude from Level 1
Level 2	4.03	77.1%	4.00	↑ 82.4%	include in Level 2
Neither	—	—	—	—	
Merkel cell carcinoma **(new)**					
Level 1	—	—	1.41	0.0%	exclude from Level 1
Level 2	—	—	2.82	35.3%	exclude from Level 2
Neither	—	—	3.12	50.0%	
Porokeratosis **(new)**					
Level 1	—	—	1.88	11.8%	exclude from Level 1
Level 2	—	—	3.24	47.1%	exclude from Level 2
Neither	—	—	2.88	41.2%	
Ink spot lentigo **(new)**					
Level 1	—	—	2.68	35.3%	exclude from Level 1
Level 2	—	—	4.00	79.4%	include in Level 2
Neither	—	—	2.15	14.7%	

Suggestions
"poroma" → vote in Round 3
"xanthogranuloma" → vote in Round 3

Additional Comments
"I think the goal for Level 2 for PCPs should be dermoscopy mastery to the level of a board-certified dermatologist."

* A positive response is defined as selection of "strongly agree" (5) or "agree" (4).

J Am Board Fam Med: first published as 10.3122/jabfm.2022.220143R1 on 9 February 2023. Downloaded from http://www.jabfm.org/ on 20 April 2024 by guest. Protected by copyright.

Table 4. Results for diagnoses representing benign melanocytic lesions (n=34 panelists). Responses were converted to a numerical scale with a minimum of 1, representing "strongly disagree," and a maximum of 5, representing "strongly agree."

Diagnosis Level	**Round 1: response average**	**Round 1: % positive responses***	**Round 2: response average**	**Round 2: % positive responses***	**Next step**
Blue Nevi					
Level 1	3.53	52.9%	3.38	58.8%	exclude from Level 1
Level 2	3.97	76.5%	3.94	↑ 79.4%	include in Level 2
Neither	—	—	—	—	
Recurrent/persistent nevi					
Level 1	2.50	14.7%	—	—	exclude from Level 1
Level 2	3.82	64.7%	2.26	↑ 73.5%	include in Level 2
Neither	2.00	2.9%	2.62	32.4%	
Halo nevi **(new)**					
Level 1	—	—	2.62	32.4%	exclude from Level 1
Level 2	—	—	3.85	79.4%	include in Level 2
Neither	—	—	—	—	
Combined nevi **(new)**					
Level 1	—	—	2.06	14.7%	exclude from Level 1
Level 2	—	—	3.59	58.8%	exclude from Level 2
Neither	—	—	2.26	20.6%	

Suggestions
(none)

Additional Comments
(none)

* A positive response is defined as selection of "strongly agree" (5) or "agree" (4).

J Am Board Fam Med: first published as 10.3122/jabfm.2022.220143R1 on 9 February 2023. Downloaded from http://www.jabfm.org/ on 20 April 2024 by guest. Protected by copyright.

Table 5. Results for diagnoses representing melanoma (n=34 panelists). Responses were converted to a numerical scale with a minimum of 1 representing "strongly disagree" and a maximum of 5 representing "strongly agree."

Diagnosis Level	**Round 1: response average**	**Round 1: % positive responses***	**Round 2: response average**	**Round 2: % positive responses***	**Next step**
Amelanotic/hypomelanotic melanoma					
Level 1	2.66	28.6%	—	—	exclude from Level 1
Level 2	3.71	65.7%	3.97	↑ 76.5%	include in Level 2
Neither	1.97	8.6%	—	—	
Nevoid melanoma **(new)**					
Level 1	—	—	2.00	14.7%	exclude from Level 1
Level 2	—	—	3.26	50.0%	exclude from Level 2
Neither	—	—	2.79	38.2%	
Desmoplastic melanoma **(new)**					
Level 1	—	—	1.91	11.8%	exclude from Level 1
Level 2	—	—	2.97	38.2%	exclude from Level 2
Neither	—	—	2.94	41.2%	
Verrucous melanoma **(new)**					
Level 1	—	—	1.85	11.8%	exclude from Level 1
Level 2	—	—	2.85	35.3%	exclude from Level 2
Neither	—	—	3.21	47.1%	

Suggestions
(none)

Additional Comments
"The reason for including melanoma is to make sure anyone trained in dermoscopy is not missing the chance to diagnose a melanoma. The consequences of a miss are too high."
"In clinical practice, many of these diagnoses/subtypes are not as relevant as the decision to excise or not."

* A positive response is defined as selection of "strongly agree" (5) or "agree" (4).

J Am Board Fam Med: first published as 10.3122/jabfm.2022.220143R1 on 9 February 2023. Downloaded from http://www.jabfm.org/ on 20 April 2024 by guest. Protected by copyright.

Table 6. Results for diagnoses related to special sites. Responses were converted to a numerical scale with a minimum of 1 representing "strongly disagree" and a maximum of 5 representing "strongly agree."

Diagnosis Level	**Round 1: response average**	**Round 1: % positive responses***	**Round 2: response average**	**Round 2: % positive responses***	**Next step**
Benign patterns of acral nevi					
Level 1	3.11	51.4%	3.53	64.7%	re-vote in Round 3
Level 2	3.86	74.3%	4.03	↑ 82.4%	include in Level 2
Neither	—	—	—	—	if not in Level 1
Lentigo of the nail					
Level 1	2.46	20.0%	—	—	exclude from Level 1
Level 2	3.71	62.9%	3.91	↑ 76.5%	include in Level 2
Neither	2.11	8.6%	—	—	
Talon noir **(new)**					
Level 1	—	—	2.62	32.4%	exclude from Level 1
Level 2	—	—	3.76	67.6%	re-vote in Round 3
Neither	—	—	2.26	17.6%	
Nevi of the mucosa **(new)**					
Level 1	—	—	1.79	11.8%	exclude from Level 1
Level 2	—	—	3.29	55.9%	exclude from Level 2
Neither	—	—	2.74	29.4%	
Nevi of the mucocutaneous junction **(new)**					
Level 1	—	—	1.68	5.9%	exclude from Level 1
Level 2	—	—	3.00	44.1%	exclude from Level 2
Neither	—	—	2.85	41.2%	

Suggestions
(none)

Additional Comments
"Talon noir and mucocutaneous lesions are quite rare. I would have no problem if they are omitted."

* A positive response is defined as selection of "strongly agree" (5) or "agree" (4).

J Am Board Fam Med: first published as 10.3122/jabfm.2022.220143R1 on 9 February 2023. Downloaded from http://www.jabfm.org/ on 20 April 2024 by guest. Protected by copyright.

Table 7. Results for other diagnoses, including skin infections and infestations (n=34 panelists). Responses were converted to a numerical scale with a minimum of 1 representing "strongly disagree" and a maximum of 5 representing "strongly agree."

Diagnosis Level	**Round 1: response average**	**Round 1: % positive responses***	**Round 2: response average**	**Round 2: % positive responses***	**Next step**
Scabies					
Level 1	3.66	68.6%	3.74	↑ 70.6%	include in Level 1
Level 2	3.46	51.4%	—	—	exclude from Level 2
Neither	1.77	8.6%	—	—	
Molluscum contagiosum					
Level 1	3.59	52.9%	3.56	64.7%	re-vote in Round 3
Level 2	3.59	58.8%	4.00	↑ 76.5%	include in Level 2
Neither	1.71	2.9%	—	—	if not in Level 1 1
Venous lake					
Level 1	3.34	51.4%	3.06	↓ 44.1%	exclude from Level 1
Level 2	3.51	51.4%	3.85	↑ 79.4%	include in Level 2
Neither	1.80	2.9%	—	—	
Radiation tattoo					
Level 1	2.83	31.4%	—	—	exclude from Level 1
Level 2	3.60	54.3%	3.62	67.6%	re-vote in Round 3
Neither	2.11	5.7%	2.26	20.6%	
Scars					
Level 1	2.74	25.7%	—	—	exclude from Level 1
Level 2	3.43	54.3%	3.62	67.6%	re-vote in Round 3
Neither	2.11	8.6%	2.38	20.6%	
Psoriasis **(new)**					
Level 1	—	—	2.65	32.4%	exclude from Level 1
Level 2	—	—	3.68	70.6%	include in Level 2
Neither	—	—	—	—	
Atopic dermatitis **(new)**					
Level 1	—	—	2.65	35.3%	exclude from Level 1
Level 2	—	—	3.24	52.9%	exclude from Level 2
Neither	—	—	2.76	38.2%	

Suggestions
(none)

Additional Comments
"I have never thought of atopic dermatitis as a dermatitis [dermoscopic?] diagnosis. I guess except on the palms or soles with its spongiotic findings."
"I do not find dermoscopy necessary for eczema or psoriasis, so [I] am not familiar with their dermoscopic features or utility."

* A positive response is defined as selection of "strongly agree" (5) or "agree" (4).

J Am Board Fam Med: first published as 10.3122/jabfm.2022.220143R1 on 9 February 2023. Downloaded from http://www.jabfm.org/ on 20 April 2024 by guest. Protected by copyright.

V. Next Steps for Panelists

All panelists who completed Round 2 will be invited to complete Round 3. The purpose of Round 3 will be to re-vote on diagnoses without a clear consensus for a particular level of proficiency (**>60% but <70%** "strongly agree" or "agree") and to vote on two additional diagnoses.

The deadline for the Round 3 survey is **Tuesday, November 23, 2021 5:00 PM CST** prior to the U.S. Thanksgiving holiday.

In the near future, panelists will vote on dermoscopic structures corresponding to each consensus-based diagnosis that would be appropriate for PCPs who use dermoscopy to recognize. The list of dermoscopic features will be largely derived from a consensus-based list of dermoscopic diagnoses considered reflective of an appropriate foundational proficiency for dermatology residents.[1] For additional diagnoses not on this list, we will consult Dermoscopedia[2] and other sources for relevant dermoscopic features.

In closing, the research team greatly appreciates all panelists' time and effort in participating in this process. Panelists who complete all required survey instruments and who review the final study manuscript will be included as a co-author for publication.

VI. References

1. Fried LJ, Tan A, Berry EG, et al. Dermoscopy Proficiency Expectations for US Dermatology Resident Physicians: Results of a Modified Delphi Survey of Pigmented Lesion Experts. *JAMA Dermatol*. 2021;157(2):189-197. doi:10.1001/jamadermatol.2020.5213
2. Dermoscopedia. International Dermosocpy Society (IDS). https://dermoscopedia.org/Main_Page

If you have any questions or comments related to this study or your rights as a research participant, please e-mail Tiffaney Tran at [redacted].

J Am Board Fam Med: first published as 10.3122/jabfm.2022.220143R1 on 9 February 2023. Downloaded from http://www.jabfm.org/ on 20 April 2024 by guest. Protected by copyright.

Development of an Expert Consensus on Core Dermoscopy Proficiencies for PCPs Who Use Dermoscopy

Dermatologic Diagnoses: Round 3

Preliminary Results

December 13, 2021

J Am Board Fam Med: first published as 10.3122/jabfm.2022.220143R1 on 9 February 2023. Downloaded from http://www.jabfm.org/ on 20 April 2024 by guest. Protected by copyright.

I. Survey Objective

The objective of this survey series is to develop an expert-approved list of common dermosopic diagnoses plus characteristic dermoscopic features that should be included in dermoscopy training programs for PCPs.

Given the diversity of interest in and engagement with dermoscopy across the PCP spectrum, dermoscopic diagnoses were sorted into the following two levels of dermoscopy proficiency:

- **Level 1** (Foundational) — PCPs who desire a basic yet practical understanding of dermoscopy and its applications for the detection of skin cancer should be able to recognize these diagnoses with sufficient training.

- **Level 2** (Intermediate) — PCPs who are highly interested in dermoscopy and desire further training in dermoscopy beyond Level 1 should be able to recognize these diagnoses. With sufficient training, recognition of these "above and beyond" diagnoses would demonstrate an additional level of mastery beyond Level 1.

In Round 1, panelists reviewed a list of diagnoses approved by the steering committee and considered whether each diagnosis should be included in the learning objectives for PCP-targeted dermoscopy education and, if so, in Level 1 or 2.

In Rounds 2, panelists re-voted on diagnoses without a clear consensus for a particular level of proficiency (>50% but <70% "strongly agree" or "agree") and voted on panelists' suggestions for additional diagnoses. The purpose of Round 3 was to conduct a simple majority vote on diagnoses still without a clear consensus for a particular level of proficiency (>60% but <70% "strongly agree" or "agree") and vote on panelists' suggestions.

II. Survey Methods

On November 15, 2021, the Round 3 survey was distributed via e-mail to all panelists who completed Round 2. The survey instrument included a consent statement and a list of 8 diagnoses, 2 of which represented newly suggested diagnoses.

Of the 35 colleagues who completed Round 1, 33 (94.3%) voluntarily consented to continue to participate and completed Round 3. Data collection concluded on December 2, 2021. Responses were de-identified, and data analyses were performed using REDCap and Excel.

III. Results Preview

The dermoscopic diagnoses that achieved consensus, or >70% agreement, are listed below. **Tables 1 and 2** include the diagnoses that panelists agreed should be included in **Level 1** and **Level 2**, respectively.

J Am Board Fam Med: first published as 10.3122/jabfm.2022.220143R1 on 9 February 2023. Downloaded from http://www.jabfm.org/ on 20 April 2024 by guest. Protected by copyright.

Table 1. Dermoscopic diagnoses that >70% panelists agreed should be included in Level 1. No new diagnoses were added in Round 3.

Nonmelanocytic lesions	Benign melanocytic lesions	Melanoma	Special sites	Other
• Basal cell carcinoma • Actinic keratosis • Squamous cell carcinoma • Simple lentigo • Solar lentigo • Seborrheic keratosis • Angioma • Dermatofibroma	• Overview of benign nevi patterns • Intradermal nevi	• Overview of melanoma patterns	• Subungual hemorrhage	• Scabies • Verruca

Table 2. Dermoscopic diagnoses that >70% panelists agreed should be included in Level 2. Diagnoses in **bold** are new additions to the list based on consensus outcomes from Round 3.

Nonmelanocytic lesions	Benign melanocytic lesions	Melanoma	Special sites	Other
• Pigmented actinic keratosis • Sebaceous hyperplasia • Squamous cell carcinoma *in situ* • Kerato-acanthoma • Angio-keratoma • Ink spot lentigo • **Lichen planus-like keratosis**	• Congenital melanocytic nevi • Blue nevi • Spitz nevi • Recurrent nevi (persistent nevi) • Halo nevi	• Acral lentiginous melanoma • Lentigo maligna melanoma • Amelanotic/ hypomelanotic melanoma	• Dermoscopic features of the face • Melanoma of the nail • Lentigo of the nail • **Benign patterns of acral nevi** • **Talon noir**	• Venous lake • Psoriasis • **Molluscum contagiosum** • **Radiation tattoo** • **Scars**

IV. Results Breakdown

A simple majority vote was conducted for diagnoses from previous rounds still without a clear consensus for a particular level of proficiency. **Table 1** summarizes these results in Round 3.

For new diagnoses, panelists were instructed as before to rate on a Likert scale whether they agree that a diagnosis should be included in Level 1 (Foundational), included in Level 2 (Intermediate), or not be included at either level. **Table 2** summarizes the results for new diagnoses in Round 3.

J Am Board Fam Med: first published as 10.3122/jabfm.2022.220143R1 on 9 February 2023. Downloaded from http://www.jabfm.org/ on 20 April 2024 by guest. Protected by copyright.

Table 3. Results for diagnoses previously without a clear consensus (n=33 panelists), based on a simple majority vote.

Category: *Diagnosis* Level	Round 3: # responses*	Round 3: % responses*	Next Step
Benign Nonmelanocytic Lesions: *Lichen planus-like keratosis*			
Level 1	—	—	exclude from Level 1*
Level 2	22	66.7%	include in Level 2
Neither	11	33.3%	
Special Sites: *Benign patterns of acral nevi*			
Level 1	15	45.5%	include in Level 2
Level 2	18	54.5%	
Neither	—	—	
Special Sites: *Talon noir*			
Level 1	—	—	exclude from Level 1*
Level 2	20	60.6%	include in Level 2
Neither	13	39.4%	
Other: *Molluscum contagiosum*			
Level 1	13	39.4%	include in Level 2
Level 2	20	60.6%	
Neither	—	—	
Other: *Radiation tattoo*			
Level 1	—	—	exclude from Level 1*
Level 2	22	66.7%	include in Level 2
Neither	11	33.3%	
Other: *Dermoscopic features of scars*			
Level 1	—	—	exclude from Level 1*
Level 2	19	57.6%	include in Level 2
Neither	14	42.4%	

Comments

"I think only lesions that could be tumors or need to be distinguished from tumors should be in a basic [Level 1] or Level 2 dermoscopy. More unusual conditions are for advanced training, more for dermatologists."

"Not certain [regarding] some of these [diagnoses], as dermoscopy not used for them, but format required an answer."

* This result was based on previous rounds of surveys.

J Am Board Fam Med: first published as 10.3122/jabfm.2022.220143R1 on 9 February 2023. Downloaded from http://www.jabfm.org/ on 20 April 2024 by guest. Protected by copyright.

Table 4. Results for additional diagnoses suggested in Round 2 (n=33 panelists). For a diagnosis to be included in Level 1 or Level 2, >70% of panelists must vote "strongly agree" (5) or "agree" (4) for that particular level.

Diagnosis Level	**Round 3: response average**	**Round 3: % positive response***	**Next step**
Poroma **(new)**			
Level 1	1.61	3.0%	exclude from Level 1
Level 2†	3.09	47.1%	exclude from Level 2
Neither	2.97	45.5%	
Xanthogranuloma **(new)**			
Level 1	1.39	0.0%	exclude from Level 1
Level 2†	2.64	30.3%	exclude from Level 2
Neither	3.39	60.6%	

* A positive response is defined as selection of "strongly agree" (5) or "agree" (4).
† Panelists were asked whether the specific diagnosis should be included in Level 2 if not included in Level 1.

V. Next Steps for Panelists

All panelists who completed Round 3 of the diagnoses survey series will be invited to complete Round 1 of the features survey series.

In the upcoming features survey series, panelists will consider dermoscopic structures corresponding to each consensus-based diagnosis and vote on whether each would be appropriate for PCPs who use dermoscopy to recognize.

The list of dermoscopic features will be largely derived from a consensus-based list of dermoscopic diagnoses considered reflective of an appropriate foundational proficiency for dermatology residents.[1] For additional diagnoses not on this list, we will consult Dermoscopedia[2] and other sources for relevant dermoscopic features.

The deadline for the next survey is **Wednesday, January 12, 2022 5:00 PM CST**.

In closing, the research team greatly appreciates all panelists' time and effort in participating in this process. Panelists who complete all required survey instruments and who review the final study manuscript will be included as a co-author for publication.

VI. References

1. Fried LJ, Tan A, Berry EG, et al. Dermoscopy Proficiency Expectations for US Dermatology Resident Physicians: Results of a Modified Delphi Survey of Pigmented Lesion Experts. *JAMA Dermatol.* 2021;157(2):189-197. doi:10.1001/jamadermatol.2020.5213
2. Dermoscopedia. International Dermosocpy Society (IDS). https://dermoscopedia.org/Main_Page

If you have any questions or comments related to this study or your rights as a research participant, please e-mail Tiffaney Tran at [redacted].

J Am Board Fam Med: first published as 10.3122/jabfm.2022.220143R1 on 9 February 2023. Downloaded from http://www.jabfm.org/ on 20 April 2024 by guest. Protected by copyright.

Development of an Expert Consensus on Core Dermoscopy Proficiencies for PCPs Who Use Dermoscopy

Dermoscopic Features: Round 1

Preliminary Results

January 24, 2022

J Am Board Fam Med: first published as 10.3122/jabfm.2022.220143R1 on 9 February 2023. Downloaded from http://www.jabfm.org/ on 20 April 2024 by guest. Protected by copyright.

I. Survey Objective

The objective of this features survey series is to develop an expert-approved list of characteristic dermoscopic features that should be included in dermoscopy training programs for PCPs.

The goal is to capture the dermoscopic structures that are highly characteristic and important to recognize. This also includes commonly seen structures that may not be specific to one diagnosis.

II. Survey Methods

On December 16, 2021, the Round 1 survey was distributed via e-mail to all panelists who completed the dermoscopic survey series. The survey instrument included a consent statement and a consensus-based list of dermoscopic diagnoses divided into five sections:

1. Nonmelanocytic lesions
2. Benign melanocytic lesions
3. Melanoma
4. Special sites
5. Other
6. Miscellaneous

A miscellaneous section was included to solicit input on a new addition to the list of consensus-based diagnoses, namely nevus of the nail. This diagnosis was inadvertently left off the diagnoses survey series.

For each diagnosis, panelists reviewed a number of dermoscopic features approved by the steering committee and considered whether each feature should be included as a learning objective for PCP-targeted dermoscopy education.

Of the 33 colleagues who completed the diagnoses survey series, 33 (100%) voluntarily consented to continue to participate and completed Round 1 of the features survey series.

Data collection concluded on January 24, 2022. Responses were de-identified, and data analyses were performed using REDCap and Excel.

J Am Board Fam Med: first published as 10.3122/jabfm.2022.220143R1 on 9 February 2023. Downloaded from http://www.jabfm.org/ on 20 April 2024 by guest. Protected by copyright.

III. Results

For each dermoscopic feature, panelists were asked to rate on a Likert scale whether they agree that the feature should be included in dermoscopy education for PCPs who use dermoscopy. For each survey item, the options for the Likert scale were:

1. Strongly disagree
2. Disagree
3. Neutral
4. Agree
5. Strongly agree

Panelists' responses on the Likert scale were converted to a numerical format with 1 representing "strongly disagree" and 5 representing "strongly agree," as above. The selection of strongly agree" (5) or "agree" (4) was considered a "positive response" and contributed towards a survey item reaching consensus.

Tables 1-6, corresponding to the 5 different sections plus the miscellaneous section, summarize the results of Round 1. Panelists' suggestions for additional features and comments are also included. Panelists will vote on these suggested features in Round 2.

For each feature, the aggregate of panelists' responses resulted in one of the following designations for the "next step":

- "include" as a learning objective
  - The feature reached a clear consensus for inclusion in PCP-targeted dermoscopy education with >70% of panelists voting "strongly agree" (5) or "agree" (4).
- "exclude" as a learning objective
  - The feature reached a clear consensus for exclusion from PCP-targeted dermoscopy education with <50% panelists voting "strongly agree" (5) or "agree" (4). In other words, >50% of panelists voted "neutral" (3), "disagree" (2), or "strongly disagree" (1).
- "re-vote in Round 2"
  - The feature did not reach a clear consensus for inclusion with >60% but <70% of panelists voting "strongly agree" (5) or "agree" (4).

J Am Board Fam Med: first published as 10.3122/jabfm.2022.220143R1 on 9 February 2023. Downloaded from http://www.jabfm.org/ on 20 April 2024 by guest. Protected by copyright.

Table 1. Results for diagnoses representing nonmelanocytic lesions (n=33). Responses were converted to a numerical scale with a minimum of 1, representing "strongly disagree," and a maximum of 5, representing "strongly agree."

Survey Item	Round 1: response average	Round 1: % positive responses*	Next step	Round 1: comments
Angioma (Level 1)				"Blue-black coloring: okay if in lacunae in absence of other structures." – **added** "Not sure PCPs need to correctly identify a thrombosed angioma/angio-keratoma." – **re-vote in Round 2** "Not sure a thrombosed angioma needs to be included. I think they are easily identified as unimportant on gross exam." – **re-vote in Round 2**
Red, blue-red, red-purple, or maroon lacunae/lagoons with white septae	4.91	72.7%	include	
Blue-black coloring in lacunae (when thrombosed) in absence of other structures	4.03	72.7%	~~include~~ re-vote in Round 2	
Dermatofibroma (Level 1)				"Shiny white lines: with polarization." – **added** "Blood vessels are not a major component." – **excluded by consensus** "Lesion needs to be firm and dimple." – **clinical feature**
Central scar-like white patch/depigmentation	4.94	100.0%	include	
Fine/delicate surrounding/peripheral network-like structures	4.79	100.0%	include	
Ring-like globules	3.97	66.7%	re-vote in Round 2	
Central shiny white lines/streaks under polarized dermoscopy	4.42	84.8%	include	
Dotted vessels	3.27	39.4%	exclude	
Central pink blush	3.30	42.4%	exclude	
Seborrheic keratosis (Level 1)				"Milia-like cysts AND comedo-like openings together (DD: dermal nevus)." – **combined** "Whitish halo: difficult to see in daily practice." – **updated** "I would just include fingerprint-like structures in lentigo as below." – **updated**
Milia-like cysts (cloudy or starry) and comedo-like openings	4.79	93.9%	include	
~~Comedo-like openings~~	~~4.79~~	~~93.9%~~	~~include~~	
Moth-eaten (sharply demarcated) borders	4.45	87.9%	include	
'Fissures and ridges' / 'gyri and sulci' / cerebriform pattern	4.70	93.9%	include	
Fat fingers	4.18	78.8%	include	
Fingerprint-like structures/~~pattern~~ (parallel lines)	4.27	78.8%	include	
Hairpin (looped) vessels~~, usually with whitish halo~~	3.97	78.8%	include	
Solar lentigo (Level 1)				(none)
Moth-eaten (sharply demarcated) borders	4.58	90.9%	include	
Homogenous light brown pigmentation	4.52	87.9%	include	
Network-like structures	3.97	63.6%	re-vote in Round 2	
Fingerprint-like structures (parallel lines)	4.42	90.9%	include	
Uniform brown perifollicular pigmentation	4.06	75.8%	include	
Basal cell carcinoma (Level 1)				"From the dermoscopy-using PCP's point of view, knowing it is a BCC is not as important as knowing it is cancer and must be removed." "Please decide if we use leaf-like or spoke wheel, not both. Or use one as a main description and the other as 'AKA.'" – **descriptions adapted from Fried *et al.*, 2021**
Leaf-like structures/areas	4.58	90.9%	include	
Blue-gray ovoid nests	4.55	87.9%	include	
Multiple blue-gray dots and globules (buckshot scatter)	4.45	84.8%	include	
Spoke-wheel-like structures/areas / concentric structures	4.36	87.9%	include	
Ulceration / erosion	4.64	93.9%	include	
Shiny white blotches and strands / structures	4.06	69.7%	re-vote in Round 2	
Arborizing vessels	4.88	97.0%	include	

J Am Board Fam Med: first published as 10.3122/jabfm.2022.220143R1 on 9 February 2023. Downloaded from http://www.jabfm.org/ on 20 April 2024 by guest. Protected by copyright.

Survey Item	Round 1: response average	Round 1: % positive responses*	Next step	Round 1: comments
Short fine telangiectasias (superficial BCC)	4.03	69.7%	re-vote in Round 2	
Actinic keratosis (Level 1)				"Agree the strawberry pattern should be included, but the description is much too long and somewhat confusing for a non-expert." – **description adapted from Fried *et al.*, 2021**
Rosettes	4.33	81.8%	include	
Surface scale	4.67	97.0%	include	
Strawberry pattern (pink-red pseudonetwork +/- fine wavy vessels [straight or coiled] surrounding hair follicles +/- white circles with central yellow clod [targetoid hair follicles])	4.30	78.8%	include	
Squamous cell carcinoma (Level 1)				"I usually think of the hairpin vessels with white halo as more suggestive of ISK, whereas SCCs have less of a halo." – **updated**
Yellow keratin mass / scale-crust	4.73	100.0%	include	
Ulceration / blood spots / hemorrhage	4.61	93.9%	include	
White circles ('keratin pearls')	4.48	90.9%	include	
Rosettes	4.15	75.8%	include	
Glomerular (coiled) vessels	4.42	90.9%	include	
Hairpin vessels~~, usually with +/- whitish halo~~	4.15	78.8%	include	
Sebaceous hyperplasia (Level 2)				"Suggest crown vessels—out of focus—when compared to telangiectasia in BCC." – **added**
Pale yellow lobules (popcorn-like structures) around a central follicular opening	4.82	100.0%	include	
Crown vessels, out of focus	4.61	90.9%	include	
Ink spot lentigo (Level 1)				"Suggest: Prominent dark homogenous (uniform) reticular network." – **added**
Prominent dark homogenous (uniform) reticular network	4.64	93.9%	include	
Chicken-wire fence	3.85	63.6%	re-vote in Round 2	
Pigmented actinic keratosis (Level 2)				"Pigmented AK vs lentigo maligna or SCC is too complex for PCP level." "The pigmented AK is relatively rare and a very difficult diagnosis. I am not sure if this belongs in a PCP curriculum at all because in my opinion, it is more confusing than anything else." "Tough call to make for beginning dermoscopy." **inclusion in Level 2 based on panel consensus**
Gray dots	3.82	69.7%	re-vote in Round 2	
Annular-granular pattern (gray dots around follicular openings)	3.82	66.7%	re-vote in Round 2	
Rosettes	4.00	75.8%	include	
Surface scale	4.48	90.9%	include	
Red pseudonetwork	3.67	57.6%	exclude	
White circles	3.48	42.4%	exclude	
Patent/evident follicles	3.67	57.6%	exclude	
Squamous cell carcinoma *in situ* (Level 2)				"It's a tall ask to have PCPs diagnose pigmented Bowen's." – **re-vote in Round 2** "The peripheral dots are extremely rare and not very typical. I would leave this out." – **excluded** "Glomerular vessels 'irregularly arranged' to differentiate from psoriasis with regular spacing and arrangement of dotted/coiled/glomerular vessels." – **added**
Surface scale	4.52	87.9%	include	
Peripheral brown/gray dots arranged linearly (pigmented SCCIS)	3.85	60.6%	re-vote in Round 2	
Irregularly arranged glomerular (coiled) / dotted vessels	4.55	93.9%	include	
Keratoacanthoma (Level 2)				(none)
Central keratin mass	4.73	93.9%	include	
Hairpin (looped) or serpentine (linear-irregular) vessels, usually at the periphery, with white-yellow halo	4.52	87.9%	include	

J Am Board Fam Med: first published as 10.3122/jabfm.2022.220143R1 on 9 February 2023. Downloaded from http://www.jabfm.org/ on 20 April 2024 by guest. Protected by copyright.

Survey Item	Round 1: response average	Round 1: % positive responses*	Next step	Round 1: comments
Angiokeratoma (Level 2)				"Not sure PCPs should be asked to diagnose this lesion." – **inclusion in Level 2 based on panel consensus**
Red/purple/black ('dark') lacunae	4.61	93.9%	include	
Hemorrhagic crust	4.09	75.8%	include	
Lichen planus-like keratosis (Level 2)				
Coarse gray granularity	3.88	63.6%	re-vote in Round 2	"Not sure PCPs should be asked to identify these lesions." – **inclusion in Level 2 based on panel consensus** "It gets pretty complicated, and I am liking TADA more and more for teaching." "I would like PCPs to see gray granularity and stop and think carefully. I worry they will miss melanomas with regression thinking they are LPLKs." "Please include blue-grey/blue-white structures." – **vote in Round 2**
Peppering (evenly spaced gray dots)	4.03	69.7%	re-vote in Round 2	
Sharp cut-off borders (scalloped/moth-eaten)	4.06	69.7%	re-vote in Round 2	
Features of a lentigo or a seborrheic keratosis in an area	4.15	72.7%	include	

* A positive response is defined as selection of "strongly agree" (5) or "agree" (4).

J Am Board Fam Med: first published as 10.3122/jabfm.2022.220143R1 on 9 February 2023. Downloaded from http://www.jabfm.org/ on 20 April 2024 by guest. Protected by copyright.

Table 2. Results for diagnoses representing benign melanocytic lesions (n=33). Responses were converted to a numerical scale with a minimum of 1, representing "strongly disagree," and a maximum of 5, representing "strongly agree."

Diagnosis (Level classification) Feature, added, ~~removed~~	**Round 1: response average**	**Round 1: % positive response***	**Next step**	**Round 1: comments**
Overview of benign nevi patterns (Level 1)				"PCP should not be asked to differentiate complex nevi from melanoma."
Diffuse reticular network	4.85	100.0%	include	
Patchy reticular network	4.70	97.0%	include	
Peripheral reticular network with central hypopigmentation	4.76	100.0%	include	
Peripheral reticular network with central hyperpigmentation	4.76	100.0%	include	
Peripheral reticular network with central globules	4.61	90.9%	include	
Homogenous (tan, brown, blue, or pink)	4.64	93.9%	include	
Central network with evenly distributed peripheral globules	4.55	87.9%	include	
Globular pattern	4.82	100.0%	include	
Two-component pattern	4.06	69.7%	re-vote in Round 2	
Symmetric multicomponent pattern	4.15	75.8%	include	
Intradermal nevi (Level 1)				"wobble sign" – **clinical feature**
Comma-shaped (curved) vessels	4.58	93.9%	include	
Homogenous (structureless) brown/tan/pink pigmentation	4.52	93.9%	include	
Peripheral network	4.03	72.7%	include	
Globules	4.36	87.9%	include	
Congenital melanocytic nevi (Level 1)				"Why are we asking PCPs to diagnose CMN?" – **inclusion in Level 2 based on panel consensus** "central hypo-pigmentation" – **vote in Round 2**
Cobblestone pattern/globular pattern	4.64	93.9%	include	
Reticular network	4.45	90.9%	include	
Homogenous background pigmentation	4.45	87.9%	include	
Hypertrichosis	4.30	78.8%	include	
Perifollicular hyper-/hypo-pigmentation	4.06	69.7%	re-vote in Round 2	
Blue nevi (Level 2)				"History is important." – **clinical feature** "Need to be presented with photos of melanoma metastases to increase suspicion of a blue/gray macule in a patient with a history of melanoma." – **clinical feature** "Must include clinical stability over time." – **clinical feature**
Homogenous blue/blue-gray pigmentation	4.88	100.0%	include	
Well-circumscribed	4.67	93.9%	include	
Spitz nevi (Level 2)				"Maybe include pseudopods as an option in #27 [starburst pattern], regularly spaced at the periphery." – **added** "PCPs should not be asked to differentiate spitz from melanoma." "Some spitz nevi have several red flag features that I would want someone to think of melanoma. I would rather have them biopsy spitz nevi than miss melanomas." "These are important findings but very advanced skills." **inclusion in Level 2 based on panel consensus**
Vascular pattern (pink homogenous with dotted vessels)	4.00	75.8%	include	
Starburst pattern with tiered globules/streaks and regularly spaced pseudopods at the periphery (radial streaming)	4.55	87.9%	include	
Negative pigment network (reticular depigmentation)	3.85	60.6%	re-vote in Round 2	
Shiny white lines (crystalline structures)	3.82	63.6%	re-vote in Round 2	
Globular with negative network or blue-white veil	3.64	60.6%	re-vote in Round 2	

J Am Board Fam Med: first published as 10.3122/jabfm.2022.220143R1 on 9 February 2023. Downloaded from http://www.jabfm.org/ on 20 April 2024 by guest. Protected by copyright.

Diagnosis (Level classification) Feature, added, ~~removed~~	**Round 1: response average**	**Round 1: % positive response***	**Next step**	**Round 1: comments**
Recurrent/persistent nevi (Level 2)				
Pigment within the scar, not extending beyond	4.30	81.8%	include	"? adding **starburst/radial pattern**" – **vote in Round 2** "Not sure that PCP should be asked to identify recurrent nevi." **inclusion in Level 2 based on panel consensus**
Halo nevi (Level 2)				
Encircling/surrounding depigmentation/pallor	4.52	93.9%	include	"The most common nevus that undergoes halo reaction are **globular** and **homogeneous**." – **added**
Central reticulation with peripheral white depigmentation	4.03	78.8%	include	"Only **globular** pattern is acceptable. Everything else comes off." – **added**
Benign nevi patterns, globular, homogenous	4.12	78.8%	include	"Need to make a note about doing a thorough skin exam to search for a melanoma."

* A positive response is defined as selection of "strongly agree" (5) or "agree" (4).

J Am Board Fam Med: first published as 10.3122/jabfm.2022.220143R1 on 9 February 2023. Downloaded from http://www.jabfm.org/ on 20 April 2024 by guest. Protected by copyright.

Table 3. Results for diagnoses representing melanoma (n=33). Responses were converted to a numerical scale with a minimum of 1, representing "strongly disagree," and a maximum of 5, representing "strongly agree."

Diagnosis (Level classification) Feature, added, ~~removed~~	**Round 1: response average**	**Round 1: % positive response***	**Next step**	**Round 1: comments**
Overview of melanoma patterns (Level 1)				"Shiny white lines/structures (crystalline structures comes up in several lesions and may cause confusion." – **okay to include if commonly seen** "Would re-phrase off-center blotch." – **added**
Atypical pigment network	4.82	97.0%	include	
Blue structures (blue-white veil, blue-gray structures)	4.88	100.0%	include	
Shiny white lines/structures (crystalline structures)	4.76	100.0%	include	
Negative pigment network	4.55	87.9%	include	
Atypical/irregular dots/globules	4.67	93.9%	include	
Atypical/irregular streaks (radial streaming, pseudopods)	4.76	97.0%	include	
Regression structures (white scar-like area and/or peppering)	4.70	93.9%	include	
Peripheral brown/tan structureless area	4.21	78.8%	include	
Angulated lines (extrafacial) / polygons / zig-zag pattern	4.21	75.8%	include	
Atypical vascular pattern/structures, polymorphous vessels (2+ types of blood vessels)	4.39	87.9%	include	
Atypical/off-center blotch	4.18	69.7%	re-vote in Round 2	
Acral melanoma (Level 2)				"pigment crossing normal ridge pattern" – **vote in Round 2** "#14 [irregular diffuse pigmentation] add blotch." – **added** "Maybe change/add descriptors in multicomponent pattern: asymmetry of structures/colors." – **added** "neovascularization → milky red" – **added** "Negative predictors of PFP [parallel furrow pattern] and fibrillar [pattern?] to stay in line with **BRAAFF checklist**." **BRAAFF checklist:** Lallas A, et al. The BRAAFF checklist: a new dermoscopic algorithm for diagnosing acral melanoma. *Br J Dermatol*. 2015;173(4):1041-1049.
Parallel ridge pattern	4.76	93.9%	include	
Irregular diffuse pigmentation or blotch	4.39	84.8%	include	
Multicomponent pattern, asymmetry of structures/colors	4.36	84.8%	include	
Atypical fibrillar pattern	4.15	72.7%	include	
Ulceration	4.58	90.9%	include	
Neo-vascularization, milky red	4.00	72.7%	include	
Lentigo maligna melanoma (Level 2)				(none)
Annular-granular pattern (gray dots around follicular openings)	4.45	90.9%	include	
Asymmetric pigmentation around follicular openings / asymmetric follicular openings	4.42	87.9%	include	
Rhomboidal structures (angulated lines) / zig-zag pattern	4.39	81.8%	include	
Circle within a circle (isobar)	3.94	60.6%	re-vote in Round 2	
Dark blotches +/- obliterated hair follicles	4.21	75.8%	include	
Amelanotic/hypomelanotic melanoma (Level 2)				(none)
Scar-like depigmentation	4.21	75.8%	include	
Milky red areas	4.42	81.8%	include	
Shiny white lines (crystalline structures)	4.39	81.8%	include	
Atypical vascular pattern, polymorphous vessels (2+ types of blood vessels)	4.24	81.8%	include	

* A positive response is defined as selection of "strongly agree" (5) or "agree" (4).

J Am Board Fam Med: first published as 10.3122/jabfm.2022.220143R1 on 9 February 2023. Downloaded from http://www.jabfm.org/ on 20 April 2024 by guest. Protected by copyright.

Table 4. Results for diagnoses related to special sites (n=33). Responses were converted to a numerical scale with a minimum of 1, representing "strongly disagree," and a maximum of 5, representing "strongly agree."

Diagnosis (Level classification) Feature, added, ~~removed~~	**Round 1: response average**	**Round 1: % positive response***	**Next step**	**Round 1: comments**
Subungual hemorrhage (Level 1)				"What about the lightning sign or white streaks?" – **vote in Round 2** "The amount of info will be daunting for PCPs, so recommend keep teaching focused." "Not so sure subungual hemorrhage needs a dermoscopic description." "For the 'discontinuous with the cuticle,' perhaps you mean not connected to the proximal nailfold/edge of nail?" – **added**
Well-circumscribed red-black dots or blotches / blood spots	4.58	90.9%	include	
Distal streaks of red-brown coloration ('filamentous' distal end)	4.27	81.8%	include	
Homogenous red/purple/black coloration without melanin granules	4.09	69.7%	re-vote in Round 2	
Discontiguous with the cuticle (not connected to the proximal nailfold or edge of nail)	4.42	87.9%	include	
Dermoscopic features of the face (Level 2)				"Not sure what this section is about."
Pseudonetwork	4.27	78.8%	include	
Benign patterns of acral nevi (Level 2)				"#12 [peas in a pod pattern] is more complex and not sure it's something the PCP needs to know." – **re-vote in Round 2** "Does it make sense to teach the benign patterns, or should we teach the malignant patterns and leave everything else in place?" – **benign patterns included based on panel consensus** "hard"
Parallel furrow pattern (with pattern variations including single line, double line, single dotted line, double-dotted line)	4.73	93.9%	include	
Lattice-like pattern	4.55	87.9%	include	
Fibrillar pattern (soles only)	4.48	84.8%	include	
Homogenous pattern	4.21	75.8%	include	
Peas in a pod pattern (parallel furrow + globules on ridges) (congenital nevi)	4.03	69.7%	re-vote in Round 2	
Lentigo of the nail (Level 2)				"regular brown lines" – **vote in Round 2** "I would call it gray band. Multiple is an exception." – **updated**
~~Multiple thin homogenous gray lines (or single gray band) +/- gray background~~ homogenous gray band or lines +/- gray background	4.18	78.8%	include	
Melanoma of the nail (Level 2)				"#19 [longitudinal brown/black lines with irregular spacing] add broken lines" – **added** "Nail dermoscopy is very advanced." "The ability to sort out benign acral nevi vs melanoma is very difficult. If you can make this easier, it would be super."
Triangular shape of pigment band (band diameter wider at proximal end)	4.45	87.9%	include	
Pigmentation of periungual skin (micro-Hutchinson's sign)	4.39	90.9%	include	
Brown to black dots/globules associated with longitudinal lines	3.91	60.6%	re-vote in Round 2	
Longitudinal brown/black broken lines with irregular spacing, width, coloration, or parallelism	4.30	81.8%	include	
Band width >3 mm or 2/3 of nail plate width	4.27	78.8%	include	
Talon noir (Level 2)				"I feel like when you say parallel ridge, it has a connotation of melanoma, so perhaps just say homogenous red-brown coloration?" – **removed "parallel ridge"** "I don't know the lightning bolt sign." – **excluded by consensus** "What about the possibility of scratching the lesion to remove the hemorrhage in the stratum corneum?" – **clinical feature** "ability to scrape off clinically" – **clinical feature**
Homogenous ~~or parallel-ridge~~ red-brown coloration	4.15	78.8%	include	
Peripheral red-brown dots/globules	4.03	66.7%	re-vote in Round 2	
Cracks (lightning bolt sign)	3.76	51.5%	exclude	

* A positive response is defined as selection of "strongly agree" (5) or "agree" (4).

J Am Board Fam Med: first published as 10.3122/jabfm.2022.220143R1 on 9 February 2023. Downloaded from http://www.jabfm.org/ on 20 April 2024 by guest. Protected by copyright.

Table 5. Results for other diagnoses, including skin infections and infestations (n=33). Responses were converted to a numerical scale with a minimum of 1, representing "strongly disagree," and a maximum of 5, representing "strongly agree."

Diagnosis (Level classification) Feature, added, ~~removed~~	**Round 1: response average**	**Round 1: % positive response***	**Next step**	**Round 1: comments**
Scabies (Level 1)				"Consider including burrows on its own since they may not always see the mite?" – **clinical feature**
Delta-wing jet with contrail sign (small dark brown triangular structure located at the end of whitish structureless curved/wavy lines)	4.52	90.9%	include	
Verruca (Level 1)				"Don't really need dermatoscope for this."
Papilliform structures	4.67	93.9%	include	
Tiny red-black dots (papillary capillaries)	4.61	90.9%	include	
Molluscum contagiosum (Level 1)				"Don't really need dermatoscope for this." "Not sure if we should dermoscopy of molluscum in this context."
Central pore or umbilication	4.61	93.9%	include	
Polylobular white-yellow amorphous structures	4.27	81.8%	include	
Linear or branched vessels (red corona) / crown vessels	3.97	63.6%	re-vote in Round 2	
Venous Lake (Level 2)				(none)
Homogenous purple/ blue/red coloration +/- globules/clods	4.61	93.9%	include	
Psoriasis (Level 2)				"Would agree strongly if 12 said white only not white-yellow." – **changed to white** "I'm not sure [if dermoscopy] is relevant to this effort." – **based on consensus** "I don't do dermoscopy on psoriasis."
Red or pink color with ~~white-yellow~~ white scales / light red background	4.03	75.8%	include	
Dotted vessels in a regular distribution	4.03	72.7%	include	
Twisted red loops in a homogenous distribution	3.42	45.5%	exclude	
Glomerular vessels	3.42	45.5%	exclude	
Radiation tattoo (Level 2)				(none)
Homogenous blue or black coloration	4.33	84.8%	include	
Dermoscopic features of scars (Level 2)				(none)
Arborizing, linear irregular, or comma vessels in keloids	3.58	45.5%	exclude	
White depigmentation	4.00	72.7%	include	

* A positive response is defined as selection of "strongly agree" (5) or "agree" (4).

J Am Board Fam Med: first published as 10.3122/jabfm.2022.220143R1 on 9 February 2023. Downloaded from http://www.jabfm.org/ on 20 April 2024 by guest. Protected by copyright.

Table 6. Results for nevus of the nail, a diagnosis inadvertently left off on prior surveys (n=33). Responses were converted to a numerical scale with a minimum of 1, representing "strongly disagree," and a maximum of 5, representing "strongly agree."

Diagnosis or feature	Round 1: response average	Round 1: % positive response*	Next step	Round 1: comments
Diagnosis: *Nevus of the nail*				(none)
Level 1	2.58	21.2%	exclude from Level 1	
Level 2	3.91	78.8%	include in Level 2	
Neither	2.30	15.2%		
Feature: *Nevus of the nail* (Level 2)				"unbroken lines" – **added** "Including blue is confusing." – **removed**
Homogenous brown background coloration	4.15	84.8%	include	
Uniform band thickness, color ~~(including blue)~~, and spacing with parallel band configuration and unbroken lines	4.24	87.9%	include	

* A positive response is defined as selection of "strongly agree" (5) or "agree" (4).

IV. Next Steps for Panelists

All panelists who completed Round 1 of the features survey series will be invited to complete Round 2. The purpose of Round 2 will be to vote on feature without a clear consensus and to vote on suggestions for additional features that were written in by panelists.

The deadline for the next survey is **Wednesday, February 9, 2022 5:00 PM CST**.

In closing, the research team greatly appreciates all panelists' time and effort in participating in this process. Panelists who complete all required survey instruments and who review the final study manuscript will be included as a co-author for publication.

If you have any questions or comments related to this study or your rights as a research participant, please e-mail Tiffaney Tran at [redacted].

J Am Board Fam Med: first published as 10.3122/jabfm.2022.220143R1 on 9 February 2023. Downloaded from http://www.jabfm.org/ on 20 April 2024 by guest. Protected by copyright.

Development of an Expert Consensus on Core Dermoscopy Proficiencies for PCPs Who Use Dermoscopy

Dermoscopic Features: Round 2

Preliminary Results

February 18, 2022

J Am Board Fam Med: first published as 10.3122/jabfm.2022.220143R1 on 9 February 2023. Downloaded from http://www.jabfm.org/ on 20 April 2024 by guest. Protected by copyright.

I. Survey Objective

The objective of this features survey series is to develop an expert-approved list of characteristic dermoscopic features that should be included in dermoscopy training programs for PCPs. The goal is to capture the dermoscopic structures that are highly characteristic and important to recognize. This also includes commonly seen structures that may not be specific to one diagnosis.

In Round 1, panelists reviewed a list of dermoscopic features approved by the steering committee and considered whether each feature should be included in the learning objectives for PCP-targeted dermoscopy education.

The purpose of Round 2 was to re-vote on features without a clear consensus for inclusion and to vote on panelists' suggestions for additional features.

II. Survey Methods

On January 26, 2021, the Round 2 survey was distributed via e-mail to all panelists who completed Round 1. The survey instrument included a consent statement and a consensus-based list of dermoscopic diagnoses divided into five sections:

1. Nonmelanocytic lesions
2. Benign melanocytic lesions
3. Melanoma
4. Special sites
5. Other (including skin infections & infestations)

Panelists re-voted on dermoscopic features without a clear consensus and voted on suggestions for additional features.

Of the 33 colleagues who completed Round 1, 30 (90.9%) voluntarily consented to continue to participate and completed Round 2. Data collection concluded on February 18, 2022. Responses were de-identified, and data analyses were performed using REDCap and Excel.

J Am Board Fam Med: first published as 10.3122/jabfm.2022.220143R1 on 9 February 2023. Downloaded from http://www.jabfm.org/ on 20 April 2024 by guest. Protected by copyright.

III. Results

For each dermoscopic feature, panelists were asked to rate on a Likert scale whether they agree that the feature should be included in dermoscopy education for PCPs who use dermoscopy. For each survey item, the options for the Likert scale were:

1. Strongly disagree
2. Disagree
3. Neutral
4. Agree
5. Strongly agree

Panelists' responses on the Likert scale were converted to a numerical format with 1 representing "strongly disagree" and 5 representing "strongly agree," as above. The selection of strongly agree" (5) or "agree" (4) was considered a "positive response" and contributed towards a survey item reaching consensus.

Tables 1-5, corresponding to the 5 different sections, summarize the results of Round 2. Panelists' comments are also included.

For each feature, the aggregate of panelists' responses resulted in one of the following designations for the "next step":

- "include" as a learning objective for PCPs
  - >70% of panelists voted "strongly agree" (5) or "agree" (4) in Round 2.
- "potentially include" as a learning objective for PCPs depending on the skill level of the educational cohort (up to the discretion of the instructor)
  - <70% but >50% of panelists voted "strongly agree" (5) or "agree" (4) in both Round 1 and Round 2.
- "exclude" as a learning objective for PCPs
  - <50% of panelists voted "strongly agree" (5) or "agree" (4) in either Round 1 or Round 2.

J Am Board Fam Med: first published as 10.3122/jabfm.2022.220143R1 on 9 February 2023. Downloaded from http://www.jabfm.org/ on 20 April 2024 by guest. Protected by copyright.

Table 1. Results for diagnoses representing nonmelanocytic lesions (Round 1, n=33; Round 2, n=30). Responses were converted to a numerical scale with a minimum of 1, representing "strongly disagree," and a maximum of 5, representing "strongly agree."

Diagnosis (Level classification) Feature, added, ~~removed~~	**Round 1: response average**	**Round 1: % positive responses***	**Round 2: response average**	**Round 2: % positive responses***	**Round 2: comments**
Hemangioma (Level 1)					"Lacunae of any color including clear ones (lymphangioma) should be included." – **updated diagnosis to "hemangioma" to distinguish from lymphangioma and other angiomas** "I worry this may be confused for a melanoma."
Red, blue-red, red-purple, or maroon lacunae/lagoons with white septae	4.91	72.7%	—	—	
Blue-black coloring in lacunae (when thrombosed) in absence of other structures	4.03	72.7%	↓3.97	↑73.3% include	
Dermatofibroma (Level 1)					"This is an important clue to DF. Network can be seen in nevi and DF, but ring-like globules only in DF and not in nevi." – **potentially include** "Not a common enough feature to be included." – **potentially include**
Central scar-like white patch/depigmentation	4.94	100.0%	—	—	
Fine/delicate surrounding/peripheral network-like structures	4.79	100.0%	—	—	
Ring-like globules	3.97	66.7%	↓3.47	↓60.0% potentially include	
Central shiny white lines/streaks under polarized dermoscopy	4.42	84.8%	—	—	
Dotted vessels	3.27	39.4%	—	—	
Central pink blush	3.30	42.4%	—	—	
Seborrheic keratosis (Level 1)					(none)
Milia-like cysts (cloudy or starry) and comedo-like openings	4.79	93.9%	—	—	
Moth-eaten (sharply demarcated) borders	4.45	87.9%	—	—	
'Fissures and ridges' / 'gyri and sulci' / cerebriform pattern	4.70	93.9%	—	—	
Fat fingers	4.18	78.8%	—	—	
Fingerprint-like structures (parallel lines)	4.27	78.8%	—	—	
Hairpin (looped) vessels	3.97	78.8%	—	—	
Solar Lentigo (Level 1)					"Too ambiguous of term and feature for PCPs." – **potentially include** "If you want to include ink spot lentigo, then need to include network-like structures."
Moth-eaten (sharply demarcated) borders	4.58	90.9%	—	—	
Homogenous light brown pigmentation	4.52	87.9%	—	—	
Network-like structures	3.97	63.6%	↓3.57	↓63.3% potentially include	
Fingerprint-like structures (parallel lines)	4.42	90.9%	—	—	
Uniform brown perifollicular pigmentation	4.06	75.8%	—	—	
Basal Cell Carcinoma (Level 1)					"Shiny white blotches and strands / structures only visible when polarized." – **added "under polarized dermoscopy"** "Consider updating 'shiny white blotches and strands / structures' to 'multiple
Leaf-like structures/areas	4.58	90.9%	—	—	
Blue-gray ovoid nests	4.55	87.9%	—	—	
Multiple blue-gray dots and globules (buckshot scatter)	4.45	84.8%	—	—	
Spoke-wheel-like structures/areas / concentric structures	4.36	87.9%	—	—	
Ulceration / erosion	4.64	93.9%	—	—	

J Am Board Fam Med: first published as 10.3122/jabfm.2022.220143R1 on 9 February 2023. Downloaded from http://www.jabfm.org/ on 20 April 2024 by guest. Protected by copyright.

Diagnosis (Level classification) Feature, added, ~~removed~~	**Round 1: response average**	**Round 1: % positive responses***	**Round 2: response average**	**Round 2: % positive responses***	**Round 2: comments**
Shiny white blotches and strands / structures under polarized dermoscopy	4.06	69.7%	↓4.00	↑76.7% include	aggregated yellow-white globules.'"
Arborizing vessels	4.88	97.0%	—	—	**Multiple aggregated yellow-white globules:** Navarrete-Dechent C, et al. Association of multiple aggregated yellow-white globules with nonpigmented basal cell carcinoma. *JAMA Dermatol.* 2020;156(8):882-890.
Short fine telangiectasias (superficial BCC)	4.03	69.7%	↓3.63	↑70.0% include	
Actinic keratosis (Level 1)					(none)
Rosettes	4.33	81.8%	—	—	
Surface scale	4.67	97.0%	—	—	
Strawberry pattern (pink-red pseudonetwork +/- fine wavy vessels [straight or coiled] surrounding hair follicles +/- white circles with central yellow clod [targetoid hair follicles])	4.30	78.8%	—	—	
Squamous cell carcinoma (Level 1)					(none)
Yellow keratin mass / scale-crust	4.73	100.0%	—	—	
Ulceration / blood spots / hemorrhage	4.61	93.9%	—	—	
White circles ('keratin pearls')	4.48	90.9%	—	—	
Rosettes	4.15	75.8%	—	—	
Glomerular (coiled) vessels	4.42	90.9%	—	—	
Hairpin vessels	4.15	78.8%	—	—	
Sebaceous hyperplasia (Level 2)					(none)
Pale yellow lobules (popcorn-like structures) around a central follicular opening	4.82	100.0%	—	—	
Crown vessels, out of focus	4.61	90.9%	—	—	
Ink spot lentigo (Level 2)					"Haven't heard this term."
Prominent dark homogenous (uniform) reticular network	4.64	93.9%	—	—	
Chicken-wire fence	3.85	63.6%	↓3.33	↓50.0% potentially include	
Pigmented actinic keratosis (Level 2)					"Too difficult (including for us)."
Gray dots	3.82	69.7%	↓3.13	↓46.7% exclude	"Overlap with lentigo maligna makes these hard to advocate training PCPs to differentiate."
Annular-granular pattern (gray dots around follicular openings)	3.82	66.7%	↓3.37	↓53.3% potentially include	
Rosettes	4.00	75.8%	—	—	
Surface scale	4.48	90.9%	—	—	
Red pseudonetwork	3.67	57.6%	—	—	
White circles	3.48	42.4%	—	—	
Patent/evident follicles	3.67	57.6%	—	—	
Squamous cell carcinoma *in situ* (Level 2)					"Best clue to pigmented SCC."
Surface scale	4.52	87.9%	—	—	
Peripheral brown/gray dots arranged linearly (pigmented SCCIS)	3.85	60.6%	↓3.30	↓46.7% exclude	
Irregularly arranged glomerular (coiled) / dotted vessels	4.55	93.9%	—	—	
Keratoacanthoma (Level 2)					(none)
Central keratin mass	4.73	93.9%	—	—	

J Am Board Fam Med: first published as 10.3122/jabfm.2022.220143R1 on 9 February 2023. Downloaded from http://www.jabfm.org/ on 20 April 2024 by guest. Protected by copyright.

Diagnosis (Level classification) Feature, added, ~~removed~~	**Round 1: response average**	**Round 1: % positive responses***	**Round 2: response average**	**Round 2: % positive responses***	**Round 2: comments**
Hairpin (looped) or serpentine (linear-irregular) vessels, usually at the periphery, with white-yellow halo	4.52	87.9%	—	—	
Angiokeratoma (Level 2)					(none)
Red/purple/black ('dark') lacunae	4.61	93.9%	—	—	
Hemorrhagic crust	4.09	75.8%	—	—	
Lichen planus-like keratosis (Level 2)					"Too much overlap with melanoma to be differentiated by PCPs. This is not a diagnosis that most PCPs should be making on dermoscopy." "Too hard to trust a beginner to know what blue-gray-white is 'fine' and what is melanoma."
Coarse gray granularity	3.88	63.6%	↓3.40	↓53.3% potentially include	
Peppering (evenly spaced gray dots)	4.03	69.7%	↓3.60	↓63.3% potentially include	
Sharp cut-off borders (scalloped/moth-eaten)	4.06	69.7%	↓3.60	↓63.3% potentially include	
Features of a lentigo or a seborrheic keratosis in an area	4.15	72.7%	—	—	
Blue-gray/blue-white structures **(new)**	—	—	2.57	20.0% exclude	

* A positive response is defined as selection of "strongly agree" (5) or "agree" (4).

J Am Board Fam Med: first published as 10.3122/jabfm.2022.220143R1 on 9 February 2023. Downloaded from http://www.jabfm.org/ on 20 April 2024 by guest. Protected by copyright.

Table 2. Results for diagnoses representing benign melanocytic lesions (Round 1, n=33; Round 2, n=30). Responses were converted to a numerical scale with a minimum of 1, representing "strongly disagree," and a maximum of 5, representing "strongly agree."

Diagnosis (Level classification) Feature, added, ~~removed~~	**Round 1: response average**	**Round 1: % positive responses***	**Round 2: response average**	**Round 2: % positive responses***	**Round 2: comments**
Overview of benign nevi patterns (Level 1)					"But only if symmetrical." – **added "symmetric"** "'Benign' label can be misleading."
Diffuse reticular network	4.85	100.0%	—	—	
Patchy reticular network	4.70	97.0%	—	—	
Peripheral reticular network with central hypopigmentation	4.76	100.0%	—	—	
Peripheral reticular network with central hyperpigmentation	4.76	100.0%	—	—	
Peripheral reticular network with central globules	4.61	90.9%	—	—	
Homogenous (tan, brown, blue, or pink)	4.64	93.9%	—	—	
Central network with evenly distributed peripheral globules	4.55	87.9%	—	—	
Globular pattern	4.82	100.0%	—	—	
Symmetric two-component pattern	4.06	69.7%	↓3.40	↓60.0% potentially include	
Symmetric multicomponent pattern	4.15	75.8%	—	—	
Intradermal nevi (Level 1)					(none)
Comma-shaped (curved) vessels	4.58	93.9%	—	—	
Homogenous (structureless) brown/tan/pink pigmentation	4.52	93.9%	—	—	
Peripheral network	4.03	72.7%	—	—	
Globules	4.36	87.9%	—	—	
Congenital melanocytic nevi (Level 2)					"I do not use these criteria in my evaluation, therefore I would need to know the sensitivity and specificity to rate their usefulness."
Cobblestone pattern/globular pattern	4.64	93.9%	—	—	
Reticular network	4.45	90.9%	—	—	
Homogenous background pigmentation	4.45	87.9%	—	—	
Hypertrichosis	4.30	78.8%	—	—	
Perifollicular hyper-/hypo-pigmentation	4.06	69.7%	↓3.57	↓60.0% potentially include	
Central hypopigmentation **(new)**	—	—	3.10	33.3% exclude	
Blue nevi (Level 2)					(none)
Homogenous blue/blue-gray pigmentation	4.88	100.0%	—	—	
Well-circumscribed	4.67	93.9%	—	—	
Spitz nevi (Level 2)					"Spitz nevus diagnosis is tough. Not sure how detailed you want to get with PCPs. The overlap with melanoma is huge." "These features are also melanoma-specific structures and could falsely reassure someone against biopsy." "I think I would want PCP-targeted dermoscopy to recognize that if there is any veil, think melanoma and biopsy, rather than observe and monitor a Spitz nevus. I tend to
Vascular pattern (pink homogenous with dotted vessels)	4.00	75.8%	—	—	
Starburst pattern with tiered globules/streaks and regularly spaced pseudopods at the periphery (radial streaming)	4.55	87.9%	—	—	
Negative pigment network (reticular depigmentation)	3.85	60.6%	↓3.10	↓33.3% exclude	
Shiny white lines (crystalline structures)	3.82	63.6%	↓3.30	↓43.3% exclude	
Globular with negative network or blue-white veil	3.64	60.6%	↓2.70	↓23.3% exclude	

J Am Board Fam Med: first published as 10.3122/jabfm.2022.220143R1 on 9 February 2023. Downloaded from http://www.jabfm.org/ on 20 April 2024 by guest. Protected by copyright.

Diagnosis (Level classification) Feature, added, ~~removed~~	**Round 1: response average**	**Round 1: % positive responses***	**Round 2: response average**	**Round 2: % positive responses***	**Round 2: comments**
					biopsy all spitz nevi in adults. So, as long as this is clarified, I could agree to add the features above."
Recurrent/persistent nevi (Level 2)					"Most of these things are high-level, and risk of making mistake has significant implications. I would not include these as part of routine dermoscopy for PCPs."
Pigment within the scar, not extending beyond	4.30	81.8%	—	—	
Starburst pattern (radial streaming) **(new)**	—	—	2.93	33.3% exclude	
Halo nevi (Level 2)					(none)
Encircling/surrounding depigmentation/pallor	4.52	93.9%	—	—	
Central reticulation with peripheral white depigmentation	4.03	78.8%	—	—	
Benign nevi patterns, globular, homogenous	4.12	78.8%	—	—	

* A positive response is defined as selection of "strongly agree" (5) or "agree" (4).

J Am Board Fam Med: first published as 10.3122/jabfm.2022.220143R1 on 9 February 2023. Downloaded from http://www.jabfm.org/ on 20 April 2024 by guest. Protected by copyright.

Table 3. Results for diagnoses representing melanoma (Round 1, n=33; Round 2, n=30). Responses were converted to a numerical scale with a minimum of 1, representing "strongly disagree," and a maximum of 5, representing "strongly agree."

Diagnosis (Level classification) Feature, added, ~~removed~~	**Round 1: response average**	**Round 1: % positive responses***	**Round 2: response average**	**Round 2: % positive responses***	**Round 2: comments**
Overview of melanoma patterns (Level 1)					"black blotch"
Atypical pigment network	4.82	97.0%	—	—	"Atypical blotch is an off-center blotch or the presence of multiple blotches." – **changed to "blotch" to "blotch(es)"**
Blue structures (blue-white veil, blue-gray structures)	4.88	100.0%	—	—	
Shiny white lines/structures (crystalline structures)	4.76	100.0%	—	—	
Negative pigment network	4.55	87.9%	—	—	
Atypical/irregular dots/globules	4.67	93.9%	—	—	
Atypical/irregular streaks (radial streaming, pseudopods)	4.76	97.0%	—	—	
Regression structures (white scar-like area and/or peppering)	4.70	93.9%	—	—	
Peripheral brown/tan structureless area	4.21	78.8%	—	—	
Angulated lines (extrafacial) / polygons / zig-zag pattern	4.21	75.8%	—	—	
Atypical vascular pattern/structures, polymorphous vessels (2+ types of blood vessels)	4.39	87.9%	—	—	
Atypical/off-center blotch(es)	4.18	69.7%	↑ 4.33	↑ 90.0% include	
Acral melanoma *(Level 2)*					"Not familiar with this term."
Parallel ridge pattern	4.76	93.9%	—	—	
Irregular diffuse pigmentation or blotch	4.39	84.8%	—	—	
Multicomponent pattern, asymmetry of structures/colors	4.36	84.8%	—	—	
Atypical fibrillar pattern	4.15	72.7%	—	—	
Ulceration	4.58	90.9%	—	—	
Neo-vascularization, milky red	4.00	72.7%	—	—	
Pigment crossing normal ridge pattern **(new)**	—	—	3.37	46.7% exclude	
Lentigo maligna melanoma (Level 2)					"I just have never used this as a diagnostic feature."
Annular-granular pattern (gray dots around follicular openings)	4.45	90.9%	—	—	
Asymmetric pigmentation around follicular openings / asymmetric follicular openings	4.42	87.9%	—	—	
Rhomboidal structures (angulated lines) / zig-zag pattern	4.39	81.8%	—	—	
Circle within a circle (isobar)	3.94	60.6%	↓ 3.57	↓ 56.7% potentially include	
Dark blotches +/- obliterated hair follicles	4.21	75.8%	—	—	
Amelanotic/hypomelanotic melanoma (Level 2)					(none)
Scar-like depigmentation	4.21	75.8%	—	—	
Milky red areas	4.42	81.8%	—	—	
Shiny white lines (crystalline structures)	4.39	81.8%	—	—	
Atypical vascular pattern, polymorphous vessels (2+ types of blood vessels)	4.24	81.8%	—	—	

* A positive response is defined as selection of "strongly agree" (5) or "agree" (4).

J Am Board Fam Med: first published as 10.3122/jabfm.2022.220143R1 on 9 February 2023. Downloaded from http://www.jabfm.org/ on 20 April 2024 by guest. Protected by copyright.

Table 4. Results for diagnoses related to special sites (n=30). Responses were converted to a numerical scale with a minimum of 1, representing "strongly disagree," and a maximum of 5, representing "strongly agree."

Diagnosis (Level classification) Feature, added, ~~removed~~	**Round 1: response average**	**Round 1: % positive responses***	**Round 2: response average**	**Round 2: % positive responses***	**Round 2: comments**
Subungual hemorrhage (Level 1)					"Despite being for PCP-targeted dermoscopy, the homogenous coloration is subtle and definitely advanced. I worry that having too many advanced features may render an over-confidence." – **potentially include** "The lightning sign is a feature of subcorneal blood. Not sure it applies to subungual blood." – **excluded**
Well-circumscribed red-black dots or blotches / blood spots	4.58	90.9%	—	—	
Distal streaks of red-brown coloration ('filamentous' distal end)	4.27	81.8%	—	—	
Homogenous red/purple/black coloration without melanin granules	4.09	69.7%	↓3.60	↓60.0% potentially include	
Discontiguous with the cuticle (not connected to the proximal nailfold or edge of nail)	4.42	87.9%	—	—	
Lightning sign or white streaks **(new)**	—	—	2.83	20.0% exclude	
Dermoscopic features of the face (Level 2)					(none)
Pseudonetwork	4.27	78.8%	—	—	
Benign patterns of acral nevi (Level 2)					(none)
Parallel furrow pattern (with pattern variations including single line, double line, single dotted line, double-dotted line)	4.73	93.9%	—	—	
Lattice-like pattern	4.55	87.9%	—	—	
Fibrillar pattern (soles only)	4.48	84.8%	—	—	
Homogenous pattern	4.21	75.8%	—	—	
Peas in a pod pattern (parallel furrow + globules on ridges) (congenital nevi)	4.03	69.7%	↓3.40	↓56.7% potentially include	
Nevus of the nail (Level 2)					(none)
Homogenous brown background coloration	4.15	84.8%	—	—	
Uniform band thickness, color, and spacing with parallel band configuration and unbroken lines	4.24	87.9%	—	—	
Lentigo of the nail (Level 2)					"There is almost always a coincidence between light brown and gray. I would put it this way and not use the term brown. This should be reserved for melanocytic." – **changed "brown" to "light brown"**
Homogenous gray band or lines +/- gray background	4.18	78.8%	—	—	
Regular light brown lines **(new)**	—	—	3.43	60.0% potentially include	
Melanoma of the nail (Level 2)					(none)
Triangular shape of pigment band (band diameter wider at proximal end)	4.45	87.9%	—	—	
Pigmentation of periungual skin (micro-Hutchinson's sign)	4.39	90.9%	—	—	
Brown to black dots/globules associated with longitudinal lines	3.91	60.6%	↓3.27	↓50.0% potentially include	
Longitudinal brown/black broken lines with irregular spacing, width, coloration, or parallelism	4.30	81.8%	—	—	
Diagnosis (Level classification) Feature, added, ~~removed~~	**Round 1: response average**	**Round 1: % positive responses***	**Round 2: response average**	**Round 2: % positive responses***	**Round 2: comments**
Band width >3 mm or 2/3 of nail plate width	4.27	78.8%	—	—	
Talon noir (Level 2)					"Talon noir is so rare that I don't think this should be included." – **inclusion in Level 2 based on panel consensus**
Homogenous ~~or parallel-ridge~~ red-brown coloration	4.15	78.8%	—	—	
Peripheral red-brown dots/globules	4.03	66.7%	↓3.27	↓40.0% exclude	
Cracks (lightning bolt sign)	3.76	51.5%	—	—	

* A positive response is defined as selection of "strongly agree" (5) or "agree" (4).

J Am Board Fam Med: first published as 10.3122/jabfm.2022.220143R1 on 9 February 2023. Downloaded from http://www.jabfm.org/ on 20 April 2024 by guest. Protected by copyright.

Table 5. Results for other diagnoses, including skin infections and infestations (Round 1, n=33; Round 2, n=30). Responses were converted to a numerical scale with a minimum of 1, representing "strongly disagree," and a maximum of 5, representing "strongly agree."

Diagnosis (Level classification) Feature, added, ~~removed~~	**Round 1: response average**	**Round 1: % positive responses***	**Round 2: response average**	**Round 2: % positive responses***	**Round 2: comments**
Scabies (Level 1)					(none)
Delta-wing jet with contrail sign (small dark brown triangular structure located at the end of whitish structureless curved/wavy lines)	4.52	90.9%	—	—	
Verruca (Level 1)					(none)
Papilliform structures	4.67	93.9%	—	—	
Tiny red-black dots (papillary capillaries)	4.61	90.9%	—	—	
Molluscum contagiosum (Level 2)					"Crown vessels in this case should also be distinguished from similar non-molluscum lesions (i.e. sebaceous hyperplasia), thus presenting this finding needs to be contrasted with a similar appearing lesion."
Central pore or umbilication	4.61	93.9%	—	—	
Polylobular white-yellow amorphous structures	4.27	81.8%	—	—	
Linear or branched vessels (red corona) / crown vessels	3.97	63.6%	↓3.63	↓63.3% potentially include	
Venous lake (Level 2)					(none)
Homogenous purple/ blue/red coloration +/- globules/clods	4.61	93.9%	—	—	
Psoriasis (Level 2)					(none)
Red or pink color with white scales / light red background	4.03	75.8%	—	—	
Dotted vessels in a regular distribution	4.03	72.7%	—	—	
Twisted red loops in a homogenous distribution	3.42	45.5%	—	—	
Glomerular vessels	3.42	45.5%	—	—	
Radiation tattoo (Level 2)					(none)
Homogenous blue or black coloration	4.33	84.8%	—	—	
Scars (Level 2)					(none)
Arborizing, linear irregular, or comma vessels in keloids	3.58	45.5%	—	—	
White depigmentation	4.00	72.7%	—	—	

* A positive response is defined as selection of "strongly agree" (5) or "agree" (4).

J Am Board Fam Med: first published as 10.3122/jabfm.2022.220143R1 on 9 February 2023. Downloaded from http://www.jabfm.org/ on 20 April 2024 by guest. Protected by copyright.

IV. Conclusion

In closing, the research team greatly appreciates all panelists' time and effort in participating in this process. Panelists who completed Round 2 of the features survey series will be invited to review the final study manuscript and included as a co-author for publication.

If you have any questions or comments related to this study or your rights as a research participant, please e-mail Tiffaney Tran at [redacted].

J Am Board Fam Med: first published as 10.3122/jabfm.2022.220143R1 on 9 February 2023. Downloaded from http://www.jabfm.org/ on 20 April 2024 by guest. Protected by copyright.

Foundational Dermoscopy Proficiency (Level 1)

Nonmelanocytic Lesions (Level 1)

Hemangioma

- Red, blue-red, red-purple, or maroon lacunae/lagoons with white septae
- Blue-black coloring in lacunae (when thrombosed) in absence of other structures

Seborrheic keratosis

- Milia-like cysts (cloudy or starry) and comedo-like openings
- "Fissures and ridges" / "gyri and sulci" / cerebriform pattern
- Moth-eaten (sharply demarcated) borders
- Fat fingers
- Fingerprint-like structures (parallel lines)
- Hairpin (looped) vessels

Dermatofibroma

- Central scar-like white patch/depigmentation
- Fine/delicate surrounding/peripheral network-like structures
- Central shiny white lines/streaks under polarized dermoscopy
- *(optional to include)* Ring-like globules

Solar lentigo

- Moth-eaten (sharply demarcated) borders
- Fingerprint-like structures (parallel lines)
- Homogenous light brown pigmentation
- Uniform brown perifollicular pigmentation
- *(optional to include)* Network-like structures

Basal cell carcinoma

- Arborizing vessels
- Ulceration / erosion
- Leaf-like structures/areas
- Blue-gray ovoid nests
- Spoke-wheel-like structures/areas / concentric structures
- Multiple blue-gray dots and globules (buckshot scatter)
- Shiny white blotches and strands / structures under polarized dermoscopy
- Short fine telangiectasias (superficial BCC)

Finding the Right Scope | Dermoscopy for Primary Care Working Group

J Am Board Fam Med: first published as 10.3122/jabfm.2022.220143R1 on 9 February 2023. Downloaded from http://www.jabfm.org/ on 20 April 2024 by guest. Protected by copyright.

Squamous cell carcinoma

- Yellow keratin mass / scale-crust
- Ulceration / blood spots / hemorrhage
- White circles ("keratin pearls")
- Glomerular (coiled) vessels
- Rosettes
- Hairpin vessels

Actinic keratosis

- Surface scale
- Rosettes
- Strawberry pattern (pink-red pseudonetwork +/- fine wavy vessels [straight or coiled] surrounding hair follicles +/- white circles with central yellow clod [targetoid hair follicles])

Benign Melanocytic Lesions (Level 1)

Overview of benign nevi patterns

- Diffuse reticular network
- Peripheral reticular network with central hypopigmentation
- Peripheral reticular network with central hyperpigmentation
- Globular pattern
- Patchy reticular network
- Homogenous (tan, brown, blue, or pink)
- Peripheral reticular network with central globules
- Central network with evenly distributed peripheral globules
- Symmetric multicomponent pattern
- *(optional to include)* Symmetric two-component pattern

Intradermal nevi

- Comma-shaped (curved) vessels
- Homogenous (structureless) brown/tan/pink pigmentation
- Peripheral network
- Globules

Finding the Right Scope | Dermoscopy for Primary Care Working Group

J Am Board Fam Med: first published as 10.3122/jabfm.2022.220143R1 on 9 February 2023. Downloaded from http://www.jabfm.org/ on 20 April 2024 by guest. Protected by copyright.

Melanoma (Level 1)

Overview of melanoma patterns

- Blue structures (blue-white veil, blue-gray structures)
- Shiny white lines/structures (crystalline structures)
- Atypical pigment network
- Atypical/irregular streaks (radial streaming, pseudopods)
- Atypical/irregular dots/globules
- Regression structures (white scar-like area and/or peppering)
- Negative pigment network
- Atypical vascular pattern/structures, polymorphous vessels (2+ types of blood vessels)
- Peripheral brown/tan structureless area
- Angulated lines (extrafacial) / polygons / zig-zag pattern
- Atypical/off-center blotch(es)

Special Sites (Level 1)

Subungual hemorrhage

- Well-circumscribed red-black dots or blotches / blood spots
- Discontiguous with the cuticle (not connected to the proximal nailfold or edge of nail)
- Distal streaks of red-brown coloration ('filamentous' distal end)
- *(optional to include)* Homogenous red/purple/black coloration without melanin granules

Other (Level 1)

Verruca

- Papilliform structures
- Tiny red-black dots (papillary capillaries)

Scabies

- Delta-wing jet with contrail sign (small dark brown triangular structure located at the end of whitish structureless curved/wavy lines)

Finding the Right Scope | Dermoscopy for Primary Care Working Group

J Am Board Fam Med: first published as 10.3122/jabfm.2022.220143R1 on 9 February 2023. Downloaded from http://www.jabfm.org/ on 20 April 2024 by guest. Protected by copyright.

Intermediate Dermoscopy Proficiency (Level 2)

Nonmelanocytic Lesions (Level 2)

Sebaceous hyperplasia

- Pale yellow lobules (popcorn-like structures) around a central follicular opening
- Crown vessels, out of focus

Pigmented actinic keratosis

- Surface scale
- Rosettes
- *(optional to include)* Annular-granular pattern (gray dots around follicular openings)
- *(optional to include)* Red pseudonetwork
- *(optional to include)* Patent/evident follicles

Squamous cell carcinoma *in situ*

- Irregularly arranged glomerular (coiled) / dotted vessels
- Surface scale

Keratoacanthoma

- Central keratin mass
- Hairpin (looped) or serpentine (linear-irregular) vessels, usually at the periphery, with white-yellow halo

Angiokeratoma

- Red/purple/black ("dark") lacunae
- Hemorrhagic crust

Lichen planus-like keratosis

- Features of a lentigo or seborrheic keratosis in an area
- *(optional to include)* Peppering (evenly spaced gray dots)
- *(optional to include)* Sharp cut-off borders (scalloped/moth-eaten)
- *(optional to include)* Coarse gray granularity

Ink spot lentigo

- Prominent dark homogenous (uniform) reticular network
- *(optional to include)* Chicken-wire fence

Finding the Right Scope | Dermoscopy for Primary Care Working Group

J Am Board Fam Med: first published as 10.3122/jabfm.2022.220143R1 on 9 February 2023. Downloaded from http://www.jabfm.org/ on 20 April 2024 by guest. Protected by copyright.

Benign Melanocytic Lesions (Level 2)

Blue nevi

- Homogenous blue/blue-gray pigmentation
- Well-circumscribed lesion

Spitz nevi

- Starburst pattern with tiered globules/streaks and regularly spaced pseudopods at the periphery (radial streaming)
- Vascular pattern (pink homogenous with dotted vessels)

Congenital melanocytic nevi

- Cobblestone pattern/globular pattern
- Reticular network
- Homogenous background pigmentation
- Hypertrichosis
- *(optional to include)* Perifollicular hyper-/hypo-pigmentation

Halo nevi

- Encircling/surrounding depigmentation/pallor
- Central reticulation with peripheral white depigmentation
- Benign nevi patterns, globular, homogenous

Melanoma (Level 2)

Acral melanoma

- Parallel ridge pattern
- Ulceration
- Irregular diffuse pigmentation or blotch
- Multicomponent pattern, asymmetry of structures/colors
- Atypical fibrillar pattern
- Neo-vascularization, milky red

Lentigo maligna melanoma

- Annular-granular pattern (gray dots around follicular openings)
- Asymmetric pigmentation around follicular openings / asymmetric follicular openings
- Rhomboidal structures (angulated lines) / zig-zag pattern
- Dark blotches +/- obliterated hair follicles
- *(optional to include)* Circle within a circle (isobar)

Finding the Right Scope | Dermoscopy for Primary Care Working Group

J Am Board Fam Med: first published as 10.3122/jabfm.2022.220143R1 on 9 February 2023. Downloaded from http://www.jabfm.org/ on 20 April 2024 by guest. Protected by copyright.

Melanoma of the nail

- Pigmentation of periungual skin (micro-Hutchinson's sign)
- Triangular shape of pigment band (band diameter wider at proximal end)
- Longitudinal brown/black broken lines with irregular spacing, width, coloration, or parallelism
- Band width >3 mm or 2/3 of nail plate width
- *(optional to include)* Brown to black dots/globules associated with longitudinal lines

Amelanotic/hypomelanotic melanoma

- Milky red areas
- Shiny white lines (crystalline structures)
- Atypical vascular pattern, polymorphous vessels (2+ types of blood vessels)
- Scar-like depigmentation

Special Sites (Level 2)

Dermoscopic features of the face

- Pseudonetwork

Benign patterns of acral nevi

- Parallel furrow pattern (with pattern variations including single line, double line, single dotted line, double-dotted line)
- Lattice-like pattern
- Fibrillar pattern (soles only)
- Homogenous pattern
- *(optional to include)* Peas-in-a-pod pattern (parallel furrow + globules on ridges) (acral congenital melanocytic nevi)

Nevus of the nail

- Uniform band thickness, color, and spacing with parallel band configuration and unbroken lines
- Homogenous brown background coloration

Lentigo of the nail

- Homogenous gray band or lines +/- gray background
- *(optional to include)* Regular light brown lines

Talon noir

- Homogenous red-brown coloration
- *(optional to include)* Cracks (lightning bolt sign)

Finding the Right Scope | Dermoscopy for Primary Care Working Group

J Am Board Fam Med: first published as 10.3122/jabfm.2022.220143R1 on 9 February 2023. Downloaded from http://www.jabfm.org/ on 20 April 2024 by guest. Protected by copyright.

Other (Level 2)

Molluscum contagiosum

- Central pore or umbilication
- Polylobular white-yellow amorphous structures
- *(optional to include)* Linear or branched vessels (red corona) / crown vessels

Radiation tattoo

- Homogenous blue or black coloration

Scars

- White depigmentation

Venous lake

- Homogenous purple/blue/red coloration +/- globules/clods

Psoriasis

- Red or pink color with white scales / light red background
- Dotted vessels in a regular distribution

Finding the Right Scope | Dermoscopy for Primary Care Working Group

J Am Board Fam Med: first published as 10.3122/jabfm.2022.220143R1 on 9 February 2023. Downloaded from http://www.jabfm.org/ on 20 April 2024 by guest. Protected by copyright.