Diagnosis and Management of Plantar Dermatoses

Cody J. Rasner, MS, Sara A. Kullberg, MD, David R. Pearson, MD, and Christina L. Boull, MD

Plantar dermatoses (PD) are common, occurring either spontaneously on healthy skin or developing secondarily from previously established foot disease. PD share similar symptoms and morphology, making them challenging to differentiate. A few of the most frequently encountered PD include tinea pedis, psoriasis, contact dermatitis, dyshidrotic dermatitis (or recurrent vesicular palmoplantar dermatitis), and juvenile plantar dermatosis. This review offers practical advice for diagnosing and treating the most common PD in the primary care office. (J Am Board Fam Med 2022;35:435–442.)

Keywords: **Dermatitis, Dermatology, Family Medicine, Primary Health Care, Psoriasis, Tinea Pedis, Workplace**

Introduction

Inflammatory skin conditions frequently affect the plantar feet (ie, plantar dermatoses [PD]), often first presenting in primary care clinics. While most PDs are a mild nuisance, severe forms cause substantial morbidity with reduced mobility, physical discomfort, and employment limitations, leading to a demonstrable reduction in quality-of-life measures.[1–4] PD pose diagnostic and treatment challenges as eruptions may share similar clinical features yet require distinct treatments (Table 1). As they are likely the principal point of contact for affected patients, primary care providers play a pivotal role in the diagnosis and management of PD. In this review, we discuss diagnostic symptoms, therapeutics, and indications for referral for the most common PD.

Tinea Pedis

Clinical Features

Tinea pedis (Figure 1), or "athlete's foot," is the most common plantar dermatosis affecting nearly 3% of adults.[5] Tinea pedis is most prevalent in males aged 31 to 60 years and is acquired through direct contact with dermatophytes that are often transferred in sites, such as bathrooms, gyms, and swimming pool areas, and flourish in the warm damp environments created by occlusive footwear.[6]

Itching and burning are typical symptoms. Skin maceration, peeling, and white scale is often asymmetrical in distribution. The interdigital subtype is most common, favoring web spaces of the fourth and fifth toes. Conversely, a "moccasin distribution" presents with superficial, desquamative scaling (or fine and powdery) diffusely over the soles and lateral feet. The leading edge of the eruption may be slightly raised and annular or arcuate. With bullous tinea, tense vesicles, bullae, and/or pustules favor the instep. Sometimes, bullous tinea may seem purpuric, mimicking vasculitis.[5] Onychomycosis often co-occurs with tinea and may be a diagnostic clue.

Erythrasma (corynebacterial infection) is a clinical mimic of tinea with maceration in the web spaces, but illumination with a Wood's lamp (365 nm) reveals the characteristic coral-red fluorescence of *Corynebacteria*.

Testing

Skin scraping with potassium hydroxide (KOH) provides a definitive diagnosis. If unavailable, a fungal culture should be collected by scraping the leading edge of the scale into a sterile container. Pathogenic species include *Trichophyton* and *Epidermophyton*. Feet often harbor soil contaminants, so the growth of molds does not indicate infection.

This article was externally peer reviewed.
Submitted 3 August 2020; revised 30 August 2021; accepted 28 September 2021.
From the University of Minnesota Medical School, Minneapolis (CR, SK, DRP, CLB); Department of Dermatology, University of Minnesota, Minneapolis (SK, DRP, CLB).
Funding: No governmental or non-governmental funding was obtained or used for this study.
Conflict of interests: None.
Corresponding author: Christina L. Boull, MD, 516 Delaware St SE, MMC 98, Minneapolis, MN 55455 (E-mail: oehr0005@umn.edu).

J Am Board Fam Med: first published as 10.3122/jabfm.2022.02.200410 on 4 April 2022. Downloaded from http://www.jabfm.org/ on 18 April 2024 by guest. Protected by copyright.

Table 1. Common Plantar Dermatoses

Diagnosis	Clinical Features	Ancillary Tests	Initial Therapy
Tinea Pedis	*Onset:* 31 to 60 years of age *Distribution:* Asymmetrical, 4th–5th web space; in-step or "moccasin distribution" *Morphology:* Fissuring, maceration, herpetiform vesicles, pustules, and bullae with pink base *Symptoms:* Itch, pain, burning *Clinical clues:* Concurrent onychomycosis	KOH Preparation or fungal culture	*Topical:* First-line: Terbinafine 1% cream, butenafine 1% cream, naftifine 1% cream Other: econazole 1% cream *Oral*: terbinafine 250 mg daily
Erythrasma	*Onset:* Increased prevalence with age *Distribution:* Often involves web spaces of 3rd–5th toes *Morphology:* Well-marginated pink, brown patches *Symptoms:* Asymptomatic or mild itch	Illumination with Wood's lamp reveals coral-red fluorescence	*Topical:* Clindamycin solution, erythromycin gel, or benzoyl peroxide wash *Oral:*Clindamycin, macrolides, or tetracyclines
Psoriasis *(plaque* vs. *pustular)*	***Plaque:*** *Onset:* Late teens or 55 to 60 years of age *Distribution:* Bilateral, symmetric, dorsal, or plantar feet. *Morphology: W*ell-demarcated pink scaly plaques *Symptoms:* Asymptomatic or painful itch ***Pustular:*** *Onset:* 45 to 65 years of age *Distribution:* widespread or limited to palms and soles *Morphology:* Sterile pustules on an erythematous background, fissures *Symptoms:* Pain, burning, itch *Other clues:* Nail pitting or distal onycholysis; Pink plaques on the scalp, umbilicus, gluteal cleft, elbows/knees	Clinical diagnosis in most cases Consider biopsy, though it may not be diagnostic	*Topical:* Mid- to high-potency topical steroids, topical vitamin D analogs (eg, calcipotriene) *Systemic:* Methotrexate, cyclosporine, acitretin, biologic agents*Other:* Phototherapy
Contact Dermatitis *Allergic (ACD)* *Irritant (ICD)*	***Allergic Contact Dermatitis (ACD):*** *Onset:* 8 to 28 days post-exposure *Distribution:* Symmetrical or asymmetrical, geometric *Morphology: Acute:* oozing/weeping pink papules, vesicles, and plaques *Chronic:* dry scaling and fissuring *Symptoms:* Itch ***Irritant Contact Dermatitis (ICD):*** *Onset:* Minutes to hours *Distribution:* geometric *Morphology:* *Acute:* red indurated plaques, vesicles, ulcers *Chronic:* dry scaling and fissures *Symptoms:* Pain and burning	Patch testing (definitive diagnosis for ACD)	Thorough removal of the irritant (for ICD) Avoidance of allergens and irritants Hypoallergenic fragrance-free soaps and emollients Mid- to high-potency topical steroids
Dyshidrotic Dermatitis	*Onset:* Recurrent crops in summer and winter *Distribution:* Symmetrical on the in-step and lateral toes *Morphology:* 1-mm to 2–mm deep vesicles; "tapioca-like." Resolution with halo-shaped desquamation and brown circular crusts *Symptoms:* Severe itch	Clinical diagnosis	Avoidance of harsh soaps and irritants Liberal use of hypoallergenic emollients Mid to high-potency topical steroids

Continued

J Am Board Fam Med: first published as 10.3122/jabfm.2022.02.200410 on 4 April 2022. Downloaded from http://www.jabfm.org/ on 18 April 2024 by guest. Protected by copyright.

Table 1. Continued

Diagnosis	Clinical Features	Ancillary Tests	Initial Therapy
Juvenile Plantar Dermatosis (JPD)	*Onset:* Young, school-aged children *Distribution:* Originating from the base of the big toe, sparing web spaces *Morphology:* Redness, fissures, scaling, "glazed donut" appearance *Symptoms:* Itch	Clinical diagnosis	Avoid occlusive footwear and change socks frequently Thick, bland emollients Mid- to high-potency topical steroids

Abbreviations: ACD, Allergic contact dermatitis; CD, contact dermatitis; DD, dyshidrotic dermatitis; ICD, irritant contact dermatitis; JPD, juvenile plantar dermatosis; KOH, potassium hydroxide; PD, plantar dermatoses; PPP, palmoplantar psoriasis.

Therapy

Topical terbinafine 1% cream (or other allylamine antifungals including butenafine and naftifine) are effective first-line fungicidal agents.[7] Topical azoles like econazole may be considered. In severe cases or with concurrent onychomycosis, oral terbinafine is preferred.

Additional Considerations

Tinea is exceptionally common and mimics many of the other PD. It should always be excluded as a cause of foot rash before initiating therapy.

Dermatitis may improve with topical antifungals due to their moisturizing and anti-inflammatory properties. Tinea pedis is often challenging to control and may recur after cessation of therapy; however, dermatitis should be considered in recurrent rashes, particularly those with a negative KOH scraping and/or fungal culture.

Initial improvement with the use of a topical steroid does not exclude tinea. Topical steroids may decrease itch and eliminate overlying scale, producing "tinea incognita."

Psoriasis

Clinical Features

Plaque and pustular psoriasis may preferentially target the feet.[4,8,9] Many patients experience itch and severe pain from fissuring. Psoriasis has a bimodal age distribution, presenting in the late teens or between ages 55 to 60 years.[10] Psoriasis should not be overlooked as a cause of PD in children.

Figure 1. Tinea Pedis and Bullous Tinea. Tinea pedis often affects the webspace between toes 4 and 5 (A) and can present in a "moccasin distribution" characterized by superficial, desquamative scaling over the soles and lateral foot (B). Tinea incognito (C) is characterized by decreased itch and elimination of overlying scale that occurs after use of topical steroids, but tinea infection persists unless treated with proper antifungal therapy. Bullous tinea (D) characteristically develops as large superficial bullae over the in-step area.

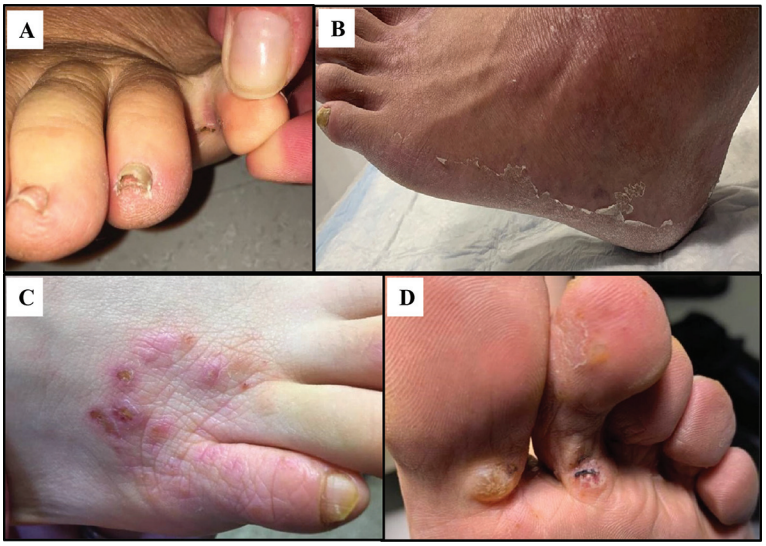

J Am Board Fam Med: first published as 10.3122/jabfm.2022.02.200410 on 4 April 2022. Downloaded from http://www.jabfm.org/ on 18 April 2024 by guest. Protected by copyright.

Palmoplantar psoriasis (PPP) classically presents as bilateral, symmetrical red-pink plaques with sharp borders. As shown in Figure 2, plaques extend up the lateral or medial aspects of the feet and may involve the dorsal foot or toes. The overlying scale can be thick with deep fissures.[8]

Palmoplantar pustular psoriasis is a rare variant in which sterile pustules form over the palms and soles.[4]

Features favoring PPP over dermatitis or tinea include the presence of scaling plaques in other psoriasis-prone areas (eg, umbilicus, gluteal cleft, scalp, palms) and psoriatic nail changes (eg, pitting, distal onycholysis).[11] Itch is more typical of dermatitis and tinea than of psoriasis, but this is not universal. Oozing of the skin with serous drainage and/or secondary infection would suggest dermatitis over psoriasis.[9]

Patients often self-treat with over-the-counter agents before presenting to the clinic. If adequate topical antifungal agents have been tried and failed, tinea is an unlikely diagnosis.

Testing

Tinea must first be excluded. Skin biopsies have limited use as PPP and dermatitis exhibit histologic similarities that can be challenging to distinguish.[12] Initial treatment options for plantar dermatitis and psoriasis are similar; therefore, additional testing may be reserved for patients unresponsive to topical corticosteroids.

Figure 2. Psoriasis Vulgaris. Psoriasis vulgaris cases of the plantar feet often present with thick overlying scale and deep fissures. Psoriasis vulgaris may affect the plantar surfaces as well as other psoriasis-prone areas such as the umbilicus, gluteal cleft, scalp, and palms.

J Am Board Fam Med: first published as 10.3122/jabfm.2022.02.200410 on 4 April 2022. Downloaded from http://www.jabfm.org/ on 18 April 2024 by guest. Protected by copyright.

Therapy

High-potent to ultrapotent topical steroids (eg, augmented betamethasone (often the most cost-effective), clobetasol, or halobetasol) are the first-line treatment for PPP, as thicker acral sites are often unresponsive to lower-potency formulations.[12–14] Topical vitamin D analogs (eg, calcipotriene) and topical retinoids (eg, tretinoin, tazarotene) are useful adjuncts.[15] The application of medications on damp skin ("soak and smear") or under occlusion with damp socks or plastic wrap can greatly enhance penetration.

Consider dermatology referral in cases refractory to topical therapies. Second-line treatments include phototherapy and systemic retinoids. In recalcitrant cases or in those with concurrent psoriatic arthritis, systemic immunomodulators (eg, methotrexate, cyclosporine) and injectable biologic agents are utilized.[4,14–16]

Contact Dermatitis

Clinical Features

Contact dermatitis arises from skin irritation or allergy.[17] Allergic contact dermatitis (ACD) and irritant contact dermatitis (ICD) are estimated to affect 4% of the United States population.[18] ICD is more prevalent, accounting for 80% of all occupational-related CD compared with 20% for ACD.[19] Aging populations and atopic individuals are at risk of ICD (and ACD with atopy) due to skin barrier dysfunction.[19]

Direct chemical irritation induces ICD. ACD results from immune sensitization following allergen-skin contact, reproducible with subsequent skin exposure. ACD develops 8 to 28 days after initial exposure, which complicates the identification of the allergen.[20] Repetitive exposure may trigger immune sensitization at any time.[21–23] Common foot allergens include shoe materials (eg, rubber accelerators, dyes, adhesives, metals of buckles/decoration).[16] Over-the-counter topical medications (eg, antibiotics, antifungals, steroids) all may provoke ACD.[17]

Well-demarcated, geometric lesions are present in acute ACD and ICD. In acute ICD, skin redness and edema localizes to the exposed area within minutes to hours. Necrotic ulcers may form in severe ICD, but not ACD.[19] ICD management includes removal of the irritant and standard wound care (eg, gentle cleansing, application of bland emollient ointment, covering to prevent infection).

Acute ACD presents with delayed onset of indurated pink plaques over areas of contact (Figure 3). In severe cases, vesiculation and bullae are present. Itch is the primary symptom of ACD, whereas burning and pain are more likely with ICD.[19]

Chronic forms of ACD and ICD are difficult to differentiate, both presenting with itching pink

Figure 3. Allergic Contact Dermatitis. Allergic contact dermatitis (ACD) develops from immune sensitization, often after repeated exposure to the offending agent. Pictured here are hallmark manifestations of ACD, characterized as indurated pink plaques with eruption of vesicles and small bullae. The offending agent, in this case, was rubber components of this individual's shoes.

J Am Board Fam Med: first published as 10.3122/jabfm.2022.02.200410 on 4 April 2022. Downloaded from http://www.jabfm.org/ on 18 April 2024 by guest. Protected by copyright.

Figure 4. Dyshidrotic Dermatitis. Dyshidrotic dermatitis presents as crops of 1 to 2 mm deep vesicles primarily localized over the lateral and medial aspects of the soles and toes. After 2 to 3 weeks, the vesicles resolve with circular collarettes of scale and brown crust.

plaques, xerosis, and fissuring. A detailed exposure history may help to discern these entities.[19]

Testing

In chronic, recurrent, or recalcitrant cases, dermatology referral for patch testing is encouraged.[23,24] Patch testing identifies cutaneous delayed hypersensitivity reactions.

Treatment

Exposures as infrequent as monthly can perpetuate ACD; therefore, assessing all potential allergens is critical. Skin eruptions may align with shoe components (eg, straps from sandals, hardware, glued seams). Yellow crusting and oozing indicate a secondary bacterial infection which should be treated with topical or oral antibiotics in conjunction with mid- to high-potent topical steroids to minimize inflammation.

Patients with sweat-induced ICD are encouraged to wear moisture-wicking socks and avoid occlusive shoes.[19] Consistent use of hypoallergenic emollients aid in skin barrier enhancement.

Dyshidrotic Dermatitis

Clinical Features

Dyshidrotic dermatitis (DD) may develop as early as preschool and is commonly provoked by cold, dry weather.[25] Crops of 1 to 2 mm "tapioca-like" deep vesicles erupt on the lateral and medial aspects of the soles and toes (Figure 4). Vesicles resolve over 2 to 3 weeks with circular collarettes of scale and brown crust. Frequently, the palms and lateral aspect of fingers are also involved. Despite severe itch, the base of the lesions is not erythematous.[25–27]

Bullous tinea, a clinical mimic, is also seen on the in-step area, but these vesicles tend to be larger and more superficial than DD.

Treatment

Routine use of thick, bland emollients with mid- to high-potency topical steroids are, again, first-line treatment.[25–27]

Juvenile Plantar Dermatosis (JPD)

Clinical Features

JPD impacts school-aged children (males>females), spontaneously resolving during early teen years. Flares occur in both summer and winter, precipitated by sweating due to hot, humid weather or occlusive boots. [28–30]

Initially, desquamation occurs at the base of the great toe (Figure 5), revealing pink-red patches with a glossy or "glazed" appearance that expand posteriorly along the forefoot. [28,29] Hyperkeratosis and fissures form over weight-bearing regions, allowing bacteria to infiltrate. Over time, the epidermal ridges

Figure 5. Juvenile Plantar Dermatosis. Juvenile plantar dermatoses present as desquamation arising at the base of the great toe with pink-red patches that have a glossy or "glazed" appearance. Hyperkeratosis and fissures will form over the weight-bearing regions. Web spaces are not classically involved.

J Am Board Fam Med: first published as 10.3122/jabfm.2022.02.200410 on 4 April 2022. Downloaded from http://www.jabfm.org/ on 18 April 2024 by guest. Protected by copyright.

flatten, resulting in anhidrosis.[31,32] Classically, web spaces are not involved.[28–30] JPD is often misdiagnosed as a dermatophyte infection, which is uncommon in children.

Treatment

Patients should avoid occlusive shoes and change out sweaty socks. Petrolatum-based emollients applied under socks can greatly improve symptoms. Topical steroids can alleviate inflammation and pain.[28]

Concluding Recommendations

PD can be effectively diagnosed and treated in the primary care clinic in most cases. Diagnostic exclusion of tinea is the most important first step in making a treatment plan because topical anti-inflammatory agents may potentiate fungal infection. Referral to dermatology should be considered when skin biopsy, patch testing, or systemic treatments are required.

Erin Warshaw, MD, MS (Minneapolis, MN), graciously provided clinical images of allergic contact dermatitis.

To see this article online, please go to: http://jabfm.org/content/35/2/435.full.

References

1. Hsu AR, Hsu JW. Topical review: skin infections in the foot and ankle patient. Foot Ankle Int 2012;33:612–9.
2. Flint WW, Cain JD. Nail and skin disorders of the foot. Med Clin North Am 2014;98:213–25.
3. Pettey AA, Balkrishnan R, Rapp SR, Fleischer AB, Feldman SR. Patients with palmoplantar psoriasis have more physical disability and discomfort than patients with other forms of psoriasis: implications for clinical practice. J Am Acad Dermatol 2003;49:271–5.
4. Obeid G, Do G, Kirby L, Hughes C, Sbidian E, Le Cleach L. Interventions for chronic palmoplantar pustulosis. Cochrane Skin Group, ed. Cochrane Database Syst Rev; 2020.
5. Ilkit M, Durdu M. Tinea pedis: The etiology and global epidemiology of a common fungal infection. Crit Rev Microbiol 2015;41:374–88.
6. Woo TE, Somayaji R, Haber RM, Parsons L. Diagnosis and management of cutaneous tinea infections. Adv Skin Wound Care 2019;32:350–7.
7. Rotta I, Ziegelmann PK, Otuki MF, Riveros BS, Bernardo NLMC, Correr CJ. Efficacy of topical antifungals in the treatment of dermatophytosis: a mixed-treatment comparison meta-analysis involving 14 treatments. JAMA Dermatol 2013;149:341–9.
8. Menter A, Strober BE, Kaplan DH, et al. Joint AAD-NPF guidelines of care for the management and treatment of psoriasis with biologics. J Am Acad Dermatol 2019;80:1029–72.
9. Murakami M, Terui T. Palmoplantar pustulosis: current understanding of disease definition and pathomechanism. J Dermatol Sci 2020;98:13–9.
10. Smith AE, Kassab JY, Payne R, Beer WE. Bimodality in age of onset of psoriasis, in both patients and their relatives. Dermatology 1993;186:181–6.
11. Kaul S, Singal A, Grover C, Sharma S. Clinical and histological spectrum of nail psoriasis: a cross-sectional study. J Cutan Pathol 2018;45:824–30.
12. Aydin O, Engin B, Oğuz O, İlvan Ş, Demirkesen C. Non-pustular palmoplantar psoriasis: is histologic differentiation from eczematous dermatitis possible? J Cutan Pathol 2008;35:169–73.
13. Farley E, Masrour S, McKey J, Menter A. Palmoplantar psoriasis: a phenotypical and clinical review with introduction of a new quality-of-life assessment tool. J Am Acad Dermatol 2009;60:1024–31.
14. Sarma N. Evidence and suggested therapeutic approach in psoriasis of difficult-to-treat areas: palmoplantar psoriasis, nail psoriasis, scalp psoriasis, and intertriginous psoriasis. Indian J Dermatol 2017;62:113–22.
15. Spuls P, Hadi S, Rivera L, Lebwohl M. Retrospective analysis of the treatment of psoriasis of the palms and soles. J Dermatol Treat 2003;14:21–5.
16. Benjegerdes KE, Hyde K, Kivelevitch D, Mansouri B. Pustular psoriasis: pathophysiology and current treatment perspectives. PTT 2016;6:131–44.
17. Shackelford KE, Belsito DV. The etiology of allergic-appearing foot dermatitis: a 5-year retrospective study. J Am Acad Dermatol 2002;47:715–21.
18. Owen JL, Vakharia PP, Silverberg JI. The role and diagnosis of allergic contact dermatitis in patients with atopic dermatitis. Am J Clin Dermatol 2018;19:293–302.
19. Cohen D. Irritant contact dermatitis. In: *Dermatology*. Fourth. Elsevier Limited; 2018. https://www-clinicalkey-com.ezp3.lib.umn.edu/#!/content/3-s2.0-B9780702062759000155?scrollTo=%23c00015&indexOverride=GLOBAL.
20. Vlahovic TC. Diagnosis and treatment options for inflammatory skin conditions of the lower extremity. Clin Podiatr Med Surg 2019;36:685–94.
21. Matthys E, Zahir A, Ehrlich A. Shoe allergic contact dermatitis. Dermatitis 2014;25:163–71.
22. Freeman S. Shoe dermatitis. Contact Dermatitis 1997;36:247–51.
23. Bangash HK, Petronic-Rosic V. Acral manifestations of contact dermatitis. Clin Dermatol 2017;35:9–18.
24. Ortiz-Salvador J-M, Esteve-Martínez A, García-Rabasco A, Subiabre-Ferrer D, Martínez-Leboráns L, Zaragoza-Ninet V. Dermatitis of the foot:

J Am Board Fam Med: first published as 10.3122/jabfm.2022.02.200410 on 4 April 2022. Downloaded from http://www.jabfm.org/ on 18 April 2024 by guest. Protected by copyright.

epidemiologic and clinical features in 389 children. Pediatr Dermatol 2017;34:535–9.

25. Scotelaro-Alves HG, Fernandes NC, Ramos-E-Silva M. Clinical profile of recurrent vesicular palmoplantar dermatitis in children and adolescents. *Clin*. CCID 2019;12:23–8.
26. Lofgren SM, Warshaw EM. Dyshidrosis: epidemiology, clinical characteristics, and therapy. Dermatitis 2006;17:https://journals.lww.com/dermatitis/Fulltext/2006/12000/Dyshidrosis__Epidemiology,_Clinical.2.aspx.
27. Brzeziński P, Martini LA. Phytotherapeutic approach to hand and feet dyshidrosis using vegetables (especially mashed celeriac applied topically); 2019.
28. Shipley DR, Kennedy CTC. Juvenile plantar dermatosis responding to topical tacrolimus ointment. Clin Exp Dermatol 2006;31:453–4.
29. Ashton RE, Jones RR, Griffiths A. Juvenile plantar dermatosis. A clinicopathologic study. Arch Dermatol 1985;121:225–8.
30. Van Diggelen MW, Van Dijk EW, Hausman RW. The enigma of juvenile plantar dermatosis. Am J Dermatopathol 1986;8:336–40.
31. Verbov JL. Juvenile plantar dermatosis. Br J Dermatol 1979;101:733.
32. Graham RM, Verbov JL, Vickers CFH. Juvenile plantar dermatosis. Clin Exp Dermatol 1987;12:468–469.

J Am Board Fam Med: first published as 10.3122/jabfm.2022.02.200410 on 4 April 2022. Downloaded from http://www.jabfm.org/ on 18 April 2024 by guest. Protected by copyright.