

BRIEF REPORT

When Is Fluid in the Mastoid Cells a Worrisome Finding?

Michael H. McDonald, MD, Matthew R. Hoffman, BS, and Lindell R. Gentry, MD

Mastoiditis is a common clinical entity that is technically present in all cases of otitis media; only a minority of cases actually represents the otolaryngologic emergency of acute coalescent mastoiditis. When reviewing an image with a radiologic diagnosis of mastoiditis, looking for key signs such as destruction of bony septa and considering patient presentation can help distinguish mild mastoiditis from acute coalescent mastoiditis. (J Am Board Fam Med 2013;26:218–220.)

Keywords: Mastoid, Mastoiditis, Otolaryngology

Before the application of antibiotics to treat otitis media, acute mastoiditis was a common clinical entity, occurring in up to 20% of cases of acute otitis media¹ and often requiring emergent mastoidectomy.² Since the use of antibiotics in the management of otitis media, incidence has decreased significantly.³ Although the incidence of acute coalescent mastoiditis has decreased, the incidence of fluid in the mastoid air cells, which can technically be referred to as “mastoiditis,” has not changed. This finding often is observed on imaging studies, including radiographs, computed tomography, or magnetic resonance imaging, frequently when these studies are obtained for unrelated purposes. Distinguishing between the relatively innocuous condition of mild mastoiditis and the emergency of acute coalescent mastoiditis can be accomplished by identifying key imaging and clinical signs (Table 1).

Mild mastoiditis occurs in almost every case of acute otitis media, which results in a middle ear effusion.⁴ On the image, there will be fluid in the

mastoid air cells but no evidence of destruction to the overlying bone (Figure 1). Because the mastoid air cells are contiguous with the middle ear via the aditus to the mastoid antrum, fluid will enter the mastoid air cells during episodes of otitis media with effusion. Indeed, almost all cases of otitis, whether sterile or infectious, will result in fluid filling the mastoid air cells.⁵ The majority of patients with otitis media are, unfortunately, not imaged; because of this we are unaware of the real incidence of mastoiditis in these patients. Most cases of mastoiditis are self-limited because the mucosa has an inherent ability to overcome acute mild infection.⁶ It is important to note that these patients will appear healthy.

Patients who present with mild mastoiditis should be treated like any patient with otitis media (Table 1). Otoscopy should be performed. Audiometry and tympanometry would be beneficial, if available, to evaluate possible hearing loss. Antibiotics may or may not be appropriate, and factors such as history of recurrent infections, presence of resistant organisms in the community, and patient age should be considered.

In rare cases, untreated mastoiditis can sometimes result in increased pressure within the mastoid cavity, which is relieved by movement of the fluid through the tympanomastoid fissure; this causes postauricular tenderness and inflammation. A subperiosteal abscess can develop as the periosteum is separated.⁴ In this case, a diagnosis of acute coalescent mastoiditis with subperiosteal abscess is made and immediate intervention is required. This

This article was externally peer reviewed.

Submitted 24 July 2012; revised 31 October 2012; accepted 2 November 2012.

From the Department of Surgery, Division of Otolaryngology-Head and Neck Surgery (MHM, MRH), and the Department of Radiology, University of Wisconsin School of Medicine and Public Health, Madison.

Funding: none.

Conflict of interest: none declared.

Corresponding author: Michael H. McDonald, Department of Surgery-Otolaryngology, University of Wisconsin School of Medicine, 2725 Medical Sciences Center, 1300 University Ave, Madison, WI 53706 (E-mail: michaelmcdonald@gmail.com).

Table 1. Summary Description of Mild Mastoiditis and Acute Coalescent Mastoiditis

	Mild Mastoiditis	Acute Coalescent Mastoiditis
Imaging findings	<ul style="list-style-type: none"> • Fluid in mastoid cavity • No invasion of bony septa 	<ul style="list-style-type: none"> • Fluid in mastoid cavity • Invasion of bony septa • Possible elevation of bone due to subperiosteal abscess
Exam findings	<ul style="list-style-type: none"> • Possible otitis media • May be asymptomatic • Generally healthy 	<ul style="list-style-type: none"> • Pain or mastoid tenderness • Discharge from the ear • Bulging tympanic membrane • Retroauricular fluctuance • Possible raised erythematous area in retroauricular space • May have meningeal symptoms, facial nerve paralysis, high fever, or sepsis
Additional tests needed	<ul style="list-style-type: none"> • Otoscopy • Tympanometry • Audiometry 	<ul style="list-style-type: none"> • Cranial MRI if intracranial complications are suspected
Management	<ul style="list-style-type: none"> • Consider antibiotics appropriate for treatment of otitis media • No referral necessary 	<ul style="list-style-type: none"> • Referral to otolaryngology for hospitalization and intravenous antibiotics or surgical intervention

MRI, magnetic resonance imaging.

can include hospitalization and intravenous antibiotics with or without myringotomy or retroauricular puncture⁷ or, in more severe cases, mastoidectomy.⁸ If available, images will show fluid in the mastoid cavity with destruction of the bony septa within the mastoid process (Figure 2). Compared with mild mastoiditis, the key distinguishing factor pathologically and radiographically is necrosis and demineralization of the bony septa.⁵ If a subperiosteal abscess is present, the periosteum will be elevated with an opacified area deep to it.

Patients with acute coalescent mastoiditis will also appear obviously sick; there are no silent cases of acute coalescent mastoiditis. Key clinical signs include a bulging tympanic membrane, protruding pinna, abundant discharge from and pain in the ear, a high fever, and mastoid tenderness.⁹ Patients presenting with advanced disease and late complica-

tions may also present with sepsis, meningeal symptoms, or facial nerve paralysis. In a retrospective review by Glynn et al,⁴ retroauricular fluctuance reflective of a subperiosteal abscess was the only clinical sign significantly associated with the need for surgical intervention. If the subperiosteal abscess extends toward the sigmoid sinus, acute intracranial symptoms may occur.

In cases of acute coalescent mastoiditis, immediate referral to otolaryngology and hospitalization are warranted. Depending on the severity, intravenous antibiotics may be administered or surgical intervention (mastoidectomy) may be employed

Figure 1. A) Acute uncomplicated mastoiditis in an asymptomatic patient. There is fluid in the mastoid cavity but no evidence of destruction of the bony septa within the mastoid process (black arrow). B) Bilateral mastoiditis in patient with acute otitis media complicated by temporary facial nerve paralysis. The patient was treated with oral antibiotics.

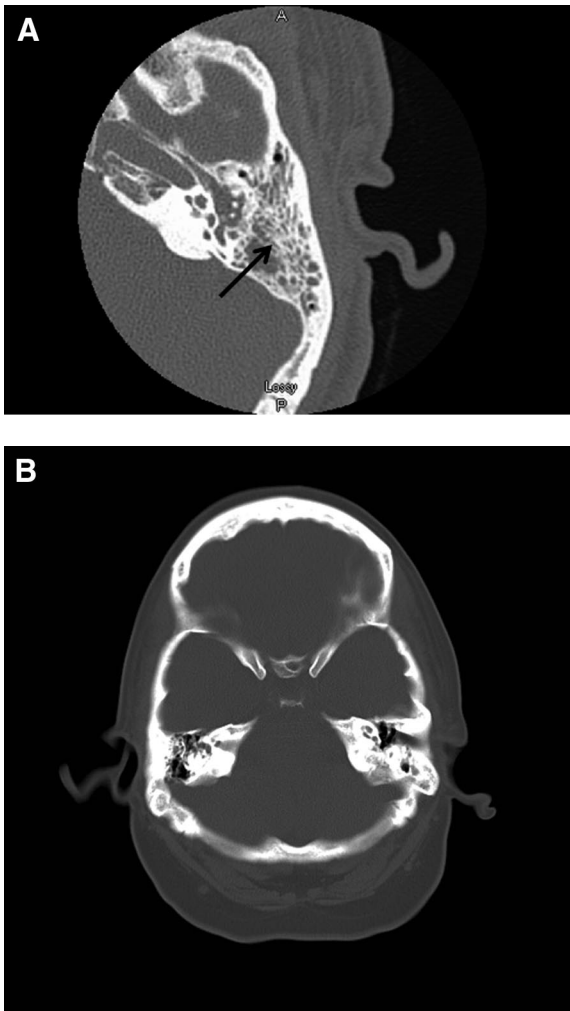
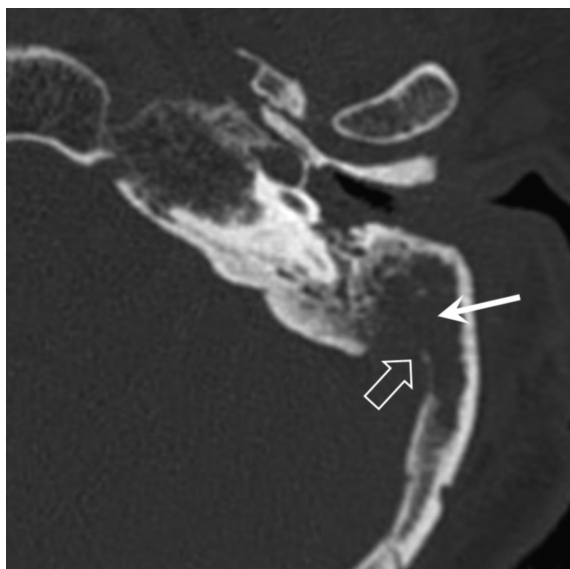


Figure 2. Acute coalescent mastoiditis. There is fluid in the mastoid cavity with extensive destruction (coalescence) of the bony septa within the mastoid process (white arrow). There is also destruction of the cortical bone separating the mastoid cavity from the sigmoid sinus (open white arrow).



(Table 1). In addition, a cranial magnetic resonance imaging scan may be obtained if intracranial complications are suspected.¹⁰

A diagnosis of “mastoiditis” on a radiologist’s report, even in a patient who otherwise appears well, can be alarming. Mastoiditis is an infamously morbid disease that is discussed frequently in medical textbooks as a complication of otitis media. An incidental finding of fluid in the mastoid air cells in an otherwise healthy individual can be approached like any case of otitis media, whereas fluid in the

mastoid combined with destruction of surrounding bone in a seriously ill patient is a medical emergency. Mastoiditis is ultimately a clinical diagnosis.

References

1. Spratley J, Silveira H, Alvarez I, Pais-Clemente M. Acute mastoiditis in children: review of the current status. *Int J Pediatr Otorhinolaryngol* 2000;56:33–40.
2. Dhooze IJM, Vandenbussche T, Lemmerling M. Value of computed tomography of the temporal bone in acute otomastoiditis. *Rev Laryngol Otol Rhinol (Bord)* 1998;119:91–4.
3. Palva T, Virtanen H, Makinen J. Acute and latent mastoiditis in children. *J Laryngol Otol* 1985;99:127–36.
4. Glynn F, Osman L, Colreavy M, Rowley H, Dwyer TPO, Blayney A. Acute mastoiditis in children: presentation and long term consequences. *J Laryngol Otol* 2008;122:233–7.
5. Anderson KJ. Mastoiditis. *Pediatr Rev* 2009;30:233–4.
6. Mafee MF, Singleton EL, Valvassori GE, Espinosa GA, Kumar A, Aimi K. Acute otomastoiditis and its complications: role of CT. *Radiology* 1985;155:391–7.
7. Bakhos D, Trijolet JP, Moriniere S, Pondaven S, Al zahrani M, Lescanne E. Conservative management of acute mastoiditis in children. *Arch Otolaryngol Head Neck Surg* 2011;137:346–50.
8. Migirov L, Yakirevitch A, Kronenberg J. Mastoid subperiosteal abscess: a review of 51 cases. *Int J Pediatr Otorhinolaryngol* 2005;69:1529–33.
9. Maroldi R, Farina D, Palvarini L, et al. Computed tomography and magnetic resonance imaging of pathologic conditions of the middle ear. *Eur J Radiology* 2001;40:78–93.
10. Vazquez E, Castellote A, Piqueras J, et al. Imaging of complications of acute mastoiditis in children. *Radiographics* 2003;23:359–72.