

BRIEF REPORT

Traction Alopecia in Sikh Male Patients

Jinny James, BS, Rao N. Saladi, MD, and Joshua L. Fox, MD

This article reports on traction alopecia among Sikh males as a result of stress on the hair from wearing a turban. Treatment for this condition in such a population is difficult. Permanent removal of the turban is religiously forbidden. Therefore, the traction continues, as will the alopecia, possibly accompanied by seborrheic dermatitis and psoriasis. (J Am Board Fam Med 2007;20:497–498.)

Traction alopecia is a form of nonpermanent alopecia which is the result of physical damage to the hair shaft. This can be caused by hair styles that tightly pull the hair such as braiding, ponytails, or other forms of habitual stress on the scalp.¹ Generally, once the stress on the scalp is relieved there is a high chance of regrowth. However, scarring of the localized tissue can be a likely outcome, ultimately leading to permanent alopecia. Traction alopecia is very frequently reported among African American males and females attributable to their individual hair styles and the susceptibility of their hair follicles.²

This condition is also a common disorder among Sikh males. Sikhism is a religion followed primarily by inhabitants of Punjab, a state in India. As part of their religious practice, males as well as females are forbidden to cut their hair. Males more specifically are required to wear a turban on their head.^{3,4} The turban is a long scarf which is wrapped tightly in a particular way around the long hair and placed atop the head (Figure 1A). Before wrapping the cloth around the hair, the hair is tied into a tight knot resting on the frontal region of the scalp (Figure 1B). Most Sikhs will wear this style for a full 24 hours or longer, after which the turban will be

removed and the hair combed. The frontal scalp region is where the alopecia will usually occur given that it experiences the bulk of the trauma (Figure 1C). Traction alopecia can also arise in the sub-mandibular area because the majority of the followers of Sikhism will also practice a similar method of knotting their beard. Beard hair, like scalp hair, is grown long and never cut. The hair is put into a ponytail, twisted, and tightly tied into a knot under the chin. In time, alopecia over the mandible can be seen.

In many cases with traction alopecia, as with our patient, seborrheic dermatitis or psoriasis may occur concomitantly. Although mild alopecia can occur as a result of seborrheic dermatitis and psoriasis, the primary basis for their dramatic focal hair loss is traction. Treatment of seborrhea or psoriasis will only reduce the symptoms while the traction alopecia will continue to progress.

Treatment of traction alopecia in Sikh patients can be a difficult process. Religious laws forbid the cutting of hair and require the wearing of the turban. Therefore cutting the hair is not an option. Patients can be advised to allow their hair to be tied loosely and free of a turban for as long as possible during the day. At night they should refrain from wearing the turban and tie their hair in a loose ponytail without the knot. When wearing the turban, the hair should be tied loosely at the scalp to decrease the tension. Patients can be treated with topical steroids, however, unless the tension is relieved, these treatments will prove ineffective. Patients should also be advised that traction alopecia may lead to permanent alopecia, which is progressive if the traction is not removed.

This article was externally peer reviewed.

Submitted 19 March 2007; accepted 28 March 2007.

From the New Age Skin Research Foundation, Fresh Meadows, NY (JJ, RNS, JLF), Albert Einstein School of Medicine, Bronx, NY (JLF), and Advanced Dermatology, Fresh Meadows, NY (JLF).

Funding: none.

Conflict of interest: none declared.

Corresponding author: Joshua L. Fox, Advanced Dermatology, 58-47 188th Street, Fresh Meadows, NY 11365 (E-mail: joshuafox@newageskin.org).

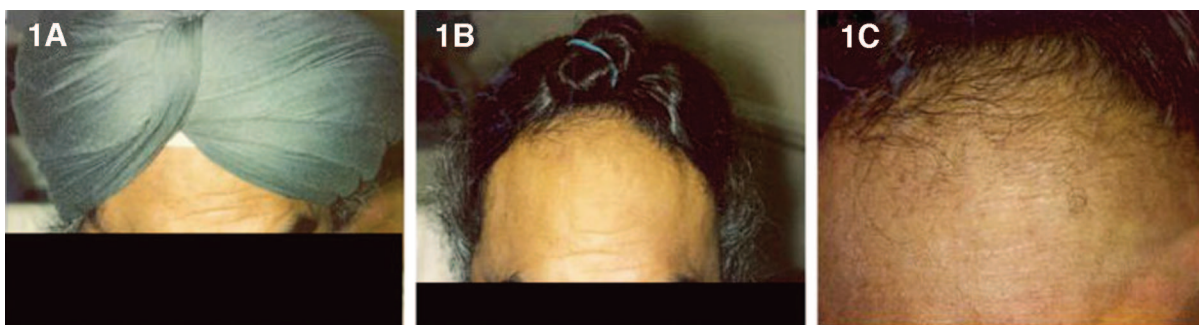


Figure 1. Traction alopecia in Sikh male patient due to the use of a turban.

References

1. Ozcelik D. Extensive traction alopecia attributable to ponytail hairstyle and its treatment with hair transplantation. *Aesthetic Plast Surg* 2005;29:325–7.
2. Mulinari-Brenner F, Bregfeld F. Hair loss: an overview. *Dermatol Nurs* 2001;13:269–78.
3. Singh G. Traction alopecia in Sikh boys. *Br J Dermatol* 1975;92:232–3.
4. Kanwar A, Kaur S, Basak P, Sharma R. Traction alopecia in Sikh males. *Arch Dermatol* 1989;125:1587.