

# Small Colon Polyps: The Primary Physician's Dilemma

Jaydev R. Varma, M.D., and Richard E. Melcher, M.D.

**Abstract:** This case report and literature review is presented to alert primary care physicians performing flexible sigmoidoscopy and limited colonoscopy to the malignant potential of even diminutive polyps.

The term "polyp" refers to any circumscribed mass of tissue that arises from mucosa and protrudes into the lumen of the gastrointestinal tract. The significance of this lesion in the rectum and colon is its propensity for malignant change. Although small polyps in the region of the rectum tend to be hyperplastic and those more proximal tend to be adenomas

A 44-year-old white man came for a routine physical examination at the Family Practice Center of the Medical College of Georgia. The patient had been treated for essential hypertension for 7 years and currently was well controlled with a single agent. He was asymptomatic, and his family history was negative for cancer.

His physical examination showed him to be well-developed and well-nourished. Although fundoscopic examination revealed early vascular changes consistent with hypertension, no other manifestations of disease were found. Complete blood count, SMA-18™, and electrocardiogram were all unremarkable, and the stool was guaiac negative. Screening flexible sigmoidoscopy was suggested and performed 6 days later at the Center. Following routine preparation, the rectum and colon were examined to a distance of 60 cm without difficulty. A single sessile lesion estimated at 5 to 6 mm was located at 25 cm. Although the lesion was less than 1 cm in size, it exhibited a "thin red zone" at its base, an abnormality not usually found with hyperplastic polyps (Figures 1, 2). This finding should alert one to the presence of an adenoma, even before biopsy, in circumstances like this. The patient was referred for colonoscopy.

Complete colonoscopy confirmed the presence of the single lesion, and a biopsy was performed. The tan mucoid lesion was 0.6 × 0.5 × 0.4 cm

From the Department of Family Medicine, Medical College of Georgia, Augusta, GA. Address reprint requests to Jaydev R. Varma, M.D., Department of Family Medicine, EG 226, Medical College of Georgia, Augusta, GA 30912-3520.

with a significant malignant potential, there is no way to distinguish them visually; hence, all need to be biopsied. The following case report shows the necessity of identifying neoplastic lesions within diminutive polyps (< 1 cm). Standard biopsy technique usually removes these lesions; nevertheless, when histology confirms the presence of adenoma or carcinoma, the patient requires additional evaluation of the entire large intestine and more frequent follow-up examinations. (J Am Bd Fam Pract 1989; 2:204-7.)

and was identified as an adenomatous polyp with atypical hyperplasia and mitotic activity consistent with early adenocarcinoma (Figure 3). The patient was treated definitively with segmental surgical resection of the colon. The following are his surgical and pathology reports:

## Surgery

The patient had previous removal of an adenomatous polyp with carcinoma within the polyp at 23–27 cm. The sigmoid was initially taken out and submitted to pathology in a fresh state. The polypectomy site was not found. Further exploration distally down to below the peritoneal reflection to the midrectum was accomplished, and this segment was resected, revealing a small area of ulceration, which appeared to be the biopsy site. No other abnormalities were noted; the peritoneal cavity was smooth and glistening; the liver was free of palpable abnormality, and there was no evidence of any mesenteric adenopathy or periaortic adenopathy. Discharge diagnosis was adenomatous polyp with carcinoma in the polyp and colon, probable Duke's stage-A carcinoma of the colon.

## Pathology

### Biopsy of Small Polyp during Colonoscopy

A tan mucoid lesion: 0.6 × 0.5 × 0.4 cm with atypical hyperplasia and mitotic activity consistent with early adenocarcinoma.

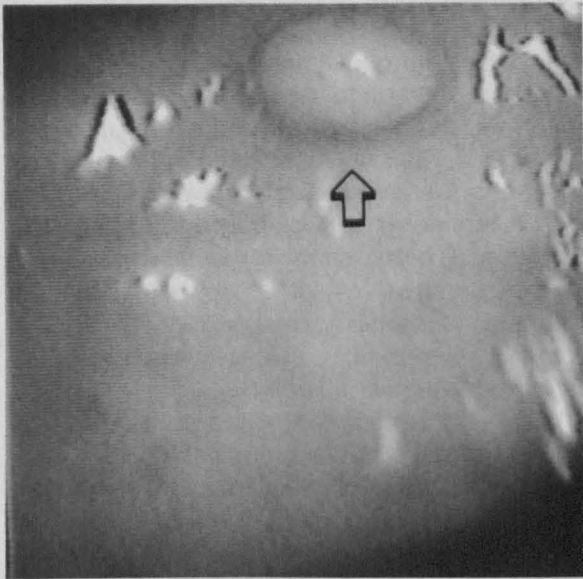


Figure 1. Small polyp surrounded by a red zone at the base.




Figure 2. Black arrow: small polyp with red zone at the base; clear arrow: normal mucosa.

**Specimen: Segments of Sigmoid Colon, Part A and Part B**

*Part A.* Representative sections are examined microscopically. This includes a section of the small hyperplastic polyp noted grossly. A random section of colonic mucosa is unremarkable.

*Part B.* Multiple representative sections are examined microscopically. This consists of sections of colon showing an intact mucosal surface. There is underlying vascular congestion and hyperemia. This is probably related to the surgical procedure. No definite previous excision site is identified microscopically or grossly.

**Discussion**

Although the adenomatous polyp in this case was less than 0.7 cm, early adenocarcinoma was identified histologically, showing the need for definitive treatment. While individual polyp size and the degree of dysplasia are important determinants of the potential for malignant change, even the smallest lesions may have neoplastic potential. Understanding the differences between hyperplastic polyps and adenomatous polyps is essential to this discussion.

Microscopically, the mucosal surface of the normal colon is flat and consists of simple, test-tube-shaped glands called crypts of Lieberkuhn.<sup>1-5</sup> Cell division occurs mainly in the deepest one-third of

these crypts. The cells then migrate upward to the surface and differentiate into mature goblet and absorptive cells.

Under normal circumstances, cell division and exfoliation occur as well-balanced phenomena. A protrusion or polyp results when factors disturbing this balance in favor of cell division occur.<sup>5,6</sup> Most of these polyps are minute hyperplastic dewdrop-like elevations ranging from 1 to 5 mm. Ninety percent of these polyps are said to be hyperplastic and 10 percent adenomatous.<sup>2,5-8</sup> The frequency of polyps (nonjuvenile) is variable, and they are estimated to occur in 25

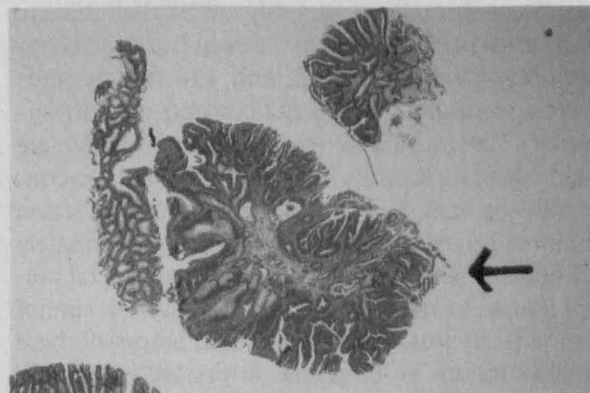


Figure 3. Arrow showing area of severe dysplasia suggestive of intramucosal carcinoma.

to 50 percent of adults, with the frequency increasing with age.<sup>6,7</sup>

These adenomas range from a few millimeters to several centimeters, occur in all shapes, and are either pedunculated or sessile. The lesions are usually noninvasive and considered to be benign. However, they are neoplastic; hence, there is a serious disturbance in cellular proliferation that is unrestricted. Therefore, cell differentiation is incomplete, and malignant potential exists.<sup>4,8-10</sup> In removing adenomas at colonoscopy, strict criteria need to be followed.<sup>11-13</sup>

To the naked eye, there is no distinction between the hyperplastic and neoplastic polyp.<sup>10</sup> Without biopsy, the diagnostic and treatment dilemma is self evident. Improvements in the technology of endoscopy have generated greater interest in flexible sigmoidoscopy screening by primary care physicians. The detection and identification of larger adenomas (greater than 1 cm) present less difficulty in management because their malignant potential is directly related to increasing size.<sup>8,14</sup> The dilemma arises when lesions are smaller than 1 cm, because the actual frequency of neoplasia in small colonic polyps is much higher than previously acknowledged.<sup>8</sup> Small lesions with any color changes should alert the physician that neoplastic vascularity often warrants the presumptive diagnosis of adenoma.

Feczko and others have reported on 222 polyps of which 144 (65 percent) were 1 cm or less.<sup>8</sup> Eighty percent of these were adenomatous. Eighty-two polyps ranged from 6 to 10 mm, and 68 (83 percent) of them were adenomas, including one adenocarcinoma and five villous adenomas. Forty-seven of the diminutive polyps ( $\leq 5$  mm) were adenomatous, including two with atypia.<sup>8</sup> Church and others have reported on the histology of small colonic polyps, less than 0.5 cm, in a series of 303 patients.<sup>15</sup> Seven hundred sixty-six polyps were removed, and 458 (60 percent) were adenomas, and 308 (22 percent) were hyperplastic. They suggested that lesions of this size are rarely symptomatic and are often followed too conservatively after discovery. The report further stated that small colorectal polyps comprise approximately 50 percent of all polyps. Although small rectal polyps tend to be hyperplastic, correct diagnosis cannot be made on gross inspection,<sup>10</sup> and biopsy of these smaller lesions is, therefore, important to identify neoplastic potential histologically.

Jass recently questioned whether hyperplastic polyps should ever be considered insignificant,

and he suggested a relationship between the epithelia of the two types of polyps.<sup>16</sup> He cited properties common to hyperplastic and villous adenomas, including reduced cytoplasmic enzymes, reduced secretion of O-acetylated sialomucin, absence of IgA secretion, and increased CEA activity.<sup>3</sup> He proposed two sets of phenomena affecting alteration of colonic epithelium: one set leading to hyperplasia, the other set to neoplasia. However, both sets contribute to malignancy. These phenomena might explain the occurrence of mixed hyperplastic-neoplastic polyps.<sup>17</sup>

Waye and associates reported on 1048 polyps less than 6 mm that were removed during colonoscopy.<sup>18</sup> Of these, 61 percent (638) were neoplastic, 38.9 percent (407) were nonneoplastic, and 212 were hyperplastic, with 188 mucosal excrescences. They recommended removal of all small colonic polyps encountered during colonoscopy in view of their potential for malignant change.

Tedesco reported on 329 diminutive polyps.<sup>1</sup> In this study, 49.2 percent were neoplastic, while 49.9 percent were nonneoplastic and 0.9 percent were of a mixed type. Lane found 90 percent of polyps to be hyperplastic and 10 percent to be adenomatous.<sup>2</sup> Lane and Fenoglio published a report wherein they stated, "The common hyperplastic polyp is not a neoplasm and is unrelated to either adenoma or carcinoma," and foci of carcinoma or adenoma are (almost) never found in these lesions.<sup>19</sup>

Morson and Konishi also indicated that there is no acceptable evidence that hyperplastic polyps have any malignant potential.<sup>20</sup>

Maskens, after a detailed histologic study, concluded that the hyperplastic polyp was a separate pathologic entity and has no malignant potential.<sup>21</sup>

In Gottlieb's study of 1124 diminutive polyps ( $\leq 5$  mm), there were 572 (51 percent) adenomas, 179 (16 percent) that were hyperplastic, and 373 (33 percent) either lipomas, normal mucosa, or other. He indicated that the diminutive polyp should be considered part of the adenoma-dysplasia-adenocarcinoma continuum.<sup>22</sup>

## Conclusion

In the midst of conflicting findings, the primary care physician, who is increasingly performing sigmoidoscopies and limited colonoscopies, encounters these diminutive lesions and is faced

with the decision of proper management. It is prudent to observe the view that although diminutive polyps in the region of the rectum tend to be hyperplastic and those more proximal tend to be adenomas, there is no way to differentiate them visually.<sup>6,9,18</sup> Lesions up to 1.0 cm, formerly thought to be "safe," should be considered for biopsy. When pathology reports neoplastic tissue, further evaluation of the entire colon is indicated. The patient is then identified as being high risk for colorectal cancer. Evaluation for complete polypectomy and detection of recurrence are indicated.

## References

1. Tedesco FJ, Hendrix JC, Pickens CA, Brady PG, Mills LR. Diminutive polyps: histopathology, spatial distribution, and clinical significance. *Gastrointest Endosc* 1982; 28:1-5.
2. Lane N, Kaplan H, Pascal RR. Minute adenomatous and hyperplastic polyps of the colon: divergent patterns of epithelial growth with specific associated mesenchymal changes. Contrasting roles in the pathogenesis of carcinoma. *Gastroenterology* 1971; 60:537-51.
3. Dawson PM, Habib NA, Rees HC, Wood CB. Mucosal field change in colorectal cancer. *Am J Surg* 1987; 153:281-4.
4. Matthews JL, Glynn M, Parkins A, Cooke T. Alteration in colonic epithelial cell DNA associated with intestinal neoplasia: selection of high risk patients. *Br J Surg* 1987; 74:23-5.
5. Fenoglio CM, Pascal RR. Colorectal adenomas and cancer: pathologic relationships. *Cancer* 1982; 50(Suppl):2601-8.
6. Fenoglio CM, Lane N. The anatomical precursor of colorectal carcinoma. *Cancer* 1974; 34:819-23.
7. Fedotin MS, Ginsberg DW. Practical considerations in screening for colorectal cancer. *Mod Med* 1988; 56:127-35.
8. Feczko PJ, Bernstein MA, Halpert RD, Ackerman LV. Small colonic polyps: a reappraisal of their significance. *Radiology* 1984; 152:301-3.
9. Cooper HS, Patchefsky AS, Marks G. Adenomatous and carcinomatous changes within hyperplastic colonic epithelium. *Dis Colon Rectum* 1979; 22:152-6.
10. Neale AV, Demers RY, Budev H, Scott RO. Physician accuracy in diagnosing colorectal polyps. *Dis Colon Rectum* 1987; 30:247-50.
11. Decosse JJ. Malignant colorectal polyp. *Gut* 1984; 25:433-6.
12. Morson BC, Whiteway JE, Jones EA, Macrae FA, Williams CB. Histopathology and prognosis of malignant colorectal polyps treated by endoscopic polypectomy. *Gut* 1984; 25:437-44.
13. Winawer SF, Sherlock P. Surveillance for colorectal cancer in average-risk patients, familial high-risk groups, and patients with adenomas. *Cancer* 1982; 50(Suppl):2609-14.
14. Lotfi AM, Spencer RJ, Ilstrup DM, Melton LJ, 3d. Colorectal polyps and the risk of subsequent carcinoma. *Mayo Clin Proc* 1986; 61:337-43.
15. Church JM, Fazio VW, Jones IT. Small colorectal polyps. Are they worth treating? *Dis Colon Rectum* 1988; 31:50-3.
16. Jass JR. Relation between metaplastic polyp and carcinoma of the colorectum. *Lancet* 1983; 1: 28-30.
17. Fenoglio-Preiser CM, Hutter RV. Colorectal polyps: a pathologic diagnosis and clinical significance. *CA* 1985; 35:322-44.
18. Waye JD, Lewis BS, Frankel A, Geller SA. Small colon polyps. *Am J Gastroenterol* 1988; 83:120-2.
19. Lane N, Fenoglio CM. Observations on the adenoma as precursor to ordinary large bowel carcinoma. *Gastrointest Radiol* 1976; 1:111-9.
20. Morson BC, Konishi F. Contribution of the pathologist to the radiology and management of colorectal polyps. *Gastrointest Radiol* 1982; 7: 275-81.
21. Maskens AP. Histogenesis of adenomatous polyps in the human large intestine. *Gastroenterology* 1979; 77:1245-51.
22. Gottlieb LS, Winawer SJ, Sternberg S, et al. National polyp study (NPS): the diminutive colonic polyp. Mallory Institute of Pathology. Boston: Memorial Sloan-Kettering Cancer Center 1984; 30(2). abstract.