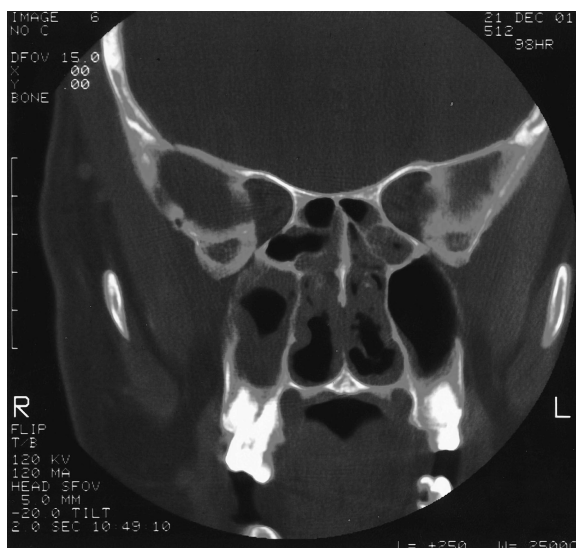

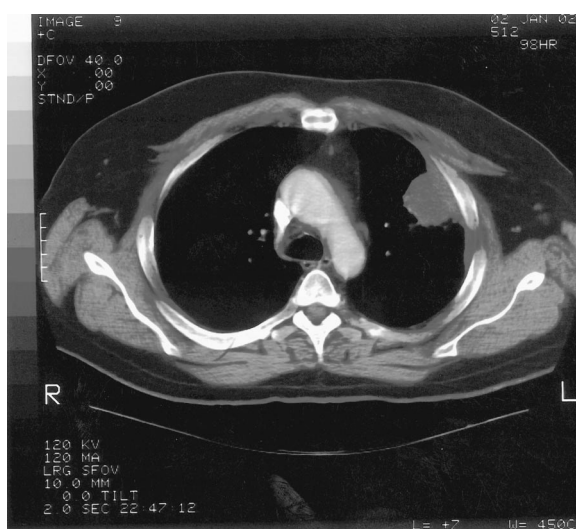## ERRATUM

# Correction to “Wegener granulomatosis: case report and brief literature review”

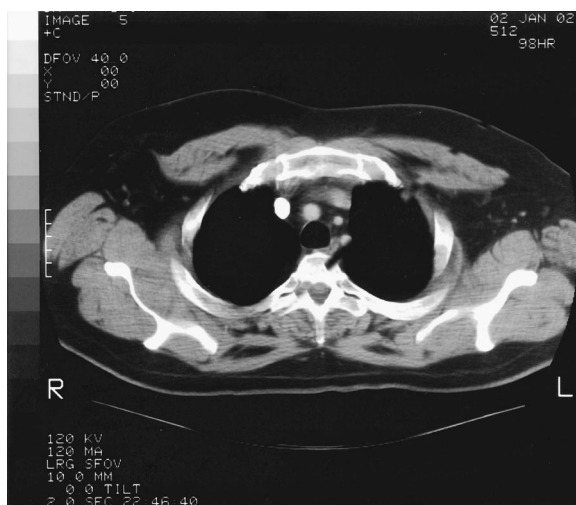In the above article (Shafiei K, Luther E, Archie M, Gulick J, Fowler MR. J Am Board Fam Pract 16: 555–9), the four figures and figure legends were mismatched. They are printed correctly below. We regret this error and apologize for any confusion or inconvenience it may have caused.



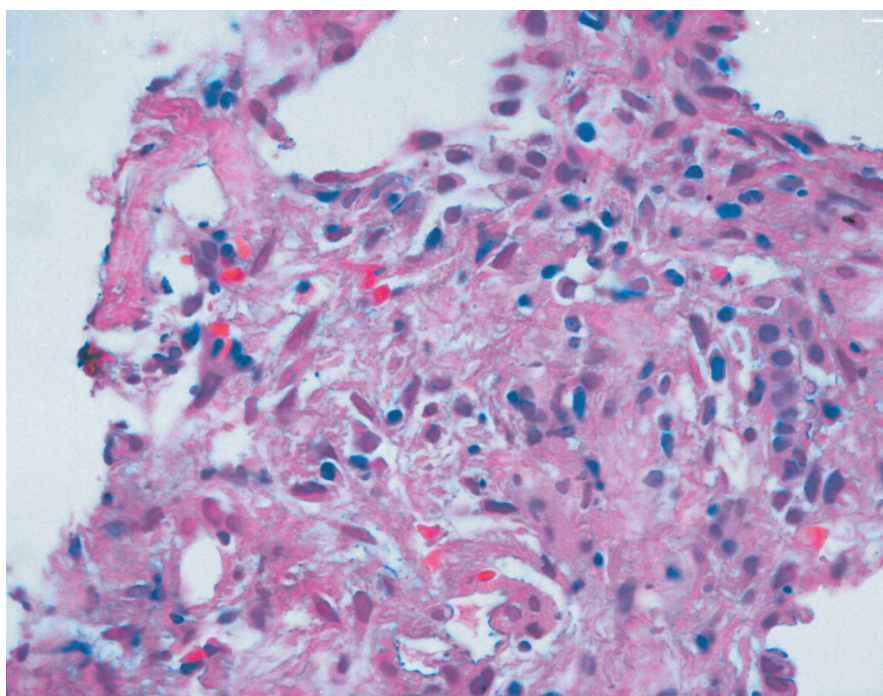
**Figure 1.** Coronal CT of sinuses demonstrating bilateral ethmoid and maxillary sinus disease.



**Figure 2.** Chest CT demonstrating soft tissue mass in left upper lobe abutting the pleura.



**Figure 3.** Chest CT demonstrating small noncalcified lesions in the left upper lobe.



**Figure 4.** Focus of granulomatous inflammation, lung (hematoxylin and eosin; original magnification, 400 $\times$ ).