

Successful Pharmacologic Treatment of Lower Extremity Ulcerations in 5 Patients with Chronic Critical Limb Ischemia

Steven M. Dean, DO, and Patrick S. Vaccaro, MD

Background: Ischemic ulcerations of the distal lower extremities are a manifestation of chronic critical limb ischemia. Without restoration of arterial flow, subsequent gangrene and limb loss can ensue. Unfortunately, revascularization is not always possible.

Methods: A literature search of MEDLINE was performed and a case series of 5 patients with lower extremity ischemic ulcerations is described.

Results and Conclusion: Five patients with severe peripheral artery disease had nonhealing lower extremity ischemic ulcerations. Because 3 patients were not ideal candidates for percutaneous or surgical intervention, and 2 refused invasive therapy, they were treated with cilostazol. Between 7 and 24 weeks after beginning cilostazol therapy, the ulcerations healed in all 5 patients. Three of the patients experienced resolution of concurrent ischemic rest pain. One patient underwent a posttreatment noninvasive arterial study that documented improved large- and small-vessel perfusion. The antiplatelet, antithrombotic, and vasodilatory effects, in addition to possible unrecognized actions of cilostazol, appeared to promote wound healing in this small group of patients with chronic critical limb ischemia. When revascularization is not ideal therapy for ischemic ulcers, a pharmacologic approach with cilostazol might induce healing and obviate limb amputation. (J Am Board Fam Pract 2002;15:55–62.)

Peripheral artery disease is a disorder typically caused by atherosclerosis that limits blood flow to the limbs. Most patients with peripheral artery disease are either asymptomatic or complain of intermittent claudication (exertional leg pain that is promptly relieved with rest). A minority, however, develop chronic critical limb ischemia whereby the integrity of the limb is jeopardized. In this scenario, peripheral artery disease is complicated by ischemic rest pain, nonhealing ulcerations, or gangrene. Without restoration of limb perfusion, the patient who has peripheral artery disease and chronic critical limb ischemia is at high risk for limb loss. Yet revascularization might not be technically possible. As a result, pharmacotherapy is sometimes used as a last resort for improving the manifestations of chronic critical limb ischemia. Unfortunately, limb salvage is rarely achieved with a pharmaceutical approach. In this article, we describe ischemic ulcerations in 5 patients that were successfully treated with cilostazol.

Methods

MEDLINE was searched using the following key words: “cilostazol,” “ulcerations,” “chronic critical limb ischemia,” and “peripheral arterial disease.” The literature search did not find articles in the English language that analyzed cilostazol in the setting of chronic critical limb ischemia. Consequently, a case series was prepared on the use of cilostazol in the treatment of lower extremity ischemic ulcerations.

Case 1

An 84-year-old minimally ambulatory man with a history of type 2 diabetes mellitus, hypertension, hyperlipidemia, coronary artery disease, and previous tobacco use (1 pack per day for 5 years) was referred to the office for evaluation of a nonhealing, painful ulceration on the right distal hallux. The pain in his great toe worsened at night and was relieved by placing the extremity in a dependent position. The ulcer had been present for approximately 14 weeks and had failed to improve despite various medications, including topical mupirocin, aspirin, and a 2-month course of antibiotics (which included 4 weeks of parenteral antibiotics).

Submitted, revised, 13 November 2001.

From Vascular Services of Ohio (SMD, PSV), Columbus. Address reprint requests to Steven M. Dean, DO, 81 East Wilson Bridge Road, Columbus, OH 43085.

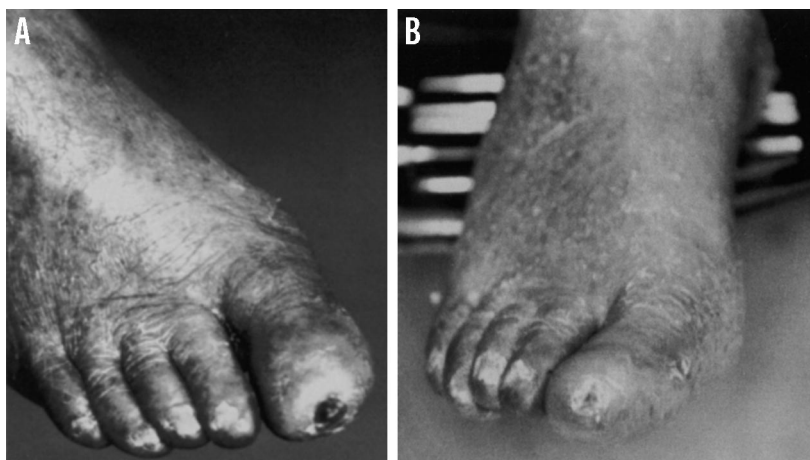

Figure 1 (Case 1). A. Ischemic right hallux ulceration. B. Right hallux after 10 weeks of therapy with cilostazol. The ulcer had healed with visible evidence of reepithelialization.

When examined, his feet were cool bilaterally with dependent rubor and pallor on elevation. A distal ulceration was observed on the right hallux, the base of which was composed primarily of dry fibrin and necrotic debris. There was only a minimal amount of granulation tissue (Figure 1A). The underlying bone was not exposed or palpable. The femoral and popliteal pulses were normal, but the dorsalis pedis and posterior tibial pulses were absent.

The patient's right ankle-brachial index measured 0.52, and his ankle systolic pressure was 64 mm Hg. The ankle-brachial index was falsely elevated because of partially calcified vessels. Arterial Doppler ultrasonography displayed posterior tibial and dorsalis pedis monophasic waveforms. In addition, the pulsed volume recording waveform at the right ankle was severely dampened (approximately 5–6 mm of amplitude) indicating severe large-vessel ischemia. The transmetatarsal waveform was flat, and the hallux waveform showed erratic, minimal pulsatility (suggesting a motion artifact, not true perfusion), which was indicative of concurrent severe small-vessel ischemia (Figure 2A). The distal plethysmographic waveforms were obtained after 5 minutes of external warming to eliminate possible vasospasm.

Percutaneous or surgical intervention was not considered an ideal treatment option for this patient because of his limited ambulatory status, advanced age, and comorbid disease. As a result, he was prescribed cilostazol, 50 mg twice a day (dose adjusted to accommodate concurrent nifedipine

therapy). After 10 weeks of cilostazol therapy, the ulcer had healed (Figure 1B), and the patient's ischemic pain had resolved. A follow-up pulsed volume recording examination displayed subtle increased pulsatility within the ankle waveform (amplitude increased to 7–8 mm) and new pulsatility at the transmetatarsal and hallux levels (Figure 2B). The ankle-brachial index increased from 0.52 to 0.57 (ankle systolic pressure increased from 64 to 82 mm Hg).

The patient returned 3 months after the follow-up visit for evaluation and treatment of a recurrent right hallux ulceration. He had mistakenly discontinued cilostazol a month earlier and subsequently traumatized the right distal hallux, provoking a second, stereotypical ischemic ulcer. Cilostazol was again prescribed, and the patient was counseled about the importance of adhering to therapy. The second ulcer healed within 2 months. By the 1-year follow-up visit, the patient was continuing to take cilostazol faithfully and has remained free of ulcers.

Case 2

A 58-year-old woman with type 2 diabetes mellitus, short-distance bilateral calf claudication, peripheral neuropathy, and current long-standing tobacco use (1 pack per day for 40 years) was seen for evaluation of a large left calf ulceration. Six weeks earlier, a bulla spontaneously developed that the patient debrided with hair scissors. Subsequently, a large, moderately painful ulcer evolved, which failed to

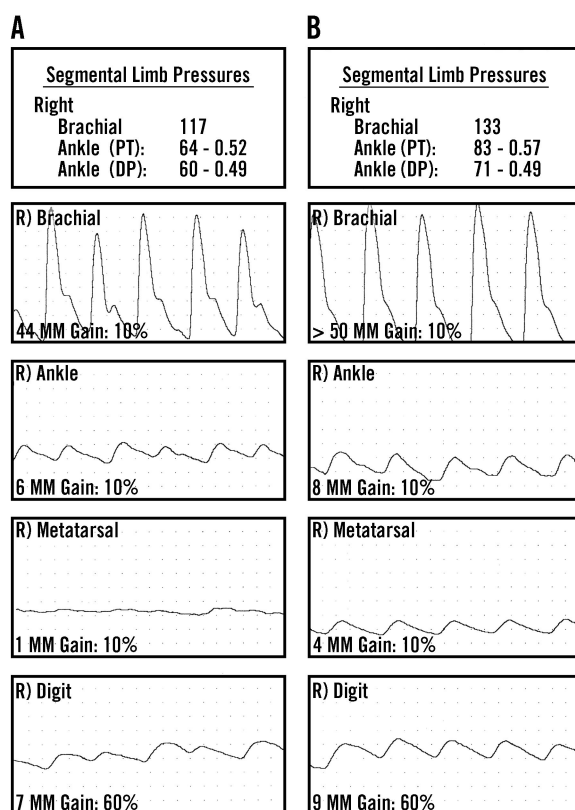


Figure 2 (Case 1). A. Pretreatment noninvasive arterial study. Right ankle-brachial index measured 0.52, with an ankle systolic pressure of 64 mm Hg. Severely dampened right ankle pulsed volume recording waveform indicates severe ischemia and suggests an ankle-brachial index falsely elevated because of arterial calcification. The right transmetatarsal waveform is flat, and hallux waveform displays erratic, minimal pulsatility (suggesting motion artifact, not true perfusion), indicating concurrent severe small-vessel ischemia. B. Posttreatment noninvasive arterial study. Right ankle-brachial index increased to 0.57 (ankle systolic pressure increased to 82 mm Hg). Right pulsed volume recording waveforms at level of ankle, transmetatarsal, and hallux displayed increased pulsatility (note the increased amplitude of ankle waveform to 7–8 mm)

improve despite treatment that included weekly debridement and oral and topical antibiotics.

The physical examination was remarkable for a 15 × 6 cm left calf ulceration with a base composed of an admixture of granulation tissue, moderate fibrin, and partial necrosis. The left femoral pulse was normal, but the popliteal, posterior tibial, and dorsalis pedis pulses were not palpable.

The left ankle-brachial index measured 0.48 with an ankle systolic pressure of 73 mm Hg. The ankle-brachial index was probably falsely elevated as a result of partially calcified vessels, as the arterial Doppler waveforms from the left popliteal, posterior tibial, and dorsalis pedis arteries were severely monophasic.

The patient adamantly refused to undergo arteriography and invasive intervention. Four more weeks of oral and topical antibiotics, weekly debridement, and aspirin therapy resulted in minimal improvement. Consequently, cilostazol, 100 mg twice a day, was added. During the next 6 weeks, increasingly robust granulation tissue appeared within the ulcer base, and the margins began to contract. A skin substitute wound dressing (Apligraf) was placed to expedite healing. Twelve weeks later, the ulcer had healed. At her 6-month follow-up examination, the patient has remained free of ulceration.

Case 3

An 87-year-old woman with a history of type 2 diabetes mellitus, short-distance bilateral calf claudication, and current long-standing tobacco use (½ to 1 pack per day for 60 years) came in for evaluation of a nonhealing painful ulceration on the left distal second toe. Her toe pain was aggravated by elevation and relieved when in a dependent position. The ulcer spontaneously appeared 1 month earlier and had not improved despite topical mupirocin and oral pentoxifylline. When examined, she had a palpably cool left foot with dependent rubor and pallor on elevation. A distal ulceration was found on the left second toe; its base was predominately composed of fibrin and minimal granulation tissue. No exposed or palpable bone was observed. The left femoral pulse was normal, but the popliteal, dorsalis pedis, and posterior tibial pulses were absent.

The left ankle-brachial index measured 0.47, with an ankle systolic pressure of 74 mm Hg; however, this value was falsely elevated as the arterial Doppler waveforms from the posterior tibial and dorsalis pedis arteries were severely monophasic (nearly flat), a finding consistent with severe large-vessel ischemia. The left first and second toe plethysmographic waveforms obtained after 5 minutes of external warming were essentially flat (≤ 2 mm), indicating attendant critical small-vessel ischemia.

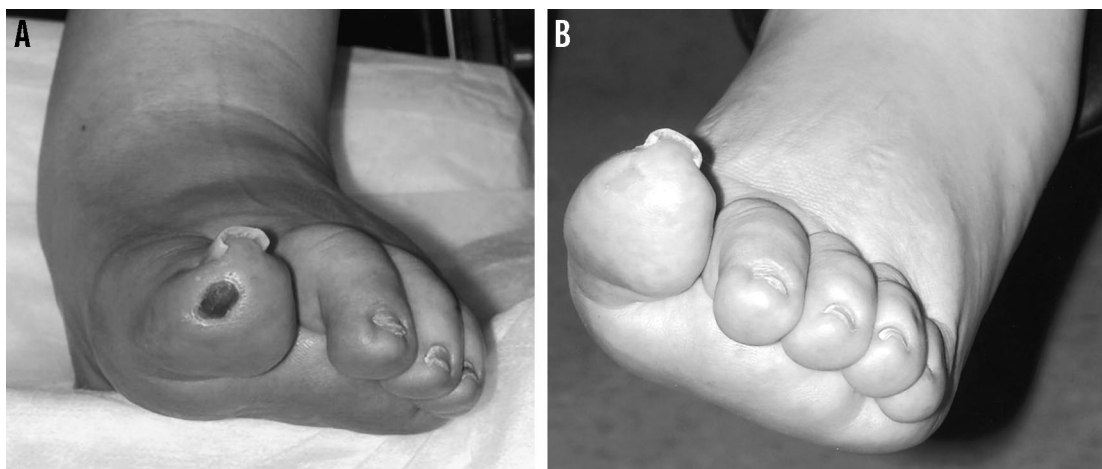


Figure 3 (Case 4). A. Ischemic left hallux ulceration when first examined. B. Left hallux after only 7 weeks of therapy with cilostazol. The ulcer had closed completely.

Invasive intervention was not an ideal treatment option because of her advanced age and comorbid disease. Cilostazol was started at a dose of 100 mg twice a day. After 17 weeks of cilostazol therapy, the ulcer had healed, and her ischemic rest pain had resolved. At a 3-month follow-up visit, no recurrent ulcerations had developed.

Case 4

A 70-year-old woman with type 2 diabetes mellitus, hypertension, and left hemiparesis was evaluated for a nonhealing left distal hallux ulceration. The patient resided in an extended-care facility and was wheelchair bound as a result of a right hemispheric stroke. Six months before her vascular evaluation, the patient traumatized the distal aspect of her hallux while transferring from her wheelchair. A subsequent ulcer ensued that failed to improve despite multiple topical treatments and several courses of oral antibiotics.

When examined, she had bilaterally cool feet with pronounced dependent rubor and pallor on elevation. An ulceration with a dry necrotic base was noted on the distal left hallux (Figure 3A). No gross signs of infections were observed. The femoral pulses were normal; however, the bilateral popliteal, dorsalis pedis, and posterior tibial pulses were absent.

A radiograph was negative for osteomyelitis of the distal phalanx. Ankle-brachial indices could not be obtained because the bilateral dorsalis pedis and posterior tibial Doppler signals were inaudible. A pulsed volume recording study documented multi-

segmental occlusive disease, and the bilateral ankle waveforms were essentially flat, a finding consistent with critical limb ischemia (Figure 4).

Neither percutaneous nor surgical interventions were ideal treatment options because the patient was not ambulatory and the ulceration involved a paretic extremity. She was therefore given cilostazol, 100 mg twice a day. After only 7 weeks of cilostazol therapy, the ulcer had healed (Figure 3B). The ulcer remained healed when she was seen at a 2-month follow up visit.

Case 5

A 41-year-old man with end-stage renal disease and hypertension was evaluated for persistent painful ulcerations on the right first and fourth toes. He was neither diabetic nor a smoker, and his renal failure was presumed caused by chronic pyelonephritis and possibly hypertension. Three months earlier he developed spontaneous painful ulcerations on the right first and fourth toes. His discomfort was aggravated by elevation and partially relieved with dependency and narcotic medication. The ulcerations had progressed despite supportive care and oral antibiotics.

When examined, he had a palpably cool right distal forefoot and toes, with dependent rubor and pallor on elevation. A small necrotic crust was observed on the right distal hallux, and an irregular ischemic ulceration was noted on the proximal-dorsal right fourth toe (Figure 5A). The bilateral femoral and popliteal pulses were easily palpable,

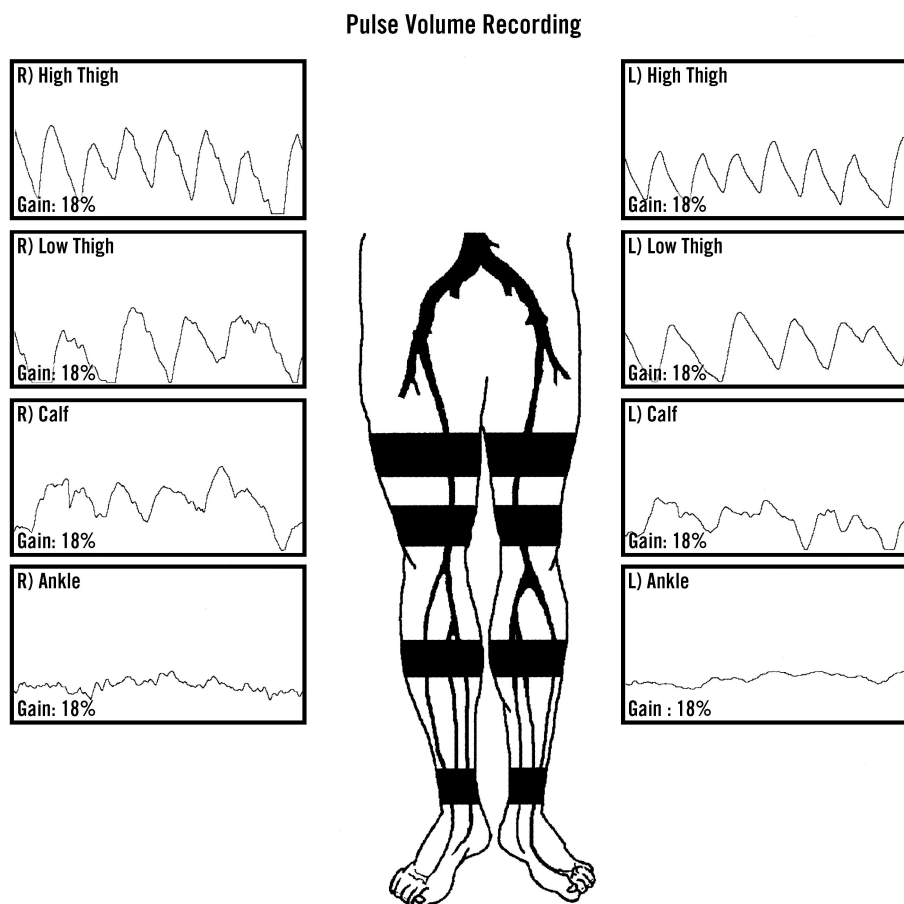


Figure 4 (Case 4). Noninvasive arterial study when first examined. Ankle brachial indices could not be obtained because bilateral dorsalis pedis and posterior tibial doppler signals were inaudible. A pulsed volume recording study documented severe, multisegmental occlusive disease, and essentially flat bilateral ankle waveforms were consistent with critical limb ischemia.

but the dorsalis pedis and posterior tibial pulses were absent.

Ankle-brachial indices were inaccurate as a result of calcified arteries and arterial Doppler-documented triphasic bilateral femoral and popliteal waveforms, with monophasic bilateral dorsalis pedis and posterior tibial waveforms. The bilateral transmetatarsal pulsed volume recording waveforms were severely dampened, and the hallux waveforms obtained after 5 minutes of external warming were flat, a finding documenting critical ischemia at the level of the forefoot and toes.

Although revascularization was offered as a treatment option, the patient requested an initial conservative approach to his care. As a result, cilostazol, 100 mg twice a day, was begun. Subsequently, the ulcerations and attendant rest pain slowly resolved within a 24-week period (Figure

5B). At a 3-month follow-up examination, no new ulcerations were found.

Discussion

Chronic critical limb ischemia defines a subset of patients with peripheral arterial occlusive disease that manifests with ischemic rest pain, ulcerations, or gangrene. Despite collateral vessel development and compensatory vasodilatation, in a patient with chronic critical limb ischemia, arterial perfusion is severely compromised and is not sufficient to meet the metabolic needs of the extremity. From a macrovascular standpoint, patients with chronic critical limb ischemia usually have multisegmental peripheral arterial occlusive disease. The microvascular circulation is impaired as well from a variety of mechanisms, including capillary collapse, arteriolar vasospasm, leukocyte activation and adhe-

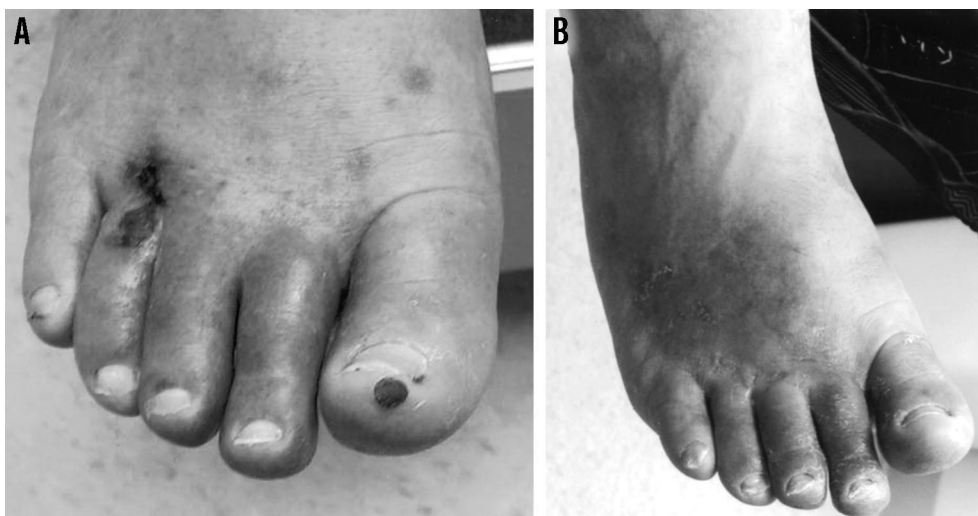

Figure 5 (Case 5). A. Ischemic-appearing ulcerations on right first and fourth toes. B. After receiving cilostazol for 24 weeks, the ulcers finally healed.

sion, platelet aggregation, and microthrombosis.¹ As a result, not only are patients with chronic critical limb ischemia functionally disabled, but they are also at high risk for limb loss and cardiovascular and cerebrovascular complications.

Corroborative noninvasive objective criteria for chronic critical limb ischemia include an ankle systolic pressure of 50 mm Hg or less and toe systolic pressure of 30 mm Hg or less.¹ If the patient has diabetes mellitus and arterial medial calcinosis, absolute pressure measurements might not be reliable or even obtainable. In such a case, a pulsed volume recording waveform of less than 5 mm² or a photoplethysmographic waveform of 4 mm or less is suggestive of chronic critical limb ischemia.³ Alternatively, a transcutaneous oxygen tension reading of 10 mm Hg or less in the supine position or 40 mm Hg or less while sitting suggests severe ischemia.⁴

Minimal data on the prevalence of chronic critical limb ischemia exists, although an incidence of 300 per million per year has been calculated⁵ by using intermittent claudication statistics (and assuming that 5% of patients with intermittent claudication progress to chronic critical limb ischemia within 5 years). Weitz et al⁶ estimated that 1%, or 20 million, of Americans older than 50 years might ultimately acquire chronic critical limb ischemia. Of 100 patients with intermittent claudication, at least 1 each year will progress to chronic critical limb ischemia.⁵

Risk factors for chronic critical limb ischemia parallel those of generalized atherosclerosis, although diabetes mellitus, smoking, and age assume the most importance.⁵ Diabetes is noteworthy because it underlies 50% to 70% of the amputations performed in the United States.^{7,8} Additionally, a diabetic patient with peripheral arterial occlusive disease is anywhere from 7 to 11 times more likely to require leg amputation.^{9,10} In Kannel's study,¹¹ 40% of diabetic patients with chronic critical limb ischemia progressed to gangrene, whereas only 9% of patients who were not diabetic had a similar outcome.

The prognosis for limb salvage as well as survival is frequently dismal in a patient with chronic critical limb ischemia. Within a 6-month period, 20% of patients die, 35% live but require amputation, and the remaining 45% live with no immediate need for amputation.⁵ In the United States, 150,000 leg amputations each year are performed for unremitting chronic critical limb ischemia.¹²

Effective treatment alternatives are traditionally restricted to endovascular or surgical revascularization. Neither surgical bypass nor percutaneous transluminal angioplasty might be technically possible, however, when the tibio-peroneal or below-knee arteries are severely diseased. Not uncommonly, the patient with chronic critical limb ischemia is typically affected by advanced tibio-peroneal arterial occlusive disease, especially if the patient has diabetes mellitus. In addition, comorbid

coronary, cerebral, and renal atherosclerosis can increase the risk of developing revascularization-associated complications. Although risk factor modification, proper foot care, antibiotics, and topical therapy for ulcerations are frequently warranted, these measures play more of an adjunctive role and are unlikely to be successful as primary therapy for chronic critical limb ischemia.

When revascularization is not possible, medical therapy is sometimes attempted. Anticoagulants, antiplatelet therapy, defibrinogenating agents,¹³ rheologic drugs,¹⁴ and prostanoids^{15,16} have been used for treatment of chronic critical limb ischemia. Unfortunately, none of these agents have produced major, long-term improvement in the critically ischemic limb. In their recent consensus document, the TASC Working Group noted, "because the results are unconvincing or negative, current drugs cannot be recommended in patients with chronic critical limb ischemia."¹⁷ As a group, prostanoids have received the most attention; however, the medication must be administered by prolonged intravenous infusion, and any improvement is only short term.

In 1988, cilostazol, a phosphodiesterase III inhibitor, was approved in Japan for the treatment of ulcerations, pain, and coldness associated with peripheral artery disease. In one study, the efficacy of cilostazol, 100 mg twice a day, was evaluated in a mixed cohort of patients with intractable skin ulcerations from a variety of causes that included severe peripheral artery disease. After 6 weeks, 48% of patients showed marked improvement, and only 19% worsened. The authors concluded that cilostazol might be useful in the treatment of skin ulcerations caused by vascular disease.¹⁸ In a group of 26 patients with arterial occlusive disease from varying causes (arteriosclerosis obliterans, Takayasu arteritis, and thromboangiitis obliterans), cilostazol, 200 mg each day, for 3 months improved ulcer healing and rest pain in 50% of the patients.¹⁹

Several studies have objectively documented increases in arterial perfusion after treatment with cilostazol. Money et al²⁰ documented a statistically significant increase in the posttreatment ankle-brachial index when cilostazol was compared with placebo (0.64–0.70 in the cilostazol group vs 0.68–0.69 in the placebo group, $P < .0125$). In a study of 9 patients with peripheral artery disease, cilostazol administered for 2 weeks increased the mean ankle blood flow by 16.2% ($P < .05$ vs baseline).²¹

Ohashi et al compared 100 mg with 200 mg of cilostazol each day for 6 weeks in 10 patients with peripheral artery disease. Significant increases in skin temperature and blood flow were documented in 7 of the 10 patients only when the higher dose was used.²²

The Food and Drug Administration approved cilostazol in 1999 as a new treatment option for intermittent claudication. In addition to its antiplatelet and antithrombotic properties, the agent induces vasodilatation, increases plasma high-density lipoprotein cholesterol, and decreases plasma triglycerides.²³ The precise mechanisms of action of the medication remain incompletely defined, however. It is known that cilostazol inhibits cyclic adenosine monophosphate (cAMP) phosphodiesterase III, resulting in decreased phosphodiesterase activity and suppression of cAMP degradation.²⁴ In turn, the level of cAMP in platelets and blood vessels is increased, leading to inhibition of platelet aggregation and to vasodilatation, respectively.

The patients described here were either not ideal candidates for invasive therapy or refused such an approach. Thus, the addition of a relatively new pharmacologic agent was a feasible option when the course of traditional supportive measures failed. Despite underlying chronic critical limb ischemia, between 7 and 24 weeks after starting cilostazol, the ischemic ulcerations completely healed in all 5 patients. Moreover, 3 patients experienced resolution of attendant ischemic rest pain. One patient erroneously discontinued cilostazol after his ulcer healed and subsequently developed a second ulcer after minor trauma to the right distal hallux. Resumption of cilostazol resulted in healing of the second ulcer within 2 months. Finally, a posttreatment noninvasive arterial study performed on 1 patient objectively illustrated improvement in both large and small arterial perfusion. All 5 patients have continued taking cilostazol and remain free of recurrent ulcerations during a follow-up period ranging from 2 to 12 months.

Primary care physicians often encounter similar patients. For instance, family physicians are sometimes asked to evaluate and treat ischemic foot and toe ulcerations in bedridden, demented patients residing in extended-care facilities (eg, case 4). These patients rarely warrant referral for aggressive interventional vascular therapy and are preferably managed with a conservative treatment approach that could include the use of cilostazol.

Considering the long-standing discouraging results of pharmacotherapy for chronic critical limb ischemia, the preliminary data showing the successful use of cilostazol in such patients are promising, and subsequent randomized, placebo controlled trials are warranted. To the best of our knowledge, our case series is the first report in the English literature investigating the use of cilostazol for treating lower extremity ischemic ulcerations.

References

1. Second European consensus document on chronic critical leg ischemia. *Circulation* 1991;84(4 Suppl): IV1-26.
2. Raines JK, Darling RC, Buth J, Brewster DC, Austen WG. Vascular laboratory criteria for the management of peripheral vascular disease of the lower extremities. *Surgery* 1976;79:21-9.
3. Carter SA, Tate RB. Value of toe pulse waves in addition to systolic pressures in the assessment of the severity of peripheral arterial disease and critical limb ischemia. *J Vasc Surg* 1996;24:258-65.
4. Carter SA. The challenge and importance of defining critical limb ischemia. *Vasc Med* 1997;2:126-31.
5. Dormandy JA, Rutherford RB. Management of peripheral arterial occlusive disease. A2. Epidemiology, natural history, risk factors. TASC Working Group. TransAtlantic Inter-Society Consensus (TASC). *J Vasc Surg* 2000;31(1 Pt 2):S5-34.
6. Weitz JI, Byrne J, Clagett GP, et al. Diagnosis and treatment of chronic arterial insufficiency of the lower extremities: a critical review. *Circulation* 1996; 94:3026-49.
7. Diabetes in the United States: a strategy for prevention: a progress report to the Technical Advisory Committee for Diabetes Translation and Community Control Programs. Atlanta, Ga: US Department of Health and Human Services, National Center for Chronic Disease Prevention and Health Promotion, Division of Diabetes Translation, 1992.
8. Report of the National Diabetes Advisory Board. Bethesda, Md: US Department of Health and Human Services, Public Health Service, National Institutes of Health, 1980. [NIH publication 81-2284.]
9. Jonason T, Ringqvist I. Factors of prognostic importance for subsequent rest pain in patients with intermittent claudication. *Acta Med Scand* 1985;218: 27-33
10. Da Silva A, Widmer LK, Ziegler HW, et al. The Basle longitudinal study: report on the relation of initial glucose level to baseline ECG abnormalities, peripheral artery disease, and subsequent mortality. *J Chronic Dis* 1979;95:577-80
11. Kannel WB. Risk factors for atherosclerotic cardiovascular outcomes in different arterial territories. *J Cardiovasc Risk* 1994;1:333-9.
12. Dormandy JA, Thomas PR. What is the natural history of a critically ischemic patient with and without his leg? In: Greenhalgh RM, Jamieson C, Nicolaides AN, editors. *Limb salvage and amputation for vascular disease*. 11th ed. Philadelphia: WB Saunders, 1998:11-26.
13. Tonnesen KH, Sager P, Gormsen J. Treatment of severe foot ischemia by defibrination with ancrod: a randomized blind study. *Scand J Clin Lab Invest* 1978;38:431-5.
14. Efficacy and clinical tolerance of parenteral pentoxifylline in the treatment of critical lower limb ischemia. A placebo controlled multicenter study. Norwegian Pentoxifylline Multicenter Trial Group. *Int Angiol* 1996;15:75-80.
15. Guilmot JL, Diot E, for the French Iloprost Study Group. Treatment of lower limb ischaemia due to atherosclerosis in diabetic and nondiabetic patients with iloprost, a stable analogue of prostacyclin: results of a French Multicentre trial. *Drug Invest* 1991; 3:351-9.
16. Prostanoids for chronic critical leg ischemia. A randomized, controlled, open-label trial with prostaglandin E1. The ICAI Study Group. *Ischemia Cronica degli Arti Inferiori*. *Ann Intern Med* 1999; 130:412-21.
17. Dormandy JA, Rutherford RB. Management of peripheral arterial occlusive disease. D4. Pharmacotherapy for critical limb ischemia. TASC Working Group. TransAtlantic Inter-Society Consensus (TASC). *J Vasc Surg* 2000;31(1 Pt 2): S197-203.
18. Arakawa K, Arada J. Clinical analysis of Pletal for intractable skin ulcer based on vascular damage and cutis symptom. *Shin'yaku to Rinsho (Journal of New Remedies & Clinics)* 1993;42(1):60-8.
19. Numano F, Kishi Y, Ashikaga T. Clinical studies of phosphodiesterase inhibitors for cardiovascular disease. *Adv Second Messenger Phosphoprotein Res* 1992;25:395-407.
20. Money SR, Herd JA, Isaacsohn JL, et al. Effect of cilostazol on walking distances in patients with intermittent claudication caused by peripheral vascular disease. *J Vasc Surg* 1998;27:267-75.
21. Kamiya T, Sakaguchi S. Hemodynamic effects of the antithrombotic drug cilostazol in chronic arterial occlusion in the extremities. *Arzneimittelforschung* 1985;35(7A):1201-3.
22. Ohashi S, Iwatani M, Hyakuna Y, Morioka Y. Thermographic evaluation of the hemodynamic effect of the antithrombotic drug cilostazol in peripheral arterial occlusion. *Arzneimittelforschung* 1985;35: 1203-8.
23. Elam MB, Heckman J, Crouse JR, et al. Effect of the novel antiplatelet agent cilostazol on plasma lipoproteins in patients with intermittent claudication. *Arterioscler Thromb Vasc Biol* 1998;18:1942-7.
24. Sorkin EM, Markham A. Cilostazol. *Drugs Aging* 1999;14:63-71.