

## BRIEF REPORTS

# Horner Syndrome from the Dentist's Chair

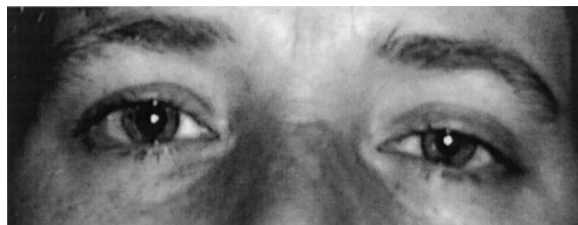
Cary Ostergaard, MD, and Dennis J. Faix, MD

Horner syndrome results from a disruption of the sympathetic nervous system input to the eye and orbit. Many causes have been described, including thoracostomy tubes,<sup>1</sup> carotid artery dissection,<sup>2</sup> herpes zoster ophthalmicus,<sup>3</sup> various headache syndromes,<sup>4</sup> Pancoast tumor,<sup>5</sup> head and neck surgery, and local trauma.<sup>6,7</sup> In the medical literature, Horner syndrome has been reported as a sequela of prolonged positioning, twice as a result of general anesthesia,<sup>8</sup> and once as a result of an alcohol-induced coma.<sup>9</sup> We report a case of Horner syndrome in a conscious patient resulting from a visit to the dentist's chair.

### Case Report

A 39-year-old woman came to our clinic with a chief complaint of left pupillary constriction and a left drooping eyelid that had been noticed by her co-workers. She was in her normal state of health the previous day, when dental work was performed on a left upper molar and premolar. The dental procedure lasted approximately 2 hours and involved only local anesthesia (3.6 mL 1% lidocaine with epinephrine). There was no history of other orofacial trauma. She had some facial pain attributed to the dental work, but she denied neck pain, pulmonary symptoms, or other neurologic symptoms.

Examination findings were remarkable for an obvious left ptosis and anisocoria (3 mm left eye, 5 mm right eye in dim lighting [Figure 1]). Facial anhidrosis was not assessed. Visual acuity and fundoscopic examination findings were normal, as were findings from head and neck, pulmonary, and neurologic examinations. There was no dental or oral numbness at the time of examination. Cocaine stimulation test confirmed the diagnosis of Horner



**Figure 1.** The patient at initial examination showing evidence of anisocoria and ptosis of Horner syndrome.

syndrome (3 mm left eye, 7.5 mm right eye). Results of a chest radiograph and head and neck computed tomographic (CT) scans were unremarkable. All blood chemistries including white cell count and erythrocyte sedimentation rate were within normal limits. Subsequently, the lesion was localized to the third-order postganglionic neuron by hydroxyamphetamine testing.

Symptoms resolved almost completely during the next several weeks. Ten months after she was initially examined, the patient had normal findings on examination except for a minimal ptosis and a 2.0-mm anisocoria with cocaine stimulation.

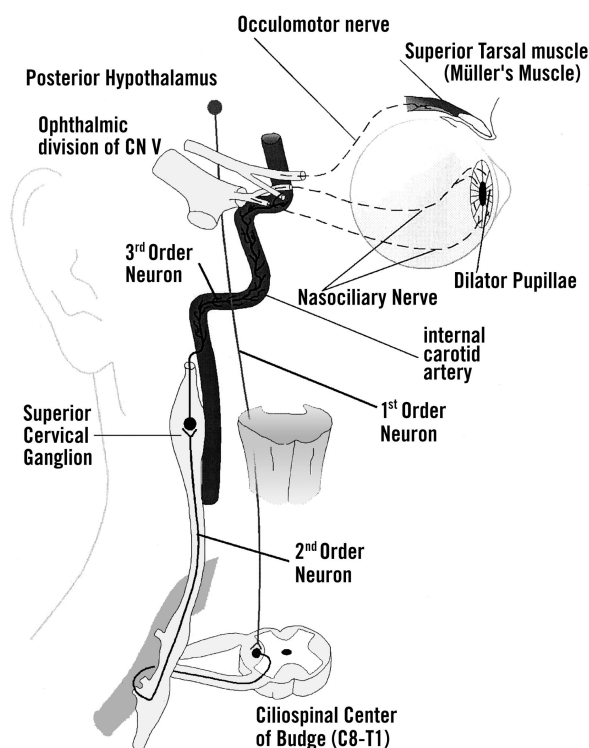
### Discussion

As is often the case, understanding the basic anatomy and physiology provides a basis for establishing a differential diagnosis and guides the primary care physician in establishing the proper workup.

The sympathetic nerve supply to the eye and orbit is a three-neuron system that begins in the posterior hypothalamus, travels uncrossed through the neck, and back up to the end organs (Figure 2).<sup>10,11</sup> Disruption of this sympathetic flow to the eye and orbit will result in a loss of sympathetic tone to the dilator pupillae muscle, resulting in miosis, and to the Müller muscle, resulting in ptosis. Localizing the lesion can help guide the differential diagnosis. Central, or first-order, neuron lesions can be caused by brainstem disease (multiple sclerosis), syringomyelia, lateral medullary (Wallenberg) syndrome, or spinal cord tumors. Pregang-

Submitted, revised, 24 January 2001.

Family Practice (CO, DJF), Branch Medical Clinic, Iwakuni Japan, Yokosuka Naval Hospital, United States Navy. Address reprint requests to Dennis J. Faix, MD, 4301 Jones Bridge Rd, Bethesda, MD 20814-4799.

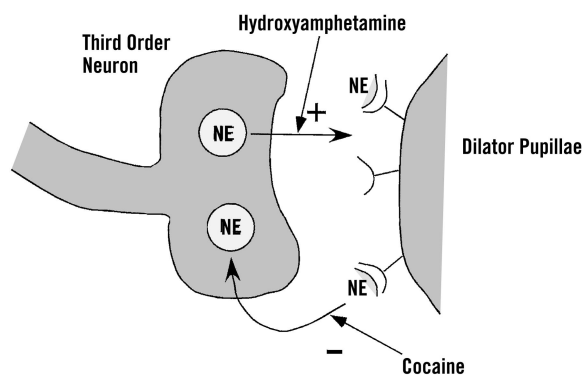


**Figure 2.** Sympathetic innervation of the eye and orbit.

glinic, second-order neuron lesions can be caused by Pancoast tumor, carotid dissection, or aneurysm and other neck lesions. Lastly, postganglionic or third-order neuron lesions can be caused by internal carotid artery disease, nasopharyngeal tumors, cavernous sinus mass, cluster headache, or even otitis media.<sup>12</sup>

The primary care physician, before embarking on a diagnostic adventure to sort out the above causes, needs to confirm the diagnosis of Horner syndrome. The diagnosis of Horner syndrome can be confirmed with the topical application of a cocaine solution.<sup>13</sup> This solution acts to potentiate any sympathetic outflow by blocking the reuptake of norepinephrine,<sup>14</sup> increasing the already present anisocoria. Although the cocaine challenge test can reliably confirm Horner syndrome, it cannot help localize the offending lesion.<sup>15</sup>

Further pharmacologic testing can differentiate between a preganglionic or postganglionic lesion (Figure 3).<sup>16</sup> A lack of mydriasis with the hydroxyamphetamine test is a strong indicator of a third-order (postganglionic) lesion, whereas a mydriatic response does not necessarily rule out a postganglionic lesion.<sup>17</sup> Note that within the first week of injury, it is possible to falsely interpret the hydroxy-



**Figure 3.** Pharmacologic testing helps establish a differential diagnosis and can affect the workup and treatment.<sup>18</sup> Cocaine prevents reuptake of norepinephrine at the terminal end of the third-order neuron and causes mydriasis if the sympathetic system is intact. Hydroxyamphetamine or pholedrine<sup>19</sup> causes release of norepinephrine from the terminal end of the third-order neuron. If the third-order neuron is damaged and not producing norepinephrine, a mydriatic response will be absent after stimulation with these agents.

amphetamine test as indicating a preganglionic lesion because the dying nerve can still have some norepinephrine stores. Furthermore, hydroxyamphetamine testing must be performed at least 48 hours after the cocaine stimulation test, as the cocaine can interfere with the results.

After confirmation of Horner syndrome with cocaine testing, and before further pharmacologic testing 2 to 7 days later to localize the lesion, additional diagnostic tests should be considered. If history and physical examination do not indicate a clear cause, then a chest radiograph, possibly with lordotic views, should be performed looking for a Pancoast tumor. If the chest radiograph is negative, magnetic resonance imaging (MRI) and angiography (or CT with contrast media if MRI and angiography are unavailable) of the head and neck should be performed to rule out lesions that might require urgent attention, such as carotid dissection. Obviously, if the imaging clearly indicates the cause, then there might be no need for further localization with hydroxyamphetamine.

In our patient, 4 weeks after her initial complaint, there was no pupillary response to the application of hydroxyamphetamine, indicating a postganglionic lesion. Postganglionic lesions are usually secondary to benign causes. With this in-

formation and the subsequent improvement in our patient, no further workup was indicated.

In the available medical literature, Horner syndrome has twice been described as a sequela of surgery (caused by positioning during general anesthesia),<sup>8</sup> and once as a result of an ethanol-induced coma (again caused by positioning).<sup>9</sup> The assumed mechanism for this appears to be ischemia or direct trauma to the postganglionic fibers traveling along the carotid artery, possibly as a result of traction of the sympathetic chain or compression against the cervical vertebrae. Testing in our patient localized the lesion to the postganglionic fibers. This injury was presumably secondary to prolonged positioning of the head and neck in an extended position while in the dental chair. It is unlikely that the local anesthetic caused the lesion, because it was given in an area well away from the normal anatomic path for the sympathetic innervation of the eye and orbit.

As expected with this type of lesion, our patient's symptoms were transient. To our knowledge, Horner syndrome has never been reported as a result of a positioning in a conscious patient. In this case, a dental procedure resulted in the patient's head being positioned in such a way as to cause a transient Horner syndrome.

## References

1. Pearce SH, Rees CJ, Smith RH. Horner's syndrome: an unusual iatrogenic complication of pneumothorax. *Br J Clin Pract* 1995;49:48.
2. Leira EC, Bendixen BH, Kardon RH, Adams HP. Brief, transient Horner's syndrome can be the hallmark of a carotid artery dissection. *Neurology* 1998;50:289-90.
3. Smith EF, Santamarina L, Wolintz AH. Herpes zoster ophthalmicus as a cause of Horner syndrome. *J Clin Neuroophthalmol* 1993;13:250-3.
4. Fields CR, Barker FM. Review of Horner's syndrome and a case report. *Optom Vis Sci* 1992;69:481-5.
5. Bosch X, Vera M. Pancoast's syndrome. *N Engl J Med* 1998;338:765-6.
6. Oono S, Saito I, Inukai G, Morisawa K. Traumatic Horner syndrome without anhidrosis. *J Neuroophthalmol* 1999;19:148-51.
7. Liu GT, Deskin RW, Bienfang DC. Horner's syndrome caused by intra-oral trauma. *J Clin Neuroophthalmol* 1992;12:110-5.
8. Jaffe TB, McLeskey CH. Position-induced Horner's syndrome. *Anesthesiology* 1982;56:49-50.
9. Thompson CG. Horner's syndrome resulting from a prolonged abnormal posture during a coma. *Aust N Z J Ophthalmol* 1998;26:165-7.
10. Netter FH. *Atlas of human anatomy*. Summit, NJ: Ciba-Geigy, 1989.
11. Yanoff M, Duker JS, Augsburger JJ, et al. *Ophthalmology*. Philadelphia: Mosby, 1999.
12. Keane JR. Oculosympathetic paresis. Analysis of 100 hospitalized patients. *Arch Neurol* 1979;36:13-5.
13. Kardon RH, Denison CE, Brown CK, Thompson HS. Critical evaluation of the cocaine test in the diagnosis of Horner's syndrome. *Arch Ophthalmol* 1990;108:384-7.
14. Gilman & Goodman's the pharmacological basis of therapeutics. New York: McGraw-Hill, Health Professions Division, 1996.
15. Van der Wiel HL, Van Gijn J. The diagnosis of Horner's syndrome. Use and limitations of the cocaine test. *J Neurol Sci* 1986;73:311-6.
16. Cremer SA, Thompson HS, Digre KB, Kardon RH. Hydroxyamphetamine mydriasis in Horner's syndrome. *Am J Ophthalmol* 1990;110:71-6.
17. Van der Wiel HL, Van Gijn J. Localization of Horner's syndrome. Use and limitations of the hydroxyamphetamine test. *J Neurol Sci* 1983;59:229-35.
18. Thompson HS. Diagnosing Horner's syndrome. *Trans Am Acad Ophthalmol Otolaryngol* 1977;83:840-2.
19. Bates AT, Chamberlain S, Champion M, et al. Pholedrine: a substitute for hydroxyamphetamine as a diagnostic eyedrop test in Horner's syndrome. *J Neurol Neurosurg Psychiatry* 1995;58:215-7.