

Fallopian Tube Torsion: Laparoscopic Evaluation and Treatment of a Rare Gynecological Entity

Haim Krissi, MD, Josef Shalev, MD, Itai Bar-Hava, MD, Rami Langer, MD, Arie Herman, MD, and Boris Kaplan, MD

Background: Fallopian tube torsion is a cause for acute low abdominal pain that is difficult to diagnose. The purpose of this article is to review the available data on and to update clinicians regarding its diagnosis and treatment in the era of laparoscopic surgery.

Methods: We searched in MEDLINE and EMBASE and reviewed the lists of references. The keywords used were “laparoscopy,” “fallopian tube,” and “torsion.”

Results and Conclusion: Fallopian tube torsion is an uncommon cause for acute low abdominal pain in women. Because it has no pathognomonic clinical symptoms or findings on imaging or laboratory studies, a history of current or past pelvic pathologic conditions or surgery, as well as pregnancy, should draw the attention of the attending physician to its occurrence. Early laparoscopy is the reference standard in the diagnosis and treatment. (*J Am Board Fam Pract* 2001;14:274–7.)

Fallopian tube torsion is a rare gynecologic cause of acute low abdominal pain. Several hundred cases have been reported in the literature since the original description by Bland-Sutton in 1890.¹ The lack of pathognomonic symptoms, clinical findings on physical examination, and specific imaging or laboratory characteristics makes this entity difficult to diagnose preoperatively, which can cause surgical intervention to be postponed. In the past surgical repair was performed by laparotomy. The introduction of laparoscopy for routine use in gynecology has changed the approach to both the diagnosis and treatment of fallopian tube torsion.

The purpose of this article is to review the available data on this rare entity and to update clinicians regarding its diagnosis and treatment in the era of laparoscopic surgery.

Methods

We searched in MEDLINE and EMBASE and reviewed the lists of references in the original arti-

cles. The keywords used were “laparoscopy,” “fallopian tube,” and “torsion.”

Etiology

The exact cause of fallopian tube torsion is unknown. Some studies have postulated theoretical explanations. Torsion is unlikely with an intact tube and is more often the result of an ovarian cyst or tumor. Regad² surveyed 201 cases of fallopian tube torsion and found a normal appearance in only 24%. In many of the patients, no pathologic reports were available. Hydrosalpinx was found in 18%, and infection in 13%. Pelvic tumor and normal or ectopic pregnancy were reported in the remainder. It is noteworthy that in 12% of these cases, the diagnosis of fallopian tube torsion was made during a normal intrauterine pregnancy. Since Regad's report, 14 additional cases of tubal torsion during pregnancy have been described.^{3–5} Fallopian tube torsion has also been described after surgical sterilization (mainly with the use of the Pomeroy technique^{6–10}), in primary carcinoma of the fallopian tube,¹¹ with hematosalpinx,¹² during labor,¹³ and in a premenarchal girl with endometriosis.¹⁴

Youssef et al¹⁵ noted factors that could possibly influence the occurrence of fallopian tube torsion and divided them into two types: internal and external (Table 1). Taken together, the existing reports indicate that the mechanism underlying tubal

Submitted, revised, 3 January 2001.

From the Department of Obstetrics and Gynecology (HK, JS, IB, RL, AH, BK), Rabin Medical Center, Beilinson Campus, Petah Tiqva, and Sackler Faculty of Medicine, Tel Aviv University, Tel Aviv, Israel. Address reprint requests to Boris Kaplan, MD, Department of Obstetrics and Gynecology, Rabin Medical Center, Beilinson Campus, Petah Tiqva 49100, Israel.

Table 1. Intrinsic and Extrinsic Causes of Fallopian Tube Torsion.

<i>Intrinsic</i>	
Congenital anomalies	Excessive length of tube or spiral course
Acquired pathology	
	Hydrosalpinx, hematosalpinx, neoplasm, surgery
Autonomic dysfunction and abnormal peristalsis	
<i>Extrinsic</i>	
Changes in the neighboring organs	
	Neoplasm, adhesions, pregnancy
Mechanical factors	
Movement or trauma to the pelvic organs	
Pelvic congestion	

Table 2. Possible Mechanisms for Tubal Torsion.

Mechanical disturbance
Venous obstruction
Lymphatic congestion
Diffuse edema
Tubal enlargement
Tubal torsion

torsion is apparently a sequential mechanical event.¹⁶ The process begins with the mechanical blockage of the adnexal veins and lymphatic vessels by ovarian tumor, pregnancy, hydrosalpinx and pelvic adhesions after tubal infection, or pelvic operation. This obstruction causes pelvic congestion and local edema, with subsequent enlargement of the adnexa, which in turn induces partial or complete torsion (Table 2). Furthermore, the mechanical blockage of the distal part of the fallopian tubes, together with the normal secretion of the fallopian tube glands, can cause hydrosalpinx, a risk factor by itself for torsion.

The incidence of fallopian tube torsion is unknown, and only sporadic cases are reported each year. It rarely occurs before menarche or during menopause.¹⁷⁻²⁰ This dispersion of frequencies apparently is because most risk factors for tubal torsion, such as ovarian cysts, infections, and pelvic surgery, occur mainly in the reproductive age-group.

Clinical Manifestations

The most common symptom of fallopian tube torsion is convulsive pain at the waist or pelvis, projecting to the side of the tubal torsion. The pain

tends to increase with time and to radiate to the thigh, with rebound tenderness and some stiffness of the abdomen on the affected side. It is often accompanied by gastrointestinal symptoms, such as nausea and vomiting, and urinary frequency and urgency with voiding difficulties. Intestinal peristalsis is usually normal. A sensitive adnexal mass might be found during a vaginal examination. Cervical motion tenderness can mimic tuboovarian abscess or pelvic inflammatory disease.²¹ The lack of specificity of the clinical signs and symptoms and the numerous pathologic findings in the pelvis and lower abdomen often fail to alert the physician to the condition, making diagnosis difficult.^{15,22,23}

Evaluation and Treatment

A medical history of ovarian or fallopian tube disease, along with the symptoms described above, is an important consideration. The available laboratory or imaging studies cannot confirm fallopian tube torsion. They can, however, rule out other abdominal conditions with similar clinical characteristics, such as nephrolithiasis, cholelithiasis, appendicitis, extrauterine pregnancy, tubo-ovarian abscess, and pancreatitis. In our center, patients with a differential diagnosis of fallopian tube torsion routinely undergo a complete physical and vaginal examination, color Doppler transvaginal sonography (Figure 1), and other imaging and laboratory studies (abdominal sonography or radiographs, intravenous pyelography, complete blood count, serum amylase and liver enzyme measurements, and so on). The finding of high impedance or absence of flow in a tubular structure, especially in a patient with a history of tubal ligation, can be indicative of the diagnosis.^{24,25} Before laparotomy, culdocentesis had been suggested to determine whether there was intraperitoneal bleeding. This technique has been replaced by laparoscopy, which is currently the most specific diagnostic tool for evaluating torsion. The definitive diagnosis of tubal torsion is still made retrospectively, usually after diagnostic laparoscopy.

At the present time, laparoscopic adnexal detorsion, not adnexectomy, is the procedure of choice. Because most of the patients are in their reproductive years, efforts should be made to preserve fertility if the ischemic damage appears to be reversible, and no malignancy is suspected. A complete resection is performed when the tissue is gangre-

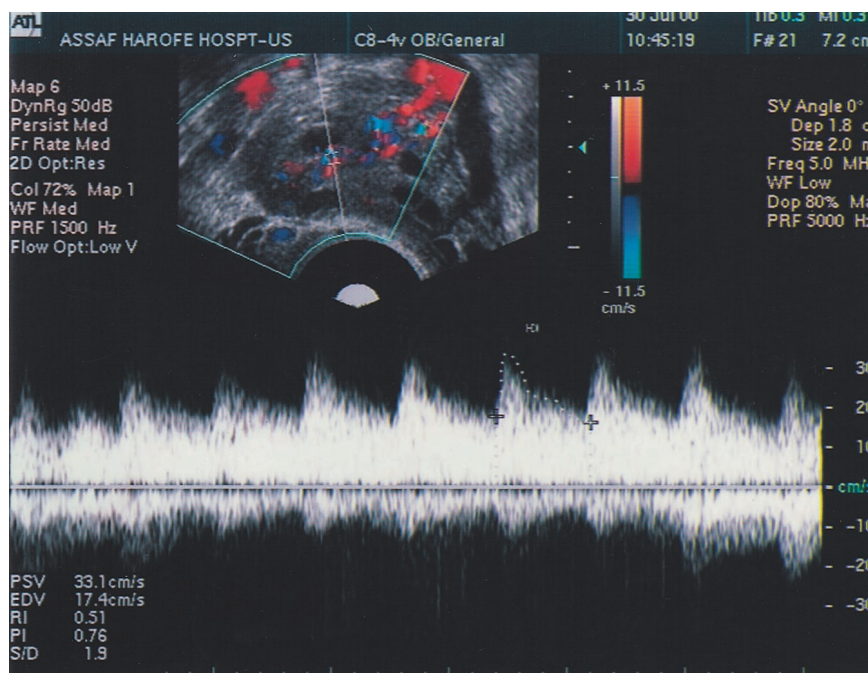


Figure 1. Normal adnexal blood flow, displayed by color Doppler transvaginal ultrasonography. Red indicates flow toward the transducer, and blue, away from it. The Doppler pattern can differentiate between arterial and venous flow by the pulsation pattern (continuous nonpulsative flow indicates a venous flow). Absence of flow, in addition to the clinical symptoms, raises the possibility of adnexal torsion.

nous, there is a tubal or ovarian neoplasm, or the woman has completed her family. When there is no apparent ischemic damage, most of the twisted adnexa regain their function.

Recovery is much faster after laparoscopy than after laparotomy. Laparoscopy also causes fewer pelvic adhesions, which is especially important for women of reproductive age who wish to preserve their fertility. Compared with laparotomy, laparoscopy (especially if performed in the second trimester) provides a better chance for the successful continuation of a pregnancy. If the patient is in her third trimester, most surgeons prefer laparotomy, because laparoscopy is technically very difficult. The main complications associated with the operation are from the effects of general anesthesia, bleeding, perforation of hollow viscera or blood vessels, infection, herniation from the trocar entry port, abortion, or preterm delivery.

We would like to emphasize that most of the studies are case reports of laparotomy and adnexectomy, many of them without histologic confirmation. Further research is needed regarding some of the unanswered questions about the percentage

of the preserved tubes that progress to gangrene, future fertility, and pregnancy outcome.

Conclusion

Fallopian tube torsion is an uncommon cause for acute low abdominal pain in women. Because it has no pathognomonic clinical symptoms or findings on imaging or laboratory studies, a history of current or previous pelvic pathologic conditions or surgery, as well as pregnancy, should draw the attention of the attending physician to its occurrence. Early laparoscopy is the reference standard in the diagnosis and treatment.

References

1. Bland-Sutton T. Salpingitis and some of its effects. *Lancet* 1890;2:1146.
2. Regad J. Etude anatomo-pathologique de la torsion des trompettes uterines. *Gynecol Obstet* 1933;27:519-35.
3. Savage JE. Twisted hematosalpinx complicating pregnancy. *Am J Obstet Gynecol* 1936;32:1043-7.
4. Caldwell RK. Torsion of normal fallopian tube pregnancy. *N Engl J Med* 1949;240:421-2.
5. Kushner DH, Rosenbaum M. Torsion of fallopian

- tube complicating pregnancy. *Am J Obstet Gynecol* 1952;64:935.
6. Muldoon MJ. Gynaecological illness after sterilization. *Br Med J* 1972;1:84–5.
 7. Neil JR, Hammond GT, Noble AD, Rushton L, Letchworth AT. Late complications of sterilization by laparoscopy and tubal ligation. A controlled study. *Lancet* 1975;2:699–700.
 8. Shapiro HI, Hughes WF, Adler DH. Torsion of the oviduct following laparoscopic sterilization. *Am J Obstet Gynecol* 1976;126:733–4.
 9. Krissi H, Orvieto R, Dicker D, Dekel A, Ben Rafael Z. Torsion of a fallopian tube following Pomeroy tubal ligation: a rare case report and review of the literature. *Eur J Obstet Reprod Biol* 1997;72:107–9.
 10. Gerald CK. Torsion of uterine tube following Pomeroy sterilization. *Obstet Gynecol* 1956;7:396–8.
 11. Sanyal R, Chakraborty A, Ghosh D. Primary carcinoma of the fallopian tube with torsion. *J Indian Med Assoc* 1989;87:145–6.
 12. Furui T, Imai A, Yokoyama Y, Tamaya T. Hematosalpinx and torsion of the fallopian tube in a virgin girl. *Gynecol Obstet Invest* 1993;35:123–5.
 13. Sorem KA, Bengtson JM, Walsh B. Isolated fallopian tube torsion presenting in labor. A case report. *J Reprod Med* 1991;36:763–4.
 14. Peng T, Parmley TH, Genadry R. Endometriosis and perimenarchal tubal torsion. A case report. *J Reprod Med* 1989;34:934–6.
 15. Youssef AF, Fayad MM, Shafeek MA. Torsion of the fallopian tube. A clinico-pathological study. *Acta Obstet Gynec Scand* 1962;41:292–309.
 16. Bernardus RE, Van der Slikke JW, Roex AJ, Dijkhuizen GH, Stolk JG. Torsion of the fallopian tube: some considerations on its etiology. *Obstet Gynecol* 1984;64:675–8.
 17. Kurzbart E, Mares AJ, Cohen Z, Mordehai J, Finaly R. Isolated torsion of the fallopian tube in premenarcheal girls. *J Pediatr Surg* 1994;29:1384–5.
 18. Ward MJ, Frazier TG. Torsion of the normal uterine adnexa in childhood: case report. *Pediatrics* 1978;61:573–4.
 19. Evans JP. Torsion of the normal uterine adnexa in premenarchal girls. *J Pediatr Surg* 1978;13:195–6.
 20. Powell JL, Foley GP, Llorens AS. Torsion of the Fallopian tube in postmenopausal women. *Am J Obstet Gynecol* 1972;113:115–8.
 21. Maynard SR, Peipert JF, Brody JM. Tubal torsion appearing as acute pelvic inflammatory disease. *J Am Assoc Gynecol Laparosc* 1996;3:431–3.
 22. Hansen OH. Isolated torsion of the Fallopian tube. *Acta Obstet Gynecol Scand* 1970;49:3–6.
 23. James J, Powell JL, Martin C. A case of torsion of a fallopian tube. *Gynecol Endosc* 1996;5:301–2.
 24. Baumgartel PB, Fleischer AC, Cullinan JA, Bluth RF. Color Doppler sonography of tubal torsion. *Ultrasound Obstet Gynecol* 1996;7:367–70.
 25. Elchalal U, Caspi B, Schachter M, Borenstein R. Isolated tubal torsion: clinical and ultrasonographic correlation. *J Ultrasound Med* 1993;12:115–7.