

# Paraesophageal Hernia and Intrathoracic Diverticulitis

Michael K. Magill, MD, and Christine Gazak, MA, MPH

Paraesophageal hernia is a potentially lethal condition that has not been previously discussed in the family medicine literature. It accounts for 3.5% to 5%<sup>1</sup> of all hiatal hernias. Diagnosis of paraesophageal hernia can be difficult. Patients are usually elderly and have symptoms of esophageal reflux or postprandial pain, bloating, and vomiting. The patient might have a history of hiatal hernia.

We report here a case of paraesophageal hernia, complicated by herniation of colon into the thorax, with intrathoracic diverticulosis, probable diverticulitis, and myocardial infarction. Family physicians should be aware of the symptoms of paraesophageal hernia so they can promptly diagnose and manage this potentially lethal condition.

## Case Report

A 90-year-old man was admitted to a community hospital complaining of abdominal pain. The pain was located in the left upper quadrant of the abdomen, and he described it as steady and "aggravating." He had no associated fever and did not report a history of esophageal reflux-type symptoms, but he did have several episodes of vomiting nonbloody fluid. There was no associated diarrhea, constipation, melena, or hematochezia.

The patient also complained of intermittent, poorly characterized pain in his left lower anterior thorax, which he said was different from his abdominal pain. He denied exertional chest pain but did complain of shortness of breath when walking up one flight of stairs. He denied orthopnea, paroxysmal nocturnal dyspnea, and edema.

He had been released from the hospital 8 days earlier after a 4-day admission for nausea, decreased appetite, and weight loss. At that time he had been given antibiotics for presumed diverticu-

litis. Although he improved initially, he developed increasing pain despite continued outpatient treatment with metronidazole and ciprofloxacin.

His medical history was notable for a myocardial infarction approximately 7 years earlier, which had been well tolerated. He had a right bundle branch block of uncertain duration. He also had a history of deep venous thrombosis for which he had recently begun taking warfarin.

At admission his respiratory rate was 24/min, pulse 90 beats per minute and regular, blood pressure 90/60 mm Hg. He was initially alert and oriented. His lips were moderately cyanotic, and oxygen saturation was 94% on 3 L of oxygen by nasal cannula. His lungs were clear to auscultation, and his heart had no murmurs or gallops. During his abdominal examination, he had normal bowel sounds and no distention or tenderness to palpitation.

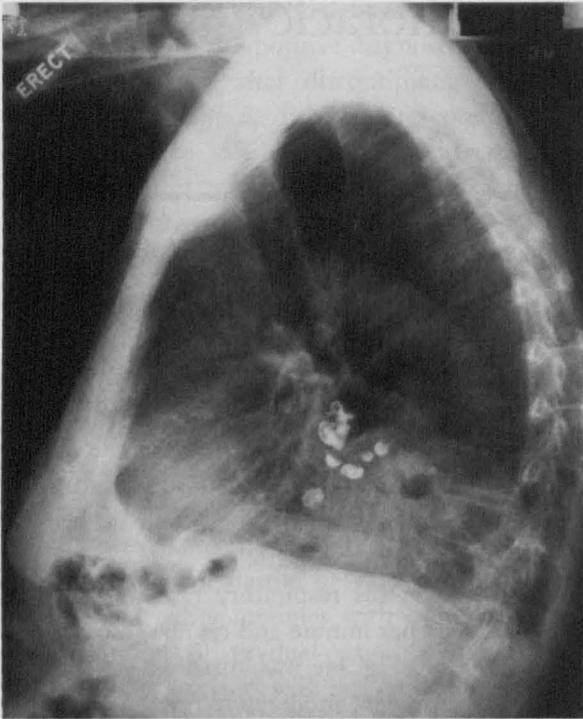
The initial laboratory evaluation included a white blood cell count of 15,200/ $\mu$ L with a left shift. His international normalized ratio was 1.1. His serum creatine kinase was 161 U/L with an MB fraction of 12.5%. An electrocardiogram showed a right bundle branch block with evidence of old myocardial injury. The chest radiograph showed a large hiatal hernia and barium retained from a previous radiologic examination in diverticulae located both above and below the diaphragm (Figure 1).

The patient was presumed to have a paraesophageal hernia, recurrent diverticulitis, and new-onset myocardial infarction. The diverticulitis was thought to be located in the intrathoracic bowel in view of the benign findings of the abdominal examination. During his hospitalization the patient showed fluctuating orientation and memory, thought to represent dementia. The family requested that no aggressive treatment be performed, and the patient was given antibiotics until his abdominal pain improved. He did not develop signs of bowel obstruction and was released from the hospital.

---

Submitted, revised, 2 May 1999.

From the Department of Family and Preventive Medicine (MKM, CG), University of Utah School of Medicine, Salt Lake City. Reprints are not available.



**Figure 1.** Chest radiograph showing large hiatal hernia and barium located in diverticula above and below the diaphragm.

## Discussion

Hiatal hernias occur as three major types: type I, the classic sliding hiatal hernia in which the esophago-gastric junction is located above the diaphragm; type II, in which the esophago-gastric junction remains below the diaphragm but the fundus of the stomach is prolapsed above the diaphragm; and type III, a mixed type in which both the esophago-gastric junction and some or all the stomach are above the diaphragm, but in which the esophago-gastric junction remains more caudal than the fundus.<sup>2-4</sup> Most paraesophageal hernias are type III; type II is relatively uncommon.

The hernia is due to attenuation of the anterior and lateral components of the phrenicoesophageal fascial complex. The resulting weakness in the muscle fibers creates mobility and instability within the hiatus, which allows for herniation into the mediastinum of the stomach, the transverse colon, and on rare occasions the entire bowel or other intraabdominal organs, such as the spleen.

Listerud and Harkins<sup>5</sup> described 11 muscle variations in the formation of an esophageal hiatus. In more than 90% of the reported cases, the hiatus is produced from the right crus. Documentation of

rarer cases of paraesophageal hiatal hernias in which the transverse colon might be involved include a report of a patient who had a paraesophageal hernia in which herniation of the splenic flexure led to colonic obstruction.<sup>6</sup> Another report described a rarer event in which a hernia through the aortic hiatus allowed passage of first the stomach and then the colon through the diaphragm.<sup>7</sup>

Paraesophageal hiatal hernias can occur, though very seldom, as congenital problems diagnosed in infancy.<sup>8</sup> They are found predominately as acquired problems in the elderly. Patients might complain of reflux, epigastric pressure or pain, postprandial vomiting of food, postprandial dyspnea, anemia, or symptoms of intermittent volvulus.<sup>9</sup> When the symptoms and signs of paraesophageal hernia include sudden onset of abdominal pain and vomiting, they are likely a result of strangulation of herniated stomach or bowel, which is a medical emergency.

Although paraesophageal hernias account for only 5% of all hiatal hernias, they are dangerous because symptoms can be nonspecific, leading to delays in diagnosis and resultant morbidity or mortality. Paraesophageal hernia should be suspected in elderly patients who have symptoms ranging from heartburn and vague abdominal discomfort to vomiting and severe pain. These patients might have few or no localizing abdominal findings on physical examination, but they have evidence of hiatal hernia on chest radiographs. Wo et al<sup>10</sup> recommended that patients with heartburn, plus postprandial distress (pain in the epigastrium or chest, dyspnea, nausea or vomiting during or after eating), be suspected of having paraesophageal hernia, especially type III, rather than simply the more common sliding hiatal hernia (type I).

The finding of a stomach-type air-fluid level or large-bowel gas pattern within the mediastinum should further raise suspicion of a paraesophageal rather than sliding hiatal hernia. The differential diagnosis for mediastinal masses occurring with similar appearance includes pericardial effusion or cyst, bronchogenic cyst, or esophageal diverticulum.<sup>11</sup> Upper gastrointestinal endoscopy can establish the diagnosis, but a type III hernia is often missed by endoscopy. Barium esophagogram might be necessary to confirm a type III hernia.<sup>10</sup>

Most authors recommend surgical repair of paraesophageal hernias at the time of diagnosis because of the risk of strangulation and its high



mortality rate.<sup>12</sup> Older case series included large proportions of emergency procedures. For example, of 29 patients with paraesophageal hernias reported by Hill,<sup>13</sup> 10 required emergency surgical repair of the strangulation and obstruction, and 2 of those cases resulted in death. More recent series have described much better elective surgical outcomes, particularly those in which repair is accomplished laparoscopically.<sup>9,14-16</sup> Successful emergency laparoscopic repair has also been described.<sup>17</sup> In some instances, symptoms have been present for many years, and the patient might be unwilling to undergo surgery to correct the condition. Some have suggested that the risk of emergency complications of hiatal hernias might be lower than generally believed, given the occasional patient in whom bowel is only incidentally identified in the thorax.<sup>18</sup>

In the case reported here, nonsurgical management was considered to be appropriate because of the advanced age of the patient, the patient's early dementia, and family refusal. The patient did not develop symptoms or signs of bowel obstruction. His initial abdominal pain was believed to represent referred pain from intrathoracic diverticulitis that improved with antibiotic treatment.

## References

1. Kafka NJ, Leitman IM, Tromba J. Acute pancreatitis secondary to incarcerated paraesophageal hernia. *Surgery* 1994;115:653-5.
2. Ellis FH Jr, Crozier RE, Shea JA. Paraesophageal hiatus hernia. *Arch Surg* 1986;121:416-20.
3. Ellis FH Jr. Diaphragmatic hiatal hernias. Recognizing and treating the major types. *Postgrad Med* 1990;88:113-4, 117-20, 123-4.
4. Mittal RK. Hiatal hernia: myth or reality? *Am J Med* 1997;103(5A):33S-39S.
5. Listerud MD, Harkins HN. Anatomy of the esophageal hiatus. *Arch Surgery* 1958;76:835-42.
6. Farrell B, Gerard PS, Bryk D. Paraesophageal hernia causing colonic obstruction. *J Clin Gastroenterol* 1991;13:188-90.
7. Wagner RB, Barry MJ, Manney MS. Sequential herniation of stomach, then colon through the aortic hiatus. *South Med J* 1997;90:338-40.
8. Jawad A, al-Samarrai AI, al-Mofada S, et al. Congenital para-oesophageal hiatal hernia in infancy. *Pediatr Surg Int* 1998;13(2-3):91-4.
9. Hawasli A, Zonca S. Laparoscopic repair of paraesophageal hiatal hernia. *Am Surg* 1998;64:703-10.
10. Wo JM, Branum GD, Hunter JG, et al. Clinical features of type III (mixed) paraesophageal hernia. *Am J Gastroenterol* 1996;91:914-6.
11. Malatino LS, Presicci PF, Bellanuova I, Di Grande A, Consoli A, Mangiafico RA. Giant paraesophageal hernia in an asymptomatic old man. The case for misdiagnosing. *Panminerva Med* 1996;38:262-5.
12. Allen B, Tompkins RK, Mulder DG. Repair of large paraesophageal hernia with complete intrathoracic stomach. *Am Surg* 1991;57:642-7.
13. Hill LD. Incarcerated paraesophageal hernia. A surgical emergency. *Am J Surg* 1973;126:286-91.
14. Agwunobi A, Bancewicz J, Attwood SE. Simple laparoscopic gastropexy as the initial treatment of paraesophageal hiatal hernia. *Br J Surg* 1998;85:604-6.
15. Schauer PR, Ikramuddin S, McLaughlin RH, et al. Comparison of laparoscopic versus open repair of paraesophageal hernia. *Am J Surg* 1998;176:659-65.
16. Medina L, Peetz M, Ratzler E, Fenoglio M. Laparoscopic paraesophageal hernia repair. *J Soc Laparosc Surg* 1998;2:269-72.
17. Nattakom T, Schuerer D, Batra S, Velonovich V, Karmy-Jones R. Emergency laparoscopic repair of a paraesophageal hernia. *Surg Endosc* 1999;13:75-6.
18. Jewell FM, Tesar PA, Virjee J. Diaphragmatic herniation of the large bowel. *Clin Radiol* 1994;49:469-72.