

Penetrating BB Shot Head Wound in an Asymptomatic 9-Year-Old Girl: The Ultimate Teaching Moment

Niel A. Johnson, CPT, MC, USA

Background: Air rifle BB injuries represent a common type of childhood accident. The purpose of this case report is to encourage all providers of pediatric care to include nonpowder firearm safety education with standard well-child anticipatory guidance.

Methods: A case report is described and experience with similar injuries is discussed from cases found in a literature review using the key words "air rifle," "patient education," "pediatric," "ballistics," and "trauma."

Results: A 9-year-old girl came to the emergency department after having been accidentally shot in the head by her 7-year-old brother with a toy air rifle. The BB shot entered through the left cheek and traversed up into the soft tissue above the mandible, just medial to the internal carotid artery, and posterior to the facial nerve. Other than local pain, she was entirely asymptomatic. The cheek was repaired without complication. Conservative therapy was recommended. She and her family were given anticipatory guidance, and her course thereafter was uneventful.

Conclusion: Firearm education is not a standard part of every well-child encounter. Injuries by all types of firearms are increasing at epidemic rates. Questioning about the accessibility of both powder- and non-powder-based weapons (ie, air rifle) and providing routine safety education should become the standard of care at all well-child encounters. (J Am Board Fam Pract 1997;10:125-30.)

Air rifle projectile injuries represent a common type of childhood accident.¹ As spring-loaded toy BB rifles evolved during the last 20 years into pump-action air-compression rifles, the incidence and severity of BB and pellet injuries have also increased. Although some research has been done in this area, the focus on prevention and consumer education has been primarily on handguns and other weapons used by adults.¹⁻³ Occurring in less than 1 percent of all firearms fatalities, air rifle injuries account for nearly 36,000 emergency department visits and at least 10 childhood deaths each year (Figure 1).³⁻⁶ The actual incidence of injuries is probably much higher, but because most injuries are minor, they are not always reported.⁶ Because of the unique ballistics proper-

ties of BBs, serious penetrating injuries to the face, eyes, and throat are fortunately not common but can nonetheless be just as fatal as those caused by traditional ammunition, given the proper speed and range of the projectile.

This case report represents a serious, penetrating deep-head injury entering the region of the pterygoid fossa, which fortunately did not cause any neurologic, vascular, hematologic, or other clinically evident complication. It is described because it is a graphic reminder to all providers of pediatric care that non-powder-based firearm safety education should be a standard part of well-child anticipatory guidance.

Methods

A case of a young girl with a penetrating head wound caused by a BB shot from a toy air rifle is described. MEDLINE was searched using the key words "air rifle," "patient education," "pediatric," "ballistics," and "trauma" to explore the potential dangers and management of this increasingly common injury.

Submitted, revised, 4 June 1996.

From the Department of Family and Community Medicine, Dwight D. Eisenhower Army Medical Center, Ft. Gordon, Georgia. Address reprint requests to Niel A. Johnson, MD, 723 Low Meadow Drive, Evans, GA 30809.

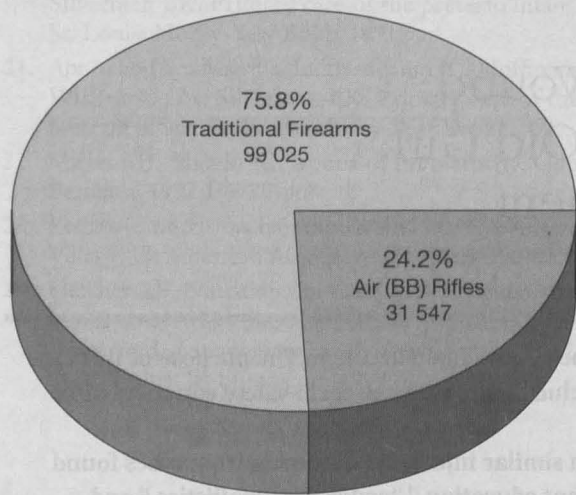


Figure 1. Firearm injuries seen in emergency departments, June 1992–May 1993.

Adapted from Annest et al.⁶

Case Presentation

An otherwise healthy 9-year-old girl came to the emergency department after having been accidentally shot in the head by her 7-year-old brother with a toy air rifle. The copper-based Daisy™ brand BB shot entered through her left cheek and traversed up into the soft tissue above the mandible, just medial to the internal carotid artery and posterior to the facial nerve. Other than local pain caused by tissue trauma of the cheek and buccal mucosa, she was entirely asymptomatic. The cheek was repaired without complication. Otolaryngologic examination 2 weeks later confirmed the secluded location of the BB by plain films (Figures 2 and 3) and computed tomography (Figure 4). Therapeutic options discussed with the patient and her parents included exploration of the wound, extraction of the BB, and observation. Because we believed an attempt to extract the BB could have traumatized the soft tissues and injured the facial nerve, internal carotid artery, mandibular joint and adjacent structures, conservative therapy was recommended. The patient and her family were given anticipatory guidance, including the importance of avoiding the magnetic resonance imaging scanner, awareness of the signs of heavy metal toxicity, and understanding the signs and symptoms of facial nerve compromise should the foreign body spontaneously come out. Her course thereafter was uneventful. On a follow-up examination 1 year later, no symptoms had devel-

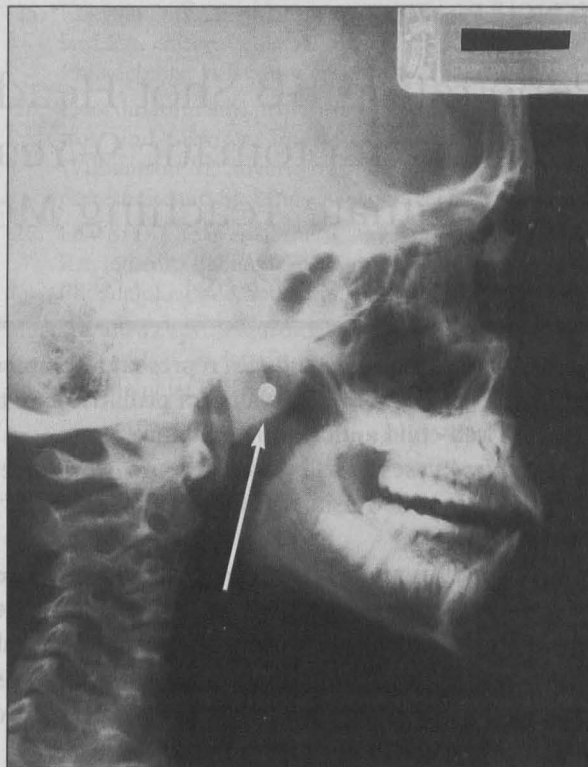


Figure 2. Lateral plain film view of skull showing location of BB.

oped, including pain, and the BB had not left its location.

From a preventive medicine standpoint for this family, this isolated incident introduced an opportunity to reinforce firearm safety precautions. On a greater scale, however, the primary prevention lesson from this case is our need to include firearm safety when we discuss injury prevention with other families.

Discussion

Air rifles were developed in 16th century Germany and are reported to have been used in the Napoleonic Wars by Austrian soldiers, as well as by Lewis and Clark for hunting during their expeditions.⁵ Today, air rifles that shoot BBs are marketed to children and young adults as toys for use in target shooting, sport hunting, and gun safety training.² Precise sales figures are not available for these products, but they are commonly sold in the United States. Unlike traditional firearms, air rifle sales do not require licensing or regulation, which makes sales figures and demographics of children utilizing these products difficult to determine accurately.

Three mechanisms of action are currently used

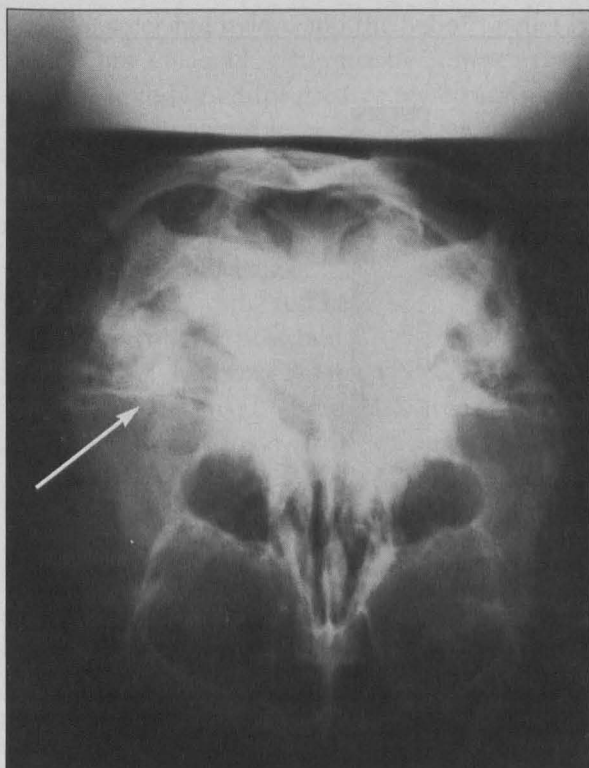


Figure 3. Anteroposterior plain film of skull showing location of BB.

in air rifles. In the pneumatic compression system, air is physically pumped into a chamber, which, when released, propels the projectile down the barrel. In the spring-compression system, a powerful spring compresses the air by means of a piston, which is triggered to release the air and thus propel the shot. A disposable carbon dioxide cartridge system works by compressing a piston and firing the shot much in the same way as the spring-compression system.⁵

Modern pump-action air rifles can generate considerable muzzle velocity, up to 340 ft/sec, comparable to a .22-caliber handgun. Skin penetration by 1.77-mm standard BB rounds can occur with as little as 150 to 170 ft/sec velocity at midrange (about 50 feet). Bone penetration, particularly into the skull, occurs with a muzzle velocity of 300 to 350 ft/sec and can be achieved with most of these toy air rifles, especially at close range.^{5,7,8} The ballistics of air rifle BBs differs from traditional rifle bullets in that the muzzle velocity is much slower, and there is no rifling of the barrel to negotiate, resulting in a more erratic trajectory. The importance of these differences is that a wound produced by a BB air rifle will tend to be primarily superficial to most parts of the

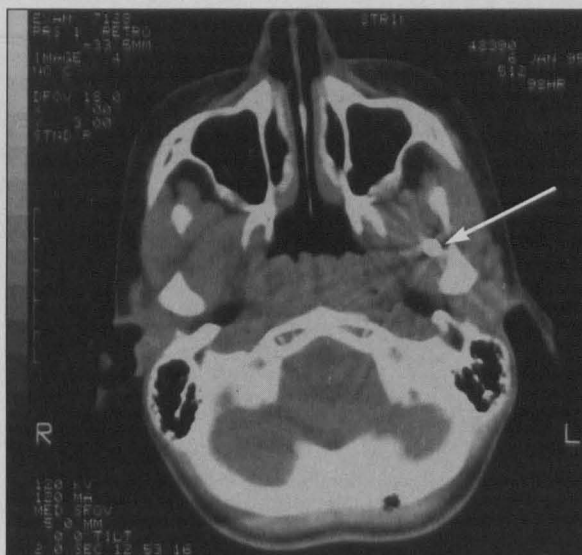


Figure 4. Computed tomographic scan of axial view of skull showing secluded location of BB.

body, and the shot will penetrate only in areas where the skin is exposed, thin, or in close range.^{3,7,8} Not surprisingly, the location of injuries from air rifles is the same as from conventional powder-based firearms, that is, the head, chest, and neck being more commonly involved in fatalities than the abdomen and extremities (Figures 5 and 6).⁹

A MEDLINE search of English-language literature back to 1966 revealed a few case reports of head and neck wounds caused by BB air rifles. Most cases describe children who suffered accidental injury by intracranial penetration of close-range BB rounds, causing some type of neurologic deficit. These deficits include hemiparesis, blindness (caused by nerve injury), speech impairment, spasticity, hydrocephalus, and oculomotor disturbance.³ One report describes the penetration of a BB into a metacarpophalangeal joint, leading to acute lead toxicity.¹⁰ Other reports describe various trauma to the thorax, abdomen, and extremities in the same distribution frequency that is found with conventional firearm injuries in children. As in our case, all but one of the previously reported cases involved accidental shooting of the patient by an unsupervised and untrained child.³ The single case involving an adult was that of an intoxicated family member accidentally shooting a 5-month old baby in the temporal lobe, resulting in only minor injury and no serious permanent neurologic sequelae.³ No report was found describing a remarkably atrau-

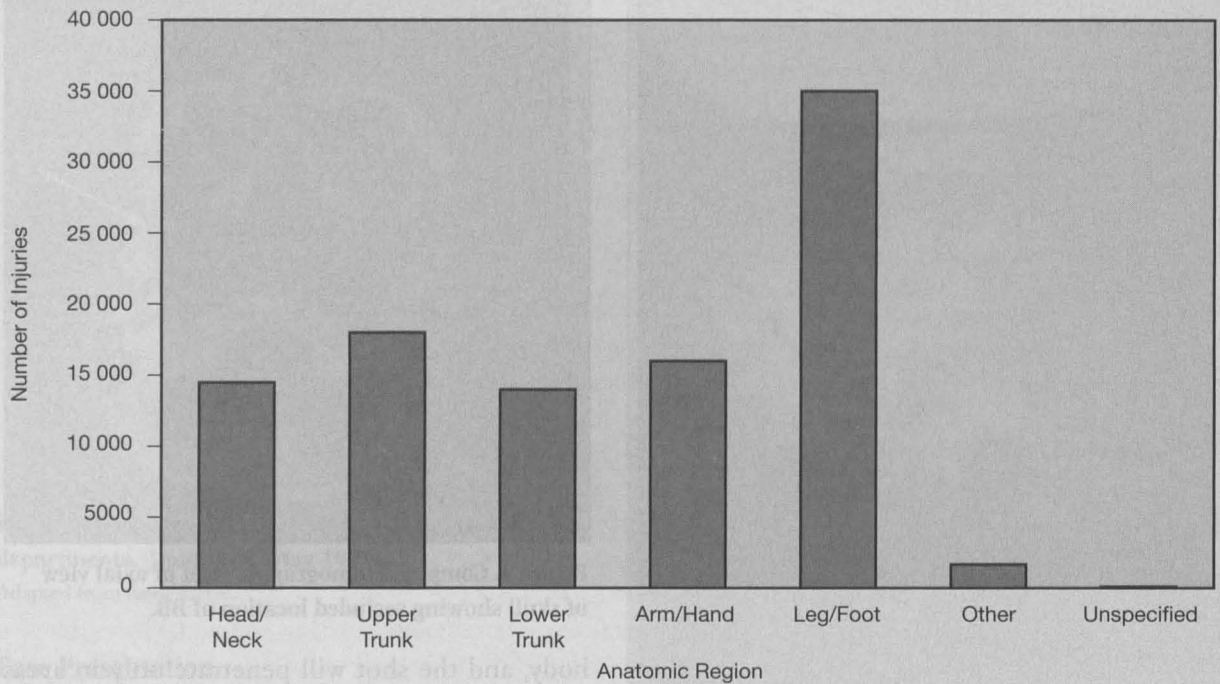


Figure 5. Injury sites for all firearms, June 1992–May 1993.

Adapted from Annett et al.⁶

matic intracranial injury, as in our case.

At least three factors contribute to the alarming incidence of air rifle injuries in children: (1) the rifles themselves bear a strong resemblance to nonprojectile toy rifles and can attract a younger child unfamiliar with their potential for injury,⁴ (2) regulation of the toys is effectively absent,⁵ and (3) the rifles are seldom locked away from a curious young child's hands.⁴

Diagnosis of head and neck air rifle injuries is made based on historical, clinical, and radiographic data. History should include the type and brand of rifle and ammunition used, the angle of aim used, the distance from the rifle, and the potential number of rounds fired. Symptoms such as focal neurologic deficits and any alteration of consciousness are important as well. Clinically, the patient should be examined for entry and exit wounds, and acute signs of blood loss should be addressed immediately. Abnormal findings on the oculomotor and neurologic examinations suggest involvement of the central nervous system. All patients should have a plain film radiograph to confirm the location and number of foreign bodies, and computed tomographic scanning should be done to assess for intracranial bleeding or pressure elevation.

Treatment is divided into two phases. During the acute phase, attention is given to local bleeding and maintenance of a patent airway. For superficial wounds standard wound care is generally all that is needed; oral antibiotics can be prescribed if the wound is extensive. Although an abscess could result from the penetration of a dirty BB, its occurrence is not supported in the literature,³ and local debridement of the BB and surrounding tissue for the prevention of abscess formation is not necessarily indicated. Injury to a cerebral or related vessel might require prompt neurosurgical intervention, and consultation with the neurosurgeon is recommended in these cases. If, however, the BB is lodged in an area where the surgery required to get to the BB could injure the surrounding structures, the decision to intervene must be made carefully. Expectant management (ie, observation without intervention) might be the safest course of action, and the patient and parents must be educated about what signs and symptoms to look for should a complication arise.

Lead was used in the BBs 20 to 30 years ago, but the issue of heavy metal toxicity is mostly of historical note, because today BBs are made primarily of a combination of copper, brass, and steel. More recently, the PrometheusTM pellet is

made of steel and nylon, and the Sabo™ pellet is made from a lead alloy and plastic. These newer pellets are designed for greater penetration and tend to fragment and leave radiolucent debris in the wound track. The inability to radiographically visualize all the pellet fragments in the soft tissue complicates the management of the wound.¹¹ Blood serum can be tested for heavy metal initially, and the test can be repeated 1 year later to rule out the possibility of heavy metal toxicity. We believed that an attempt to extract the copper-based Daisy™ brand BB from our patient's pterygoid fossa would have resulted in trauma to the soft tissues of the face, as well as potential injury to the facial nerve, internal carotid, mandibular joint, and other adjacent structures. Because the patient indeed was asymptomatic and the BB did not appear to be causing any trauma, observation was the most appropriate therapy.

It is not known what effect firearm education during well-child encounters has on the prevention of injuries in children. One can surmise from the success primary prevention has had on such potentially tragic situations as unrestrained front car seats and airbags,¹² infant walkers and stairwells,¹³ and supine sleeping position and sudden infant death syndrome¹⁴ that the risk of tragic injury from BB air rifles would be reduced as a result of counseling during well-child encounters. Further research would be indicated to measure this effect.

The issue of product liability warrants mentioning from a preventive medicine standpoint. Put another way, what responsibility do air rifle and BB manufacturers have in injury prevention with their products? For example, packaging has evolved to include more explicit warnings and to increase the difficulty of opening without reading the safety information provided. I would hypothesize that air rifle and BB manufacturers take customer safety very seriously, yet they do not incur a greater liability for several reasons: (1) the rifles are meant to shoot things; (2) the warnings are clearly marked on the packages (to include "close adult supervision"); (3) the risk from such a product is implied, that is, injury is a generally accepted risk of using this product; and (4) compared with traditional firearms, the destructive potential of which far exceeds what air rifles as a group can do, any serious attempt to pin liability to these so-called toys would likely be ignored. As

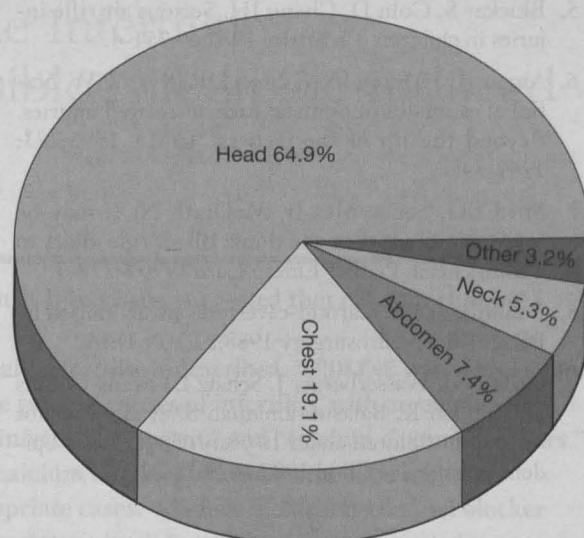


Figure 6. Site of firearm fatalities: all firearms, 1980.

Adapted from Beaver et al.⁴

the incidence of firearm injuries continues to increase, the issue of product liability might assume a different importance.

Conclusion

Firearm education has not yet become a standard part of every well-child encounter despite the evidence that ballistic injuries, both accidental and intentional, by all types of firearms are increasing at epidemic rates.⁵ Asking whether either powder- or non-powder-based (ie, air rifle) weapons or toys are in the household and providing routine safety education should become standard care at all well-child encounters.^{1,2,9} Pediatric health care providers should either take the opportunity to educate their patients and families about gun safety or refer them to an appropriate person who can provide advice in this area.

References

1. Keck NJ, Istre GR, Coury DL, Jordan F, Eaton AP. Characteristics of fatal gunshot wounds in the home in Oklahoma: 1982-1983. *Am J Dis Child* 1988;142:623-6.
2. Patterson PJ, Smith LR. Firearms in the home and child safety. *Am J Dis Child* 1987;141:221-3.
3. Miner ME, Cabrera JA, Ford E, Ewing-Cobbs L, Amling J. Intracranial penetration due to BB air rifle injuries. *Neurosurgery* 1986;19:952-4.
4. Beaver BL, Moore VL, Pecllet M, Haller JA Jr, Smialek J, Hill JL. Characteristics of pediatric firearm fatalities. *J Pediatr Surg* 1990;25:97-100.

5. Blocker S, Coln D, Chang JH. Serious air rifle injuries in children. *Pediatrics* 1982;69:751-4.
6. Annet JL, Mercy JA, Gibson DR, Ryan GW. National estimates of nonfatal firearm-related injuries. Beyond the tip of the iceberg. *JAMA* 1995;273:1749-54.
7. Ford EG, Senac MO Jr, McGrath N. It may be more significant than you think: BB air rifle injury to a child's head. *Pediatr Emerg Care* 1990;6:278-9.
8. Rahimizadeh A. Carotid-cavernous fistula caused by BB air rifle. *Neurosurgery* 1988;22(1 Pt 1):160.
9. Ordog GJ, Wasserberger J, Schatz I, Owens-Collins D, English K, Balasubramanian S, et al. Gunshot wounds in children under 10 years of age. A new epidemic. *Am J Dis Child* 1988;142:618-22.
10. Watson N, Songcharoen GP. Lead synovitis in the hand: a case report. *J Hand Surg Br* 1985;10:423-4.
11. Smith WD. Air rifle ammunition and its influence on wounding potential. *Arch Emerg Med* 1985;2:25-9.
12. Centers for Disease Control. Air-bag-associated fatal injuries to infants and children riding in front passenger seats—United States. *MMWR Morbid Mortal Wkly Rep* 1995;44:845-7.
13. Guide to clinical preventive services: report of the US Preventive Services Task Force. Baltimore: Williams & Wilkins; 1989:321-9.
14. Freed GE, Steinschneider A, Glassman M, Winn K. Sudden infant death syndrome and an understanding of selected clinical issues. *Pediatr Clin North Am* 1994;41:967-90.