

Atraumatic Pneumopericardium in a Full-Term Newborn with Fetal Tachycardia

CPT Niel A. Johnson, MC, USA, and CPT Johnathan R. Gore, III, MC, USA

Pneumopericardium is an uncommon complication of the neonatal transition period, occurring in 1.3 percent of premature neonates in intensive care settings. Its occurrence is usually associated with some type of barotrauma or respiratory intervention, such as endotracheal intubation or administration of continuous positive airway pressure, and is almost exclusively a problem for the premature infant.

The purpose of this case report is to describe the occurrence of pneumopericardium in a full-term infant who had no apparent barotrauma and whose symptoms were tachycardia and mild respiratory difficulty. We will also review the diagnosis and current therapy of this potentially serious complication in a newborn who develops respiratory distress during transition.

Case Report

A 3770-g boy was born at term by normal spontaneous vaginal delivery to a healthy 21-year-old primigravida woman whose prenatal course was uncomplicated. Family physicians were in attendance at this delivery, which occurred at a large teaching hospital. Labor had progressed uneventfully for approximately 8 hours while the mother was receiving epidural anesthesia. One hour before delivery, however, the mother's temperature rose to 38.9°C, and the fetal heart rate increased to more than 200 beats per minute. Antibiotics were administered, and labor was augmented with intravenous oxytocin until delivery, which proceeded without difficulty over a small midline episiotomy. The infant's tachycardia improved to less than 180 beats per minute soon after delivery, but grunting and subcostal retractions were ob-

served. Apgar scores were 8 and 8 at 1 and 5 minutes, respectively.

The infant was taken to the neonatal intensive care unit in stable condition for observation and a routine sepsis workup for possible chorioamnionitis. His temperature, blood pressure, heart rate were normal, and his oxygen saturation was greater than 99 percent. His lungs were clear, and there was no cyanosis or ballooning of the chest or soft tissues of the neck. Plain chest radiographs, done as part of this sepsis workup, showed a pneumopericardium (Figures 1 and 2). The attending neonatologist recommended intubation, sedation, and examination by the pediatric thoracic surgeon.

After these initial interventions and consultation, several treatment options were considered. Conservative nonsurgical management of the pneumopericardium was selected because no evidence of tamponade was seen clinically or by echocardiogram. The pericardial air gradually resolved (Figure 3), and the infant was extubated on the 2nd day after delivery (Figure 4). The remainder of his hospital course was notable for a blood culture that grew gram-positive cocci, for which he was prescribed antibiotic therapy. The source of this bacteremia was felt to be nosocomial, although chorioamnionitis was included in the differential diagnosis. His recovery was uncomplicated, and he did well after discharge.

Discussion

The cause of this infant's pneumopericardium was believed to be a small rupture of the pericardial sac adjacent to a nearby bronchial structure at the time of his initial breath. It was hypothesized that in his case, a congenital conduit allowed air to enter the pericardium during the first few breaths—a time when this conduit might have been the path of least resistance. Increased heart rate and breathing effort at the time of delivery as a result of chorioamnionitis could have precipi-

Submitted, revised, 9 October 1996.

From the Department of Family and Community Medicine, Dwight D. Eisenhower Army Medical Center, Ft. Gordon, Georgia. Address reprint request to CPT Niel A. Johnson, MC, 723 Low Meadow Dr, Evans, GA 30809.

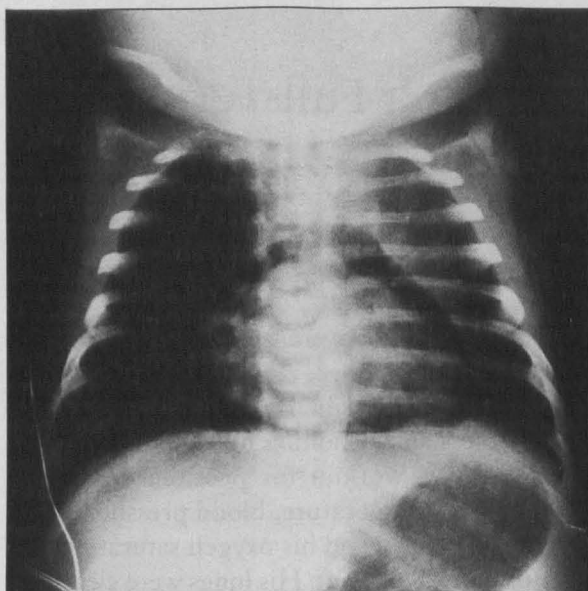


Figure 1. Initial anteroposterior chest radiograph showing the classic pneumopericardial halo sign.

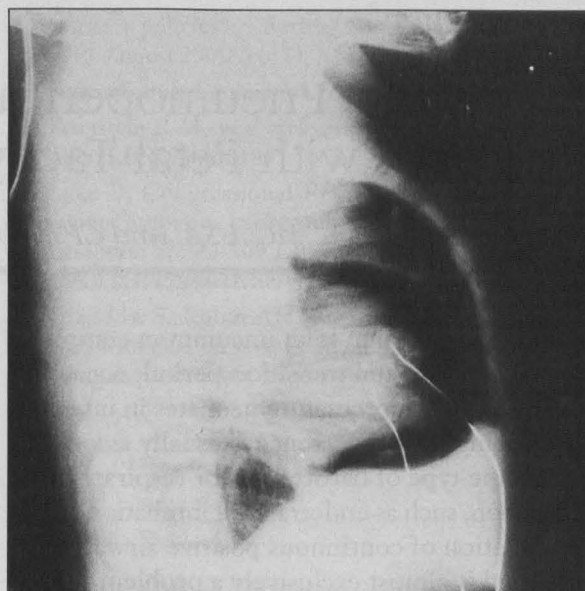


Figure 2. Initial chest radiograph showing pericardial air anteriorly.

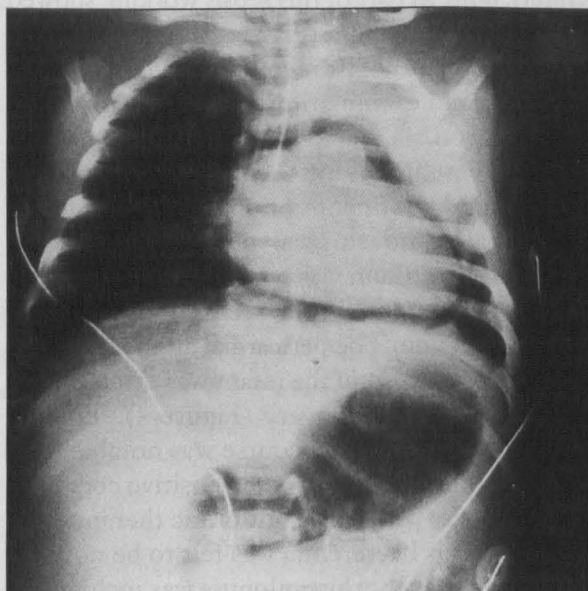


Figure 3. Chest radiograph, day 1, showing the slowly resolving pneumopericardium.

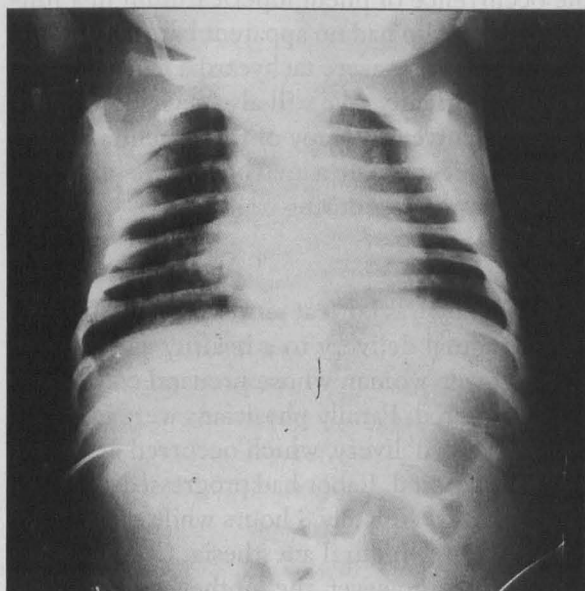


Figure 4. Chest radiograph, day 2, showing resolution of the pericardial air.

tated this event. As airway pressures normalized, no further air passed into the pericardium, and the trapped air was absorbed.

The actual incidence of such congenital anomalies is not known, but autopsy records show that they do exist. It is possible that physical trauma could have occurred during the birth process from the natural compression of the chest through the pelvic outlet, but the incidence of such a complication should be much higher given the number of full-term infants born every day. A

fractured sternum or other related bony structure was also considered but not supported radiographically or clinically.

Family physicians and other providers of neonatal care are often faced with the infant who shows signs of respiratory distress. In full-term babies, in either the absence or presence of barotrauma, this respiratory difficulty could be due to delayed amniotic fluid absorption, meconium aspiration, narcotic-induced depression, effects of magnesium sulfate, and other related conditions.

In premature babies, the list of potential causes also includes hyaline membrane disease, sepsis, congenital malformations (eg, tracheoesophageal fistula), and fetal lung immaturity. The more common complications that can lead to pneumopericardium include endotracheal intubation; fracture of the rib, clavicle, or sternum; and a congenital heart defect resulting in a weak or incomplete pericardium, among others. Although most complications would typically arise in the neonatal intensive care setting, familiarization with these complications better prepares the birth attendant to recognize them at the time of delivery.

The role of the family physician in this case highlights an important teaching point. Because the delivery occurred at a tertiary medical center, such resources as a neonatal intensive care unit, in-house neonatology backup, and on-call pediatric thoracic surgery staff were readily available. These resources would not be available for many family physicians providing obstetric care at outlying facilities.

In retrospect, the management might have been overly aggressive, for the intubation itself, along with gentle positive-pressure ventilation, placed the baby at risk for further pneumopericardium and other barotrauma, such as pneumothorax and pneumomediastinum. At the time, however, the clinical picture of a tachycardic infant with a positive halo sign on his chest radiograph prompted a quick decision for more secure, albeit invasive, management. Because the neonatologist was much more accustomed to caring for premature infants that develop this problem, his judgment was understandably influenced by a population frequently known to require invasive measures, as opposed to full-term infants who might require only less-invasive means. Either way, the infant did well, and the lesson for family physicians is that neonatal complications do occur, usually unexpectedly, and there are many ways to approach a specific situation. The availability of resources and consultants and the proximity to tertiary care are important variables in arriving at a treatment plan.

We found several cases of traumatic pneumopericardium on a MEDLINE review searching back to 1966. Once considered rare, the number of reported cases of traumatic pneumopericardium have increased from seven in 1970 to severalfold more in recent years, probably as a result of the increased use of high-pressure ventilation in

neonatal intensive care settings.^{1,2} Glenski and Hall² reviewed 127 cases of neonatal pneumopericardium from 1975 to 1984, and noted that 121 occurred in neonates receiving positive-pressure ventilation; of the remaining 6 cases, 3 infants were receiving negative-pressure ventilation, and 3 were not receiving any ventilatory support. The authors concluded that pneumopericardium is related to barotrauma, specifically high peak inspiratory pressure, prolonged inspiratory time, and an elevated mean airway pressure of 17 ± 10 cm of air.

We found few cases of pneumopericardium caused by nontraumatic medical conditions. Björklund et al³ reported pneumopericardium in an infant born by forceps delivery without apparent barotrauma. No other similar case of atraumatic neonatal pneumopericardium appeared in our literature search.

Pneumopericardium carries an overall mortality of 70 to 75 percent, which is mostly attributed to coexisting illness, such as prematurity and respiratory distress syndrome.³⁻⁵ The mortality from pneumopericardium in full-term infants is not known, but it is likely much less. In older children and adults, atraumatic pneumopericardium can be caused by achalasia, gas-producing infection, severe cough, chlorine gas exposure, cocaine inhalation, emesis, barotrauma, parturition, and contact sports participation.⁶

Diagnosis of pneumopericardium, also called pericardial emphysema, can be made by clinical and radiographic findings. In practice, however, the diagnosis is almost exclusively made initially by plain film radiography,^{1,6} where the finding of air lining the pericardium, the classic halo sign,³ is diagnostic.⁷ Acute retrosternal pain radiating to the back, neck, or shoulders is a common complaint in adults. Cyanosis, dyspnea, and the classic ballooning of the soft tissues of the neck can be observed,⁴ which when accompanied by the Hamman sign (mediastinal crepitation), suggest a coexisting pneumomediastinum.⁶ Percussion of the precordium can reveal tympany and, on auscultation, dullness. Coexisting injury by pneumomediastinum or pneumothorax is not uncommon and is likely to complicate the accurate diagnosis of air in the pericardial sac.⁴

A chest radiograph will show the characteristic signs of pericardial air and is considered the diagnostic study of choice. Transthoracic echocar-

diography is sometimes indicated to look for evidence of cardiac tamponade. Electrocardiographic findings are not helpful, although older children and adults might show tachycardia and signs of pericardial effusion.⁶ Cabatu and Brown⁸ describe the use of thoracic transillumination as a potential diagnostic tool for this neonatal emergency.

Management of the acute pneumopericardium is straightforward. Respiratory distress is managed by mechanical ventilation, if necessary, to maintain adequate oxygenation. Cardiac tamponade is managed by needle pericardiocentesis to allow the heart chambers to fill properly. The underlying cause is then sought⁷ after initiating resuscitative measures, including oxygen supplementation and sedation. Sepsis, intrinsic pulmonary disease, and trauma should be treated as appropriate. Parents can be referred to a pediatric geneticist when congenital malformations are diagnosed or suspected. Surgery is indicated to provide relief of the tamponade for large air collections causing distress.

Observation only might be indicated for mild pneumopericardium when there are no signs of cardiac wall motion abnormality or clinical signs of distress, as the body can spontaneously resolve the air without specific therapy.^{3,6} Intubation and sedation might be indicated, as in our case, to allow the pericardium a chance to heal for a brief period of time. Recurrence is almost guaranteed if the original injury was due to ventilatory intervention and the infant is kept on the ventilator for a prolonged period of time.^{1,7} The management of pneumopericardium clearly depends on the age of the patient, the suspected cause, the available tertiary neonatal medical support, and the degree of clinically observed respiratory compromise.

Conclusion

Pneumopericardium is an uncommon, but serious, life-threatening complication of newborn life that usually results from barotrauma, but it should be considered in a full-term newborn who shows respiratory difficulty yet is born under apparently atraumatic conditions. The initial signs can be unreliable in neonates, and chest radiography might be the only way to make an early diagnosis. Family physicians who deliver babies should be comfortable with not only recognizing the early signs of birth complications, such as pneumopericardium, but also managing them.

References

1. Neal RC, Beck DE, Smith VC, Null DM. Neonatal pneumopericardium with high-frequency ventilation. *Ann Thorac Surg* 1989;47:274-7.
2. Glenski JA, Hall RT. Neonatal pneumopericardium: analysis of ventilatory variables. *Crit Care Med* 1984;12:439-42.
3. Björklund L, Lindroth M, Malmgren N, Warner A. Spontaneous pneumopericardium in an otherwise healthy full-term newborn. *Acta Paediatr Scand* 1990;79:234-6.
4. Emery RW, Foker J, Thompson TR. Neonatal pneumopericardium: a surgical emergency. *Ann Thorac Surg* 1984;37:128-32.
5. Fiser DH, Walker WM. Tension pneumopericardium in an infant. *Chest* 1992;102:1888-91.
6. Bartal N, Zaarura S, Marvan H. Spontaneous pneumopericardium and pneumomediastinum. *Ann Otol Rhinol Laryngol* 1990;99:1005-6.
7. Schwartz MZ, Palder SB, Tyson KR, Marr CC. Complications of prematurity that may require surgical intervention. *Arch Surg* 1988;123:1135-8.
8. Cabatu EE, Brown EG. Thoracic transillumination: aid in the diagnosis and treatment of pneumopericardium. *Pediatrics* 1979;64:958-60.