

# Current Use Of The Papanicolaou Smear

William J. Crump, M.D.

**Abstract:** The Papanicolaou smear is an extremely useful screening technique for early detection of cervical neoplasia. The recent clarification of cervical intraepithelial neoplasia (CIN) as a continuum of dysplasia has ramifications for management. The modern reporting scheme includes a narrative portion that gives the clinician information beyond the original Class I-V. This is especially helpful in inter-

pretation of the atypical smear. The recent findings of invasive disease following an atypical smear and the malignant potential of condylomatous changes have resulted in early use of colposcopy in these clinical situations. This article discusses Papanicolaou smear technique, reporting classifications, and management of the patient who has an abnormal smear. (JABFP 1988; 1:131-4.)

The Papanicolaou smear is a powerful screening technique for detection of the early stages of cervical carcinoma. Populations receiving routine screening show a marked decrease in the incidence and mortality of invasive disease with comparatively little change in areas not carefully screened.<sup>1,2</sup> Current estimates of incidence in the United States are 13 per 100,000 for invasive cancer, and it is three to four times that figure for curable preinvasive disease. Preinvasive disease is largely a problem of young women, and the risk is increased when there is a history of beginning sexual intercourse at a young age and having multiple partners. Women who are black or from a lower socioeconomic environment also have risk factors.<sup>3</sup> The marked recent increase in preinvasive disease and the epidemic of potentially carcinogenic cervical condylomata have brought these problems into sharp focus for primary care physicians.

## Natural History of Cervical Cancer

Much has been learned recently concerning the natural history of cervical carcinoma. The older concept of a separate classification of dysplasia and carcinoma in situ has been replaced by the framework of a continuum of cervical intraepithelial neoplasia (CIN). Although definitive therapy usually is preceded by histologic diagnosis, the grades of CIN can be determined by cytology alone.<sup>4,5</sup> If only the lower one-third of the squa-

mous epithelium is neoplastic, this is classified as CIN 1. The lower two-thirds is involved in CIN 2, and full thickness neoplasia is classified as CIN 3 (Figure 1). The maturity of the neoplastic cell indicates the layer from which it arises, allowing the cytopathologist to classify individual cells as CIN 1-3. Although microinvasive disease can occur at any stage of CIN, it is unusual in the lower grades.<sup>4</sup> This leads to the concept of cure by complete removal of the intraepithelial lesion by simple biopsy or conization. However, there are still significant gaps in our knowledge of the progression; for example, we do not understand why 30-60 percent of preinvasive disease will regress spontaneously.<sup>3</sup>

## Technique for Obtaining Papanicolaou Smears

Technique is important in assessing the Papanicolaou smear as a screening test. The 30 percent false-negative rate of a single smear<sup>3</sup> can be sharply decreased by careful attention to detail. The entire squamocolumnar junction must be sampled when a smear is done. While this usually can be accomplished with a wooden spatula, obtaining an endocervical sample with a cotton swab or aspiration instrument helps to assure completeness. The endocervical swab is especially important in older women, since the squamocolumnar junction may be inside the endocervical canal. Because lubricating jelly alters cellular detail, it is best to use a water-lubricated speculum for the exam. The sample should be gently smeared on the slide and sprayed immediately with Spray-Cyte™ or a similar product.

From the School of Primary Medical Care, Family Medicine Program, University of Alabama in Huntsville. Address reprint requests to William J. Crump, M.D., 201 Governor's Drive, Huntsville, AL 35801.

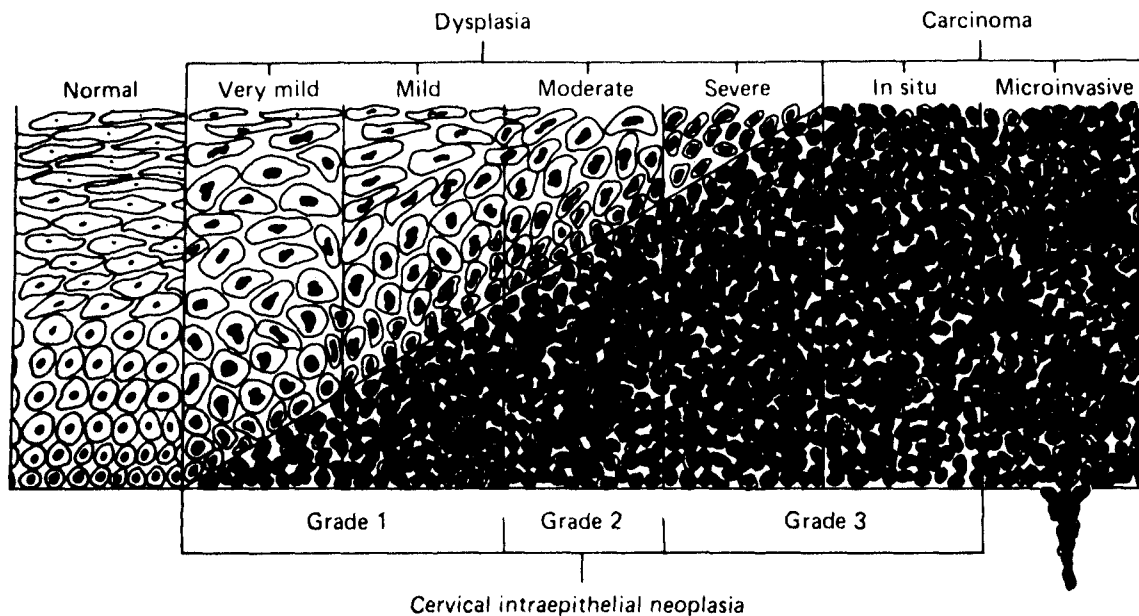


Figure 1. Drawing representing cervical cancer precursors. There is a logarithmic increase in the number of malignant basal cells with severity of disease. Note that the basal cells of carcinoma in situ are morphologically identical with those of very mild dysplasia. According to the disease continuum concept, grade 1 cervical intraepithelial neoplasia (CIN) corresponds to very mild-mild dysplasia, grade 2 to moderate dysplasia, and grade 3 to severe dysplasia-carcinoma in situ. The precursor stage ends when clones of malignant cells invade the stroma: this is microinvasive carcinoma. Used with permission from Ferenczy A. *Cervical intraepithelial neoplasia*. In: Blaustein A. *Pathology of the female genital tract*. New York: Springer-Verlag, 1977:146.

## Report Classification

The original Papanicolaou nomenclature scheme reported results as Class I–V. It was difficult for many clinicians to select appropriate treatment for the smears reported as atypical dysplastic or carcinoma in situ (CIS), and this led to a proposed change in the reporting scheme.<sup>4</sup> The new classification suggested by Richart is shown in Table 1, which lists the seven categories likely to be encountered.<sup>4,5</sup> This classification includes a narrative portion that is especially important when the cytologic changes are difficult to classify. A smear may be unsatisfactory because there are no endocervical cells present (i.e., the squamocolumnar junction was not sampled) or because of an artifact introduced by bleeding, severe inflammation, or necrosis. The latter three findings are common in invasive cervical carcinoma, so careful evaluation of the patient on repeat exam is indicated. A negative report means that no benign or malignant changes were seen.

## Management

The narrative portion of the report classified as atypical should direct treatment to the cause

(Table 1). The former recommendation of treatment of the inflammatory process and repeating the smear in 3 months has been questioned recently. Considering that the repeat smear has an overall rate of 26 percent false-negative<sup>6</sup> and the growing evidence for a very short preinvasive phase in some young women,<sup>7</sup> it is important to exercise caution in this situation. If the report of atypia does not specify a cause and definite

**Table 1.** *Cervical Smear Classification.*

1. Unsatisfactory
2. Negative
3. Atypical cells suggestive of
  - a. *Trichomonas/Monilia/Gardnerella*
  - b. Herpes
  - c. Atrophy (Hypoestrogenic)
  - d. Nonspecific cervicitis
4. Squamous metaplasia
5. Hyperkeratosis
6. Condyloma (Koilocytosis)
7. Dysplasia
  - a. CIN
  - b. Invasive cancer

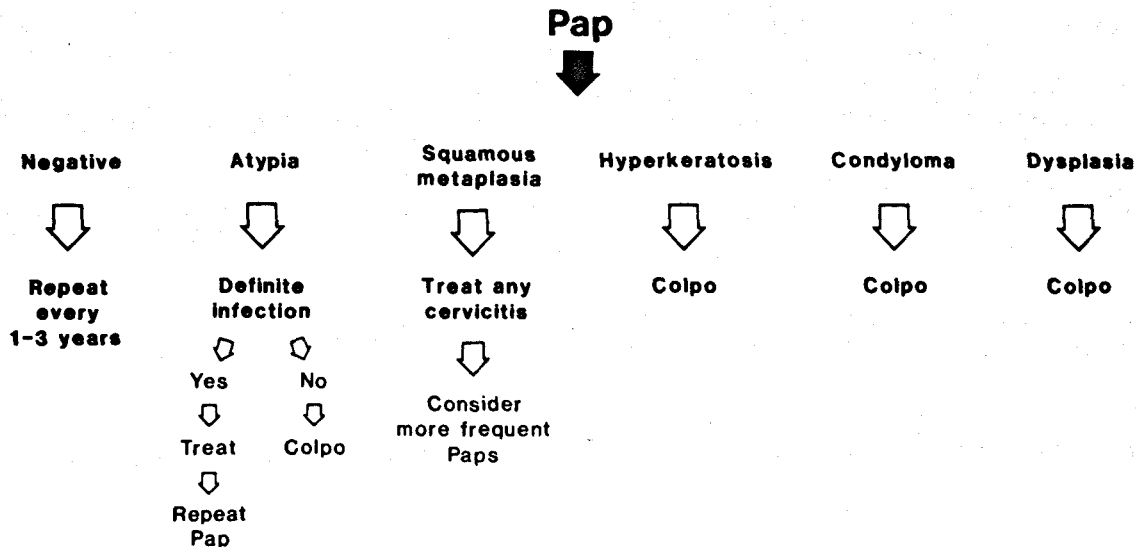


Figure 2. Suggested management of Papanicolaou smear results.

inflammation is not seen on examination, colposcopy is indicated<sup>8,9</sup> (Figure 2).

The report of squamous metaplasia means the normally tall columnar endocervical cells have become polygonal, yet are still benign. This is most common in chronic cervicitis and in users of oral contraceptives and is not believed to be a pre-malignant condition. Hyperkeratosis, on the other hand, may not be simply a response to inflammation and, if focal, can be a form of leukoplakia. Because hyperkeratosis may be impossible to differentiate from dysplasia, it should be managed with colposcopy.

Condylomatous changes due to human papillomavirus (HPV) changes are currently the major cause of abnormal smears in young women.<sup>10</sup> A specific pattern of nuclear hyperchromasia and cytoplasmic changes called koilocytosis are characteristic of HPV infection. Many of these lesions are "flat" condyloma that are not visible to the naked eye. The concept of cervical carcinoma as a venereal disease continues to gain acceptance, since HPV and CIN coexist 25 percent of the time and because HPV DNA has been found in CIN lesions. For these reasons, a report of condylomatous changes should be managed as a form of dysplasia.

If frank dysplasia is reported, the patient should be referred to an experienced colposcopist. If a lesion is visible, the primary physician may choose to obtain a punch biopsy prior to referral. In a poorly compliant patient who is unlikely to return for colposcopy, a biopsy of any suspicious

lesion done at the time of the original Papanicolaou smear is appropriate. If invasive disease is found on colposcopic-directed biopsy or conization, definitive therapy depends on the results of the metastatic survey and clinical staging.

### Frequency of Obtaining Papanicolaou Smears

There is considerable controversy regarding how frequently Papanicolaou smears should be done. The crux of this argument is the duration of the preinvasive phase of the disease. Most authorities agree that it takes 6 to 8 years for intraepithelial neoplasia to become invasive, and, therefore, the American Cancer Society (ACS) recommends that after two negative exams a year apart, the screening interval should be 3 years.<sup>11</sup> However, there is recent evidence for a bimodal progression, with 5 percent becoming invasive within 3 years, especially in young women.<sup>12</sup> This information and the significant rate of false-negative smears lend support to the recommendation of the Canadian task force for annual Papanicolaou smears in women aged 18-35 years.<sup>13</sup> On the issue of cessation of screening, the ACS currently does not recommend Papanicolaou smears after age 65. However, 25 percent of cervical cancer is in patients 65 years of age or older,<sup>14</sup> and cessation of screening presumes multiple smears have been done earlier. A recent study suggests that this presumption may not be true, as 25 percent of patients over 65

years of age had never had a Papanicolaou smear, and another 50 percent had not had regular smears.<sup>15</sup> Physicians caring for older patients should individualize health maintenance. For many women, this should include continuation of regular Papanicolaou smears.

With an understanding of the natural history of cervical carcinoma and helpful narrative reports of cervical cytology, the primary physician can make excellent use of the Papanicolaou smear as an important screening tool. Constant vigilance and earlier use of colposcopy should result in a continued decline in the incidence of mortality from invasive cervical disease.

## References

1. Christopherson WM, Lundin FE Jr, Mendez WM, Parker JE. Cervical cancer control: a study of morbidity and mortality trends over a twenty-one year period. *Cancer* 1976; 38:1357-66.
2. Boyes DA, Nichols TM, Millner AM, Worth AJ. Recent results from the British Columbia screening program for cervical cancer. *Am J Obstet Gynecol* 1977; 128:692-3.
3. Frame PS. A critical review of adult health maintenance, Part 3: prevention of cancer. *J Fam Pract* 1986; 22:511-20.
4. Richart RM. Current concepts in obstetrics and gynecology: the patient with an abnormal pap smear—screening techniques and management. *N Engl J Med* 1980; 302:332-4.
5. Sedlis A, Chen P. Cytology. In: Sciarra JJ. *Gynecology and obstetrics*. Vol. 1, Chap. 29. New York: Harper & Row, 1986:1-25.
6. Drescher CW, Peters WA III, Roberts JA. Contribution of endocervical curettage in evaluating abnormal cervical cytology. *Obstet Gynecol* 1983; 62:343-57.
7. Berkowitz RS, Ehrmann RL, Lavizzo-Mourey R, Knapp RC. Invasive cervical carcinoma in young women. *Gynecol Oncol* 1979; 8:311-6.
8. Jones WB, Saigo PE. The "atypical" Papanicolaou smear. *CA* 1986; 36:237-42.
9. Davis GL, Hernandez E, Davis JL, Miyazawa K. Atypical squamous cells in Papanicolaou smears. *Obstet Gynecol* 1987; 69:43-6.
10. Paavonen J. Colposcopic findings associated with human papillomavirus infection of the vagina and cervix. *Obstet Gynecol Surv* 1985; 40:185-9.
11. American Cancer Society Report on the Cancer-Related Health Checkup. Cancer of the cervix. *CA* 1980; 30:215-23.
12. Richard RM, Barron BA. Screening strategies for cervical cancer and cervical intraepithelial neoplasia. *Cancer* 1981; 47:1176-81.
13. Cervical cancer screening programs: summary of the 1982 Canadian task force report. *Can Med Assoc J* 1982; 127:581-9.
14. Mortality. Vol. 2. In: *Vital statistics of the United States, 1976*. Hyattsville, MD, National Center for Health Statistics, 1976, Part A.
15. Mandelblatt J, Gopaul I, Wistreich M. Gynecological care of elderly women. Another look at Papanicolaou smear testing. *JAMA* 1986; 256:367-71.

## Editorial Comment

All the confusion about the timing and frequency of Pap smears on the cervix and endocervix has recently been resolved. Under the guidance of the American College of Obstetricians and Gynecologists, as well as the American Cancer Society, agreement has been reached. There are seven major health organizations, including the American Medical Association, which support this effort. The new guidelines agreed to by the seven organizations say:

All women who are, or have been sexually active, or have reached the age of 18 shall have an annual Pap smear and pelvic examination. After a woman has had three or more satisfactory or normal examinations, the Pap smear may be performed less frequently at the discretion of her physician.<sup>1</sup>

As George Morley, M.D., President of the American College of Obstetricians and Gynecologists says:

We continue to recommend annual pelvic and breast examinations for all women and annual Pap smear tests for all women in high-risk groups. These would include all women who have had more than one sex partner, or whose partner has had more than one sex partner; all women who started sexual activity before age 18; women with a history of vaginal infections; and DES women.<sup>1</sup>

Certainly for postmenopausal women in the low-risk group, the importance of the pelvic examination to exclude pelvic masses is equal to or even greater in importance than doing a cervical Pap smear.

John L. Duhring, M.D.  
Medical College of Ohio  
Toledo, OH

## References

1. American Cancer Society, American College of Obstetricians and Gynecologists. News release. Washington, D.C., January 19, 1988.