

Accidental Instillation Of Cyanoacrylate Adhesive In The Eye

Scott P. Bruder, MD, PhD, and Alan B. Leahey, MD

Cyanoacrylate adhesives have been used for a variety of industrial and domestic purposes since their introduction by the Eastman Company in 1958. Many of the consumer products containing this compound are packaged in plastic bottles that resemble ophthalmic medications or artificial tears (Figure 1). This packaging has contributed to the accidental application of cyanoacrylate into the eye. As primary care physicians assume even greater responsibility within the medical community in the 1990s and beyond, many are faced with evaluating ophthalmologic emergencies, including these accidental instillations. Our review of the medical literature shows that while such unfortunate accidents have been previously reported,¹⁻⁸ there exist no clear recommendations or guidelines for treatment. Furthermore, because these injuries are found in a variety of clinical settings, management must be tailored to suit the individual patient. We report three cases that illustrate the salient issues regarding patient evaluation and review several treatment alternatives in the establishment of general prevention and management guidelines.

Report of Cases

Case 1

An 82-year-old woman with insulin-dependent diabetes mellitus, background diabetic retinopathy, and a visually compromising cataract in the left eye came to the emergency department 4 hours after having mistakenly instilled 1 drop of Fingrs artificial nail adhesive (cyanoacrylate), instead of artificial tears, in the left eye. The patient complained of decreased vision in that eye; however, she had no discomfort even with eye movement. Visual acuity was 20/40 in the right eye and 20/200 in the left eye. Slit lamp examination showed that the nasal and temporal aspects of the

lids and lashes of the left eye were stuck together with polymerized glue. The central 12 mm of the horizontal fissure was not involved, and the entire cornea was visible through this area when the patient was taken through all fields of gaze (Figure 2). Neither an abrasion nor glue fragments were present on the surface of the cornea or adjacent conjunctiva. An attempt to separate the lids mechanically was not successful, so the eye was patched with a generous amount of polymyxin B-bacitracin ointment, and the patient was seen 1 day later for follow-up in the Ophthalmology Clinic. The patch was removed and the eyelids were easily separated at that time by peeling off the polymerized glue. A 0.12-mm forceps was gently used to remove the residual pieces of glue from the lid margin and lashes. Few lashes were epilated, and no material was found in the fornices. Vision in the left eye remained 20/200, equal to her preaccident acuity secondary to substantial lenticular changes and diabetic retinopathy. The patient was seen 1 month later and found to have entirely normal lid and lash anatomy.

Case 2

A 55-year-old man with noninsulin-dependent diabetes mellitus and background diabetic retinopathy mistakenly instilled 1 drop of Crazy Glue (cyanoacrylate) in the left eye instead of artificial tears. He called his family physician, who prescribed polymyxin B-bacitracin-neomycin-hydrocortisone eye drops by telephone. The following day he noted increased pain, photophobia, and decreased vision in the left eye. He was then referred to one of the authors. Visual acuity was 20/25 in the right eye and 20/200 in the left eye. Slit lamp examination showed hardened glue fragments on the base of the lids and many of the lashes of the left eye. In the lower conjunctival fornix of the left eye, two large pieces of polymerized glue were found. There was a 7-mm × 6-mm epithelial defect on the cornea (Figure 3). The foreign particles were removed from the fornix, lashes, and lid margins with 0.12-mm forceps. Many lashes were epilated during this procedure.

Submitted, revised, 21 July 1995.

From the Department of Ophthalmology, Scheie Eye Institute, University of Pennsylvania School of Medicine, Philadelphia (SPB, ABL), and the Department of Surgery, Division of Ophthalmology, Lehigh Valley Hospital, Allentown, Pennsylvania (ABL). Address reprint requests to Alan B. Leahey, MD, 400 North 17th Street, Suite 102, Allentown, PA 18104.

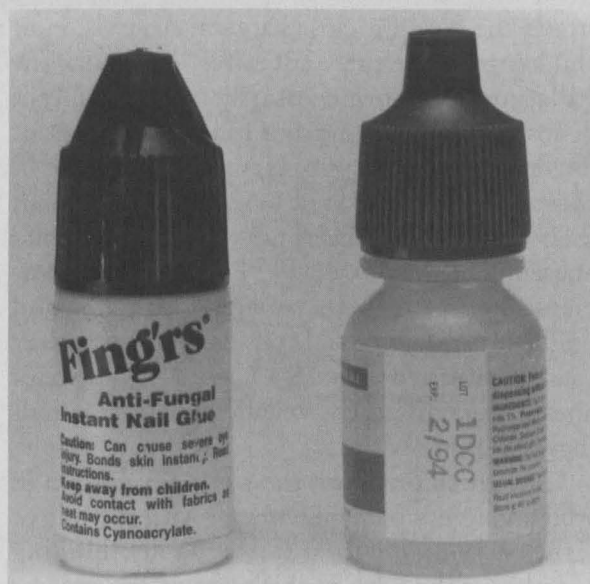

Figure 1. Example of a cyanoacrylate adhesive container (left) that resembles a typical ophthalmic medication bottle (right).

The patient was prescribed tobramycin eye drops 4 times daily, a bandage contact lens was applied, and he was seen daily for follow-up care. His epithelial defect was totally healed by the 3rd day, and his vision in his left eye returned to 20/30. Six months after this incident the patient was seen for a routine examination at which time his lid and lash anatomy was normal.

Case 3

A 5-year-old boy was brought to the emergency department 2 hours after accidentally wiping Super Glue Gel (cyanoacrylate) into his right eye. The child complained of right eye pain and an in-

ability to see anything from the right eye. Vision in his right eye was restricted to light perception through closed lids and was 20/20 in his left eye. Slit lamp examination showed that the right eye-lids were stuck together with a substantial amount of glue along the lid margins and lashes. The lower lid was slightly everted. The lids could not be opened mechanically, and the child resisted further examination or manipulation. The child was taken to the operating room, where chloral hydrate sedation was used to allow further examination and treatment. Once the boy was sedated, acetone-soaked cotton swabs were carefully used to dissolve the cyanoacrylate along the lid margins and lashes. After the lids were separated, an eccentric 1-mm \times 2-mm corneal abrasion was observed through the operating microscope. No fragments of polymerized glue were found in the fornices; however, one small 1-mm \times 2-mm fragment was adherent to the cornea and was easily removed with 0.12-mm forceps. The patient was treated with polymyxin B-bacitracin ointment and a pressure patch for 1 day, followed by ciprofloxacin eye drops 4 times a day, and was seen for follow-up care on a daily basis. Three days after the accident the corneal abrasion was completely healed, and visual acuity in his right eye returned to 20/20. External lid and lash anatomy was entirely normal.

Discussion

Although cyanoacrylate tissue adhesives have numerous applications in clinical ophthalmology, including the treatment of corneal perforations,⁹ corneal thinning,¹⁰ and leaking filtering blebs,¹¹ this brief report focuses on the inadvertent ad-

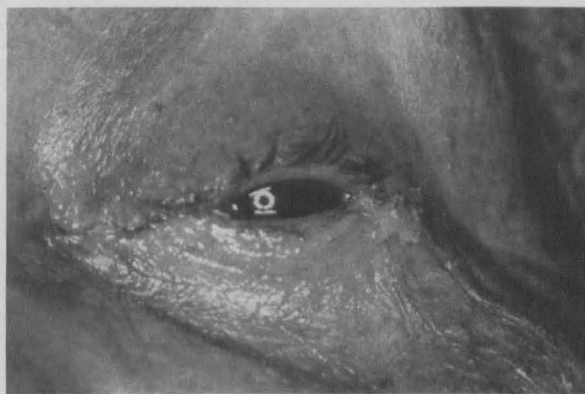
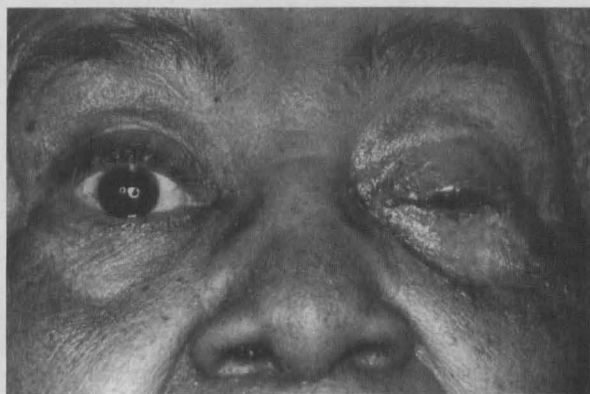
Figure 2. Case 1. Left: the patient 4 hours after accidental instillation of cyanoacrylate adhesive into the left eye. Right: polymerized glue fragments are apparent along the medial and lateral edges of the horizontal fissure of the left eye. Note sparing of the central horizontal fissure, which allows examination of the entire cornea.

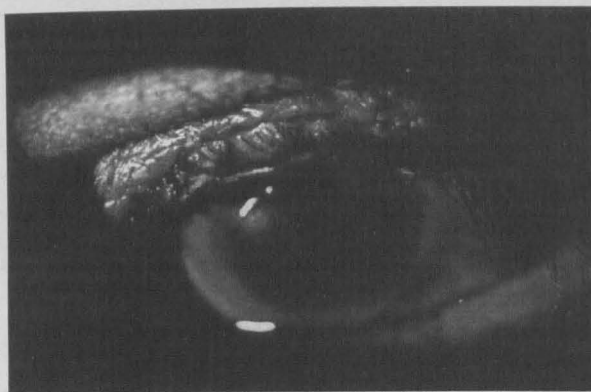

Figure 3. Case 2. The patient 24 hours after accidental instillation of cyanoacrylate adhesive into the left eye. An abrasion is present in the superonasal aspect of the cornea. Note the polymerized glue fragments along the base of the upper lashes. Some lashes have already been trimmed.

ministration of this compound and management guidelines for primary care physicians. In contrast to the accidents reported here, clinical adhesive administration is always performed under meticulously controlled conditions and with fastidious clinical follow-up care. Accidental instillation of cyanoacrylate in the eye remains a source of potentially serious ocular morbidity that should be easily prevented. Patient education combined with physician awareness can prevent complicating sequelae of this type of accident. The cases reported here serve to illustrate the key teaching points in understanding the cause and management of accidental cyanoacrylate exposure in the eye.

First, and foremost, prevention of such accidents needs to be addressed. Despite 10 years of published reports attributing such accidents to the similar packaging of cyanoacrylate and ophthalmic medicines and preparations,^{1,2,6} glue manufacturers have yet to answer the professional pleas to change their package. Persons with normal vision have carelessly instilled glue in their eyes, and visually impaired individuals honestly have mistaken the glue for their ocular medicine or artificial tears. Warning labels are not sufficient, in part because many accidents occur in those who are partially sighted and unable to read small print and who require the regular administration of ophthalmic medications. Mishaps of this variety could be prevented if glue were dispensed in containers that did not at all resemble ophthalmic preparations. The third case demon-

strates the need for close parental supervision of children who use these adhesives. Accidental instillation does not necessarily occur by direct deposition into the eye but can be the result of finger to eye inoculation, as was the case here. In some instances children have received glue in their eyes, not by accident, but as an act of child abuse inflicted by parents.^{3,5} Primary care physicians, emergency department physicians, and ophthalmologists should consider child abuse as a cause when children with a history suggestive of abuse or an unusual constellation of physical findings are examined.

Case 1 demonstrates the simple condition in which glue has come in contact with the lids or lashes causing a partial tarsorrhaphy (binding together of the lids). In this scenario the eye was painless, and the cornea was amenable to examination and found not to be involved. Although some have initially chosen not to intervene but to allow the lids to separate naturally in several days,^{5,12} others advocate immediate manual separation.¹ Several clinicians have reported easy lid separation 1 day after pressure patching with either a polymyxin B-bacitracin-neomycin ophthalmic ointment,² water,⁷ or mineral oil.^{13,14} We achieved the same success with polymyxin B-bacitracin ophthalmic ointment. It is our recommendation that uncomplicated tarsorrhaphies which do not involve or threaten the cornea or conjunctiva be conservatively managed by pressure patching with mineral oil or antibiotic ointment and daily follow-up to peel away the adhesive easily (Figure 4).

Case 2 represents a slightly more complicated condition wherein there coexists a partial tarsorrhaphy and a corneal abrasion with retained glue fragments. First, prescribing steroid-containing eye drops by telephone by the family physician was clearly wrong. Administration of these drops can lead to exacerbation of the injury, especially if the eye is contaminated by a fungal or viral source. Additionally, the use of steroid drops can mask the symptoms of corneal injury and infection, potentially leading to a far worse outcome. The only acceptable eye drop in this setting is a broad-spectrum antibiotic, such as tobramycin, polymyxin B-bacitracin, or ciprofloxacin, which is used to prevent an infectious keratitis. The subsequent application of a bandage contact lens by the ophthalmologist was specifically for the treat-

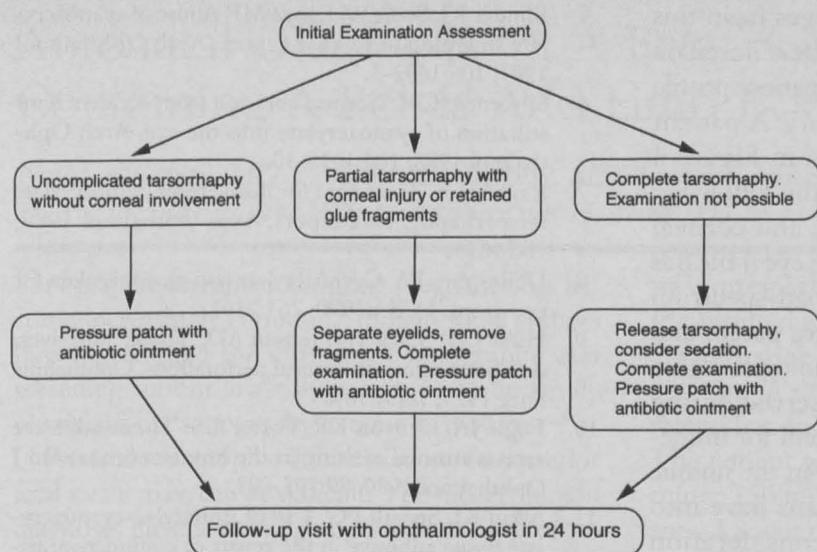


Figure 4. Patient evaluation flow chart. Technical or clinical complications at any point in this algorithm require immediate referral to an ophthalmologist.

ment of a large corneal abrasion. Healing in this diabetic patient would have likely been delayed several days if only simple patching and ointment were used. The application of such a bandage lens should be performed only by an ophthalmologist and, as such, requires careful follow-up. In general, bandage contact lenses are often used in patients intolerant of patching or those who will otherwise have considerable pain, as in case 2.

Furthermore, with a known injury to the cornea and fragments of polymerized glue in the fornix, it is important to perform a complete eye examination quickly. This examination necessitates prompt release of the tarsorrhaphy and removal of the cyanoacrylate fragments. Complications of retained adhesive fragments include infectious keratitis,¹⁵ giant papillary conjunctivitis,¹⁶ cataracts,¹⁷ and granulomatous keratitis.¹⁸ The lids can be opened by manual separation, careful dissection with forceps or scissors, or dissolution of the adhesive with pure acetone. Special care must be used when acetone is applied to the lid margins or the cornea itself, and ideally patients requiring such treatment should be referred to an ophthalmologist for this treatment. Although acetone is a good solvent for cyanoacrylate adhesives, and it has no permanent effect on the cornea or conjunctiva,¹⁹ it should not be used where a penetrating wound is present or suspected. For this reason, a careful history of potential trauma to the affected eye is crucial. Simple accidents in-

volving direct installation of glue into the eye by mistake are not likely to be associated with penetrating trauma. Acetone that enters the anterior chamber, or any intraocular region, can cause devastating destruction and should be avoided if at all possible. Additional means of removing polymerized adhesive include the use of neodymium:YAG laser.²⁰ It is our recommendation, therefore, that in the face of corneal injury or the possibility of retained or adherent glue fragments, appropriate steps be taken to ensure a complete ophthalmic examination in a timely manner.

Lids should be separated by the techniques described above, retained glue fragments fastidiously removed by forceps or acetone, and abrasions treated in a routine fashion with broad-spectrum antibiotic drops and daily follow-up until healing is complete.

Case 3 highlights several other important factors that help to guide treatment. First, when an eye is completely shut, it is essential to perform a complete examination so that retained glue fragments or ocular injury can be treated expeditiously. In the case presented here, in which the child complained only of vague pain, both of the aforementioned conditions were found once the lids were separated. Release of the tarsorrhaphy in pediatric patients or in adults who are uncooperative might require sedation or anesthesia. Clearly, in those individuals unfortunate enough to have glue instilled in both eyes, appropriate measures to reverse the tarsorrhaphies and restore functional vision must be undertaken immediately. As noted above, options include acetone dissolution of adhesive or surgical intervention with clipping of the dried glue and matted lashes. In general, broad-spectrum antibiotic ointment, rather than drops, is prescribed for children because of its relative ease of administration for the parents.

The illustrative cases reported here are used to establish guidelines for the prevention and treatment of accidental instillation of cyanoacrylate

adhesive into the eye. What emerges from this discussion is that each case should be tailored on an individual basis according to the patient profile and the clinical setting of the injury. A patient evaluation flow chart is presented in Figure 4 and has as its principle guidelines the following: (1) evaluate the eyelids, fornices, and cornea; (2) take simple measures to open the eye if the lids are glued shut; (3) prescribe a broad-spectrum antibiotic ointment with a pressure patch; and (4) refer the patient to an ophthalmologist within 24 hours. If complications are observed during the initial assessment, refer the patient for immediate ophthalmic consultation. Given the unique insight that primary care physicians have into whole family dynamics, special consideration should be afforded to children who seek care with this condition. Physicians are obliged to consider the unfortunate possibility of child abuse. Of equal importance perhaps, these cases demonstrate the continuing need for additional measures to prevent such accidents. We strongly recommend that manufacturers change the shape of their bottles or add safety caps to make their use more difficult.

References

1. Margo CE, Trobe JD. Tarsorrhaphy from accidental instillation of cyanoacrylate adhesive in the eye. *JAMA* 1982; 247:660-1.
2. Kimbrough RL, Okereke PC, Stewart RH. Conservative management of cyanoacrylate ankyloblepharon: a case report. *Ophthalmic Surg* 1986; 17(3):176.
3. Awan KJ. Accidental and abusive aspects of cyanoacrylate adhesive. *Pakistan J Ophthalmol* 1987; 3(3):73-4.
4. Allar RM. Most cyanoacrylate super-glues should be removed promptly. *Ophthalmic Surg* 1987; 18(2):156.
5. Blinder KJ, Scott W, Lange MP. Abuse of cyanoacrylate in child abuse: case report. *Arch Ophthalmol* 1987; 105:1632-3.
6. Silverman CM. Corneal abrasion from accidental instillation of cyanoacrylate into the eye. *Arch Ophthalmol* 1988; 106:1029-30.
7. Raynor LA. Treatment for inadvertent cyanoacrylate tarsorrhaphy: case report. *Arch Ophthalmol* 1988; 106:1033.
8. DeRespinis PA. Cyanoacrylate nail glue mistaken for eye drops. *JAMA* 1990; 263:2301.
9. Hirst LW, Stark WJ, Jensen AD. Tissue adhesives: new perspectives in corneal perforations. *Ophthalmic Surg* 1979; 10(3):58-64.
10. Fogle JA, Kenyon KR, Foster CS. Tissue adhesive arrests stromal melting in the human cornea. *Am J Ophthalmol* 1980; 89:795-802.
11. Awan KJ, Spaeth PG. Use of isobutyl-2-cyanoacrylate tissue adhesive in the repair of conjunctival fistula in filtering procedures for glaucoma. *Ann Ophthalmol* 1974; 6:851-3.
12. Maitra AK. Management of complications of cyanoacrylate adhesives. *Br J Clin Pract* 1984; 38(7-8): 284-6.
13. Bock GW. Skin exposure to cyanoacrylate adhesive. *Ann Emerg Med* 1984; 13:486.
14. Dean BS, Krenzelok EP. Cyanoacrylates and corneal abrasion. *Clin Toxicol* 1989; 27(3):169-72.
15. Leahey AB, Gottsch JD, Stark WJ. Clinical experience with N-butyl cyanoacrylate (Nexacryl) tissue adhesive. *Ophthalmology* 1993; 100(2):173-80.
16. Carlson AN, Wilhelmus KR. Giant papillary conjunctivitis associated with cyanoacrylate glue. *Am J Ophthalmol* 1987; 104:437-8.
17. Gudas PP, Altman B, Nicholson DH, Green WR. Corneal perforations in Sjogren syndrome. *Arch Ophthalmol* 1973; 90:470-2.
18. Ferry AP, Barnert AH. Granulomatous keratitis resulting from use of cyanoacrylate adhesive for closure of perforated corneal ulcer. *Am J Ophthalmol* 1971; 72:538-41.
19. Turss U, Turss R, Refojo MF. Removal of isobutyl cyanoacrylate adhesive from the cornea with acetone. *Am J Ophthalmol* 1970; 70:725-8.
20. Martinez LA, Miller KN, Brown RH, Lynch MG. The Nd:YAG laser removal of cyanoacrylate used to repair conjunctival wound leaks. *Am J Ophthalmol* 1989; 108:86-7.