

Severe Scleredema Diabeticorum And Insulin Resistance

Bruce E. Wilson, MD, and Jeffrey J. Newmark

Scleredema, an unusual disorder of the skin, is associated with symmetric induration and thickening of the skin generally on the posterior neck and the upper back.¹⁻⁴ Scleredema is classified into two types, scleredema adultorum of Buschke and scleredema diabeticorum.^{4,5} Scleredema adultorum of Buschke is more commonly diagnosed in children, despite the term adultorum, and is usually preceded by an acute infection, often streptococcal. Clinically, this type can easily be recognized by observing the patient's indurated, nonpitting skin. Although there have been cases in which internal organs are involved by scleredema, the disease usually enters remission without any treatment within 18 months. Scleredema diabeticorum is generally associated with non-insulin-dependent diabetes mellitus (NIDDM).^{1,6,7} While this second type of scleredema involves the upper back and neck in a manner similar to the Buschke type, scleredema diabeticorum can involve a more extensive region of the body, extremities, and internal organs. Scleredema diabeticorum can persist for many years, and there is no effective therapy. Histologically, the dermis is characterized by hyperplasia of collagen and increased accumulation of glycosaminoglycans and hyaluronic acid in both types of scleredema.

Case Report

The patient, a 64-year-old African-American man, had a 21-year history of NIDDM and required insulin therapy for the last 9 years. During the last 3 years, he reported progressively increasing insulin requirements, and at the time of

our examination he was administering 300 units of human insulin daily. Five years earlier he had noted dark, thickened skin on his neck, which had since extended to his axillae. During the previous 3 years he developed progressive thickening and hardening of his skin and subcutaneous tissue of his neck, shoulders, upper extremities, and back. This skin change progressively worsened until his upper body mobility was impaired to the point that he could barely dress himself.

The patient's medical history was remarkable for a coronary artery bypass grafting procedure 9 years earlier and a 13-year history of hypertension. The patient's father also had NIDDM.

The physical examination revealed an older man, 5 feet, 7 inches tall, weighing 241 pounds. Proliferative retinopathy was apparent on funduscopic examination. The skin of the neck and axilla region had thickened, black areas with numerous skin tags. The upper back, shoulder, and proximal upper extremities had firm indurated skin, subcutaneous tissue that did not pit with pressure, and diminished hair growth (Figures 1 and 2). He was not able to abduct his arms past 90 degrees and could rotate his neck in an arc of only 90 degrees.

Laboratory results were as follows: creatinine clearance 125 mL/min, 24-hour urine total protein of 1600 mg/24 h (normal: less than 100 mg/24 h), and a serum creatinine of 1.2 mg/dL (normal: 0.6–1.2 mg/dL). Early morning cortisol was 9.0 µg/dL (normal: 7.0–25 µg/dL), thyroid-stimulating hormone 4.0 µU/mL (normal: 0.4–5.6 µU/mL), growth hormone 1.5 ng/mL (normal: 0–6.5 ng/mL), insulin-like growth factor 1 (IGF-1) 96.8 ng/mL (normal: 123–463 ng/mL). Antibodies to the insulin receptor were not present; however, there were antibodies present to insulin. Microscopic examination of a skin biopsy of his back revealed thickly packed collagen bundles throughout the dermis with matrix material of glycosaminoglycans consistent with scleredema.

Submitted, revised, 2 September 1994.

From the Division of Endocrinology and Metabolism, University of Nevada School of Medicine, Las Vegas (BEW), and Harvard College, Cambridge, MA (JJN). At the time the paper was written, Jeffrey Newmark was a summer research fellow, University of Nevada School of Medicine. Address reprint requests to Bruce E. Wilson, MD, Division of Endocrinology and Metabolism, University of Nevada School of Medicine, 2040 West Charleston Blvd., #503, Las Vegas, NV 89102.

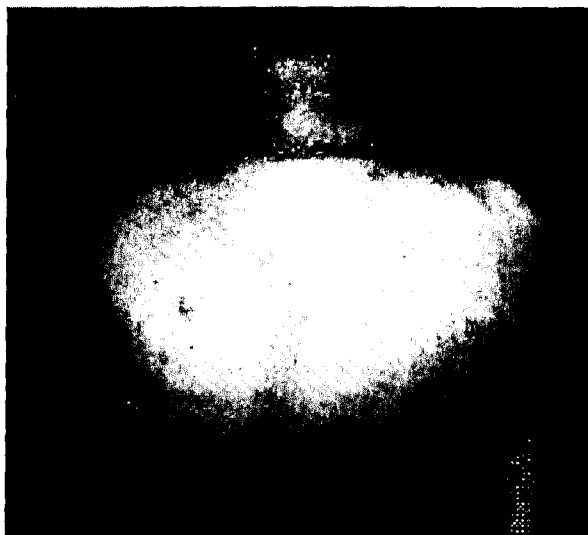


Figure 1. Scleredema diabeticorum affecting the patient's neck, back, and proximal upper extremities. The affected skin is indurated and thickened; hair loss is also present. Acanthosis nigricans is seen on the patient's neck.

Discussion

Scleredema diabeticorum is generally reported to be a rare disorder of the skin.⁴ There have been approximately 140 cases reported in the literature.^{4,6} In contrast, Sattar and colleagues⁶ reported that scleredema occurred in 14 percent of their hospitalized diabetic population and suggested that earlier low estimates of prevalence were due to a lack in physician recognition. Others have suggested that the prevalence of scleredema diabeticorum is 2.5 percent.⁷ In these series, the affected patients were not described in detail, and many could have had subclinical scleredema, which does not conform to the extensive scleredema generally described in NIDDM.¹⁻³ This disorder usually occurs in middle-aged patients with NIDDM, obesity, and microvascular complications of diabetes mellitus. In insulin-dependent diabetes (IDDM), changes in skin thickness and joint mobility have been reported (waxy skin syndrome) that are distinct from scleredema.⁴ It has been suggested that these changes in IDDM are secondary to the irreversible glycosylation of collagen and subsequent inefficiency of collagen proteolysis and removal.⁸ The pathogenesis of scleredema in NIDDM is thus far undefined.

We describe a patient with long-standing NIDDM who had scleredema diabeticorum with associated acanthosis nigricans. Acanthosis nigri-

cans, confluent areas of darkened epidermal thickening that appear in the axillae, neck, groin, and intertriginous areas, is often seen in patients with NIDDM with considerable insulin resistance, obesity, or internal malignancies.⁹ Our patient had microvascular and macrovascular complications of diabetes mellitus and had moderate insulin resistance. Although our patient had a normal creatinine clearance, he had marked proteinuria. Certain diabetic patients, especially those with concomitant hypertension, can manifest proteinuria prior to a decline in glomerular filtration rate. A component of his insulin resistance could have been due to anti-insulin antibodies, which were most likely initiated by his previous therapy with porcine and bovine insulin. There were no clinical or laboratory data to suggest a secondary cause of insulin resistance, such as cortisol or growth hormone excess or an occult malignancy. In fact, his serum IGF-1 was low, which is often seen with aging.¹⁰ Because insulin is a growth factor for connective tissue in the pathogenesis of atherosclerosis,¹¹ it is plausible that the pathogenesis of scleredema in NIDDM is related to excessive insulin-stimulated collagen synthesis. Excess collagen deposition in the cutaneous tissue could be subjected to glycosylation, cross-linking, and abnormal structure formation resistant to collagenase degradation and removal.¹²

Although many reports of scleredema diabeticorum have stated that this complication of




Figure 2. Lateral view of the raised, indurated scleredematous tissue of the upper back and neck.

diabetes mellitus is innocuous,^{6,7} we report a case of scleredema that caused our patient considerable disability. It is likely that less severe cases of scleredema diabeticorum are relatively common; however, the type of extensive cutaneous involvement seen in our patient remains quite unusual. The association of scleredema with NIDDM and insulin resistance might suggest that the underlying cause of scleredema is related to the effects of hyperinsulinemia on cutaneous collagen synthesis.

References

1. Cohn BA, Wheeler CE Jr, Briggaman RA. Scleredema adultorum of Buschke and diabetes mellitus. *Arch Dermatol* 1970; 101:27-34.
2. Fleischmajer R, Faludi G, Krol S. Scleredema and diabetes mellitus. *Arch Dermatol* 1970; 101:21-6.
3. Beeaff DE, Lazar P. Scleredema adultorum. *Arch Dermatol* 1980; 116:1347-8.
4. Jelinek JE. Skin disorders associated with diabetes mellitus. In: Rifkin H, Porte D Jr, editors. *Diabetes mellitus: theory and practice*. 4th ed. New York: Elsevier, 1990:841-2.
5. Buschke A. Ueber scleredema. *Klin Wochenschr* 1902; 39:955.
6. Sattar MA, Diab S, Sugathan TN, Sivanandasingham P, French FF. Scleredema diabeticorum: a minor but often unrecognized complication of diabetes mellitus. *Diabet Med* 1988; 5:465-8.
7. Cole GW, Headley J, Showsky R. Scleredema diabeticorum: a common and distinct cutaneous manifestation of diabetes mellitus. *Diabetes Care* 1983; 6:189-92.
8. Collier A, Matthews DM, Kellett HA, Clarke BF, Hunter JA. Change in skin thickness associated with cheiroarthropathy in insulin dependent diabetes mellitus. *Br Med J* 1986; 292:936.
9. Olefsky JM, Molina JM. Insulin resistance in man. In: Rifkin H, Porte D Jr, editors. *Diabetes mellitus: theory and practice*. 4th ed. New York: Elsevier, 1990:149-151.
10. Iranmanesh A, Lizzaralde G, Veldhuis JD. Age and relative adiposity are specific negative determinants of the frequency and amplitude of growth hormone (GH) secretory bursts and the half-life of endogenous GH in healthy men. *J Clin Endocrinol Metab* 1993; 73:1081-8.
11. Stout RW. Insulin and atheroma: 20 year perspective. *Diabetes Care* 1990; 13:631-54.
12. Brownlee M, Cerami A, Vlassara H. Advanced glycosylation end products in tissue and the biochemical basis of diabetic complications. *N Engl J Med* 1988; 318:1315-21.