

Carpal Boss and the Differential Diagnosis of Dorsal Hand Masses

David duBrutz Lewis, MD

Although the dorsal wrist ganglion is by far the most common soft tissue mass of the hand, there are other lesions that can mimic the ganglion. Family physicians must be able to recognize the variety of dorsal hand masses to ensure appropriate patient education and proper therapy. Because of the appearance and occasional discomfort associated with these lesions, young healthy patients frequently seek medical attention. Fortunately, the majority of these lesions can be treated conservatively, and almost all are benign. Carpal boss is a condition frequently mistaken for a ganglion cyst; however, the two conditions can be differentiated clinically. When there is uncertainty, a unique radiographic view can help make the diagnosis.

Case Report

An otherwise healthy 28-year old man sought treatment for a nonpainful mass on the dorsum of his right hand that had been present for approximately 8 years. The patient had been seen by a physician 3 years previously, at which time a diagnosis of a dorsal ganglion cyst was made. The mass had always been nonpainful, and since being seen, it had not changed in size. The patient's complaint was of a cosmetic nature with an occasional awareness of the extensor tendons sliding over the mass.

Physical examination of the right wrist showed a 1.5 cm × 1.5 cm bony prominence that was 0.5 cm high located on the dorsal surface at the base of the second and third carpometacarpal joints. The mass was hard, nontender, and unmovable. The wrist had full range of motion. The extensor tendons abruptly slipped over the bony prominence with alternating radial and ulnar deviation of the hand while in volar flexion. A roentgenogram was obtained and revealed carpal boss (Figure 1).

Submitted, revised, 11 January 1994.

From the Department of Community and Family Medicine, Duke University Medical Center, Durham, NC. Address reprint requests to David duBrutz Lewis, MD, Department of Community and Family Medicine, Box 3886, Duke University Medical Center, Durham, NC 27710.

Discussion

Carpal boss was first described by Fiolle,¹ a French physician, in 1931 when he described the lesion on his own right wrist. He believed his to be primarily a carpal lesion involving the capitate and third metacarpal base and thus coined the term *carpe bossu* (carpal boss). In 1941 Carter² reported six cases of carpal boss of which five had symptoms of pain in the affected hand. Two patients underwent surgical therapy; both experienced recurrences.

The carpometacarpal boss appears as an unmovable protuberance over the dorsum of the hand at the base of the second or third metacarpals and their articulations with the trapezoid and the capitate. Occasionally, all four bones will be involved. Pain or local tenderness can be associated with the mass. When present, the pain typically imitates that of degenerative joint disease, being aggravated by repetitive use, especially extension, and improving with rest. There is characteristically no limitation of wrist motion. These symptoms have been attributed to an overlying ganglion cyst or inflamed bursa, tenosynovitis related to the extensor tendons slipping over the prominence, or localized osteoarthritic changes at the site.³ The localized degenerative disease is thought to result from an inability of the abnormal joint configuration to withstand the normal daily stress placed on it. The symptomatic carpal boss occurs more frequently on the right hand, and there is evidence to suggest it appears more often in women.⁴

Various explanations for carpal boss exist, which include a nonunited chip fracture at the base of the second or third metacarpals, periostitis at the site of insertion of the radial wrist extensor tendons, and peritendinitis calcarea. Most authors agree, however, that the mass represents a hypertrophic lipping of the carpometacarpal joints that is associated with an acquired post-traumatic laxity of the involved joints.⁵

Carpal boss is frequently mistaken for a ganglion cyst; however, the common dorsal ganglions of the wrist usually occur more proximally

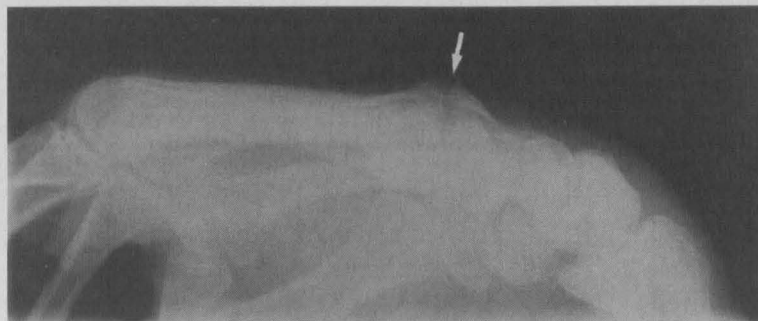


Figure 1. Modified lateral view of the patient's right hand. Note the hypertrophic lippling and preserved joint space (arrow) characteristic of carpal boss.

(arising from the scaphoid-lunate ligament), have a cystic consistency, and are easily transilluminated. In addition to a ganglion, the differential diagnoses include other lesions that arise from synovial tissue (giant cell tumors), as well as from fat (lipomas) and from nerves (traumatic neuromas, neurofibromas, and neurilemmomas). Lesions that arise from bony structures are often mistaken for carpal boss, such as congenital accessory ossicles (os styloidium and os epilunatum), intraosseous ganglia, enchondromas, osteochondromas, and osteoid osteomas. Most tumors of the wrist and hand are benign with the exception of osteosarcomas and malignant tumors from metastatic disease. Although the incidence of metastatic tumors to the hand bones parallels that of the primary tumor (breast, lung, kidney), the true incidence of carpal boss is difficult, if not impossible, to ascertain because most reports group it with other lesions of the hand.

The diagnosis of carpal boss is made by clinical and radiological examinations. The radiographic appearance of a carpal boss is characteristic; however, it is difficult to show on posteroanterior and lateral views. The optimal examination is the modified lateral view (after Cuono and Watson⁴) with the wrist in 20 to 30 degrees of supination and ulnar deviation. The boss appears as a dorsal overgrowth of the bones involved usually without sclerosis of the joint margin or narrowing of the cartilage space (Figure 1).

Therapy for painful carpal boss consists of reassurance to the patient, nonsteroidal anti-inflammatory agents, and limited use of the involved hand. Local steroid injection can be beneficial, especially if periostitis or peritendinitis calcarea is thought to be a causative factor. Although Carter concluded that surgery was contraindicated because of the prompt recurrence of the lesion, a more recent study reported no recurrences at a mean

follow-up of 3.5 years in a series of 30 patients who underwent surgical resection.⁴ Surgery is directed at complete excision of the bony abnormality so that good cartilage is visible on both sides of all four joints, forming a slight cancellous concavity.

Conclusion

Symptomatic carpal boss is a treatable clinical entity that occurs in relatively young patients. The condition most likely represents a localized degenerative arthritis at the site of the second and third carpometacarpal articulations. Diagnosis is made when there is high clinical certainty and radiographic findings are characteristic. Although frequently misdiagnosed as a ganglion, carpal boss should be suspected in patients who have a hard bony mass on the dorsum of the hand.

References

1. Fiolle J. Le carpe bossu. *Bull et Mem Soc Nat'l Chir* 1931; 57:1687-90.
2. Carter RM. Carpal boss: a commonly overlooked deformity of the carpus. *J Bone Joint Surg* 1941; 23:935-40.
3. Conway WF, Destouet JM, Gilula LA, Bellinghausen HW, Weeks PM. The carpal boss: an overview of radiographic evaluation. *Radiology* 1985; 156(1):29-31.
4. Cuono CB, Watson HK. The carpal boss: surgical treatment and etiological considerations. *Plast Reconstruct Surg* 1979; 63(1):88-93.
5. Joseph RB, Linscheid RL, Dobyns JH, Bryan RS. Chronic sprains of the carpometacarpal joints. *J Hand Surg* 1981; 6:172-80.