

Left-Sided Leg Edema Of The Elderly: A Common Variant Of The Iliac Compression Syndrome

Philip D. Sloane, MD, MPH, Ruth Baldwin, PhD, Royce Montgomery, PhD, Franklin Hargett, MD, MPH, and Abraham Hartzema, PharmD, MSPH

Abstract: Background: Anatomically, the right common iliac artery crosses the left iliac vein and its accompanying lymphatics. We hypothesized that this situation could lead to a predominance of edema, telangiectasis, and venous varicosities on the left lower extremities of older persons.

Methods: To test this hypothesis, a research assistant who was blinded to the study goals examined 215 predominantly elderly residents of North Carolina homes for the aged and disabled.

Results: Among these subjects, 17.7 percent had predominantly left-sided edema, and 5.7 percent had predominantly right-sided edema ($P < 0.001$). When the 88 subjects with pitting edema greater than 3 mm were studied, 34.5 percent showed a left-sided predominance, and 6.9 percent showed a right-sided predominance ($P < 0.001$). In contrast, no significant difference was found in the lateralization of venous varicosities or of telangiectasis.

Conclusions: Asymmetric edema is common and is usually left-sided in older persons. Compression of the left common iliac vein and its accompanying lymphatics by the right iliac artery, rather than overt clinical disease, might explain the majority of asymmetric edema seen in clinical practice. (J Am Board Fam Pract 1993; 6:1-4.)

Physicians in internal medicine, general practice, family medicine, and a variety of medical and surgical subspecialties often encounter patients with peripheral edema and other physical signs of venous disease. Examination of such patients can be extensive, because these conditions can arise from systemic or local causes. When edema or varicosities are unilateral or asymmetric, causes local to the involved extremity are implicated. The most common causes of unilateral or regional leg edema are reported to be chronic venous insufficiency and thrombophlebitis.^{1,2} Often medical textbooks recommend an intense search for causes of lymphatic obstruction in such patients, such as malignancy in the inguinal nodes or deep venous thrombosis.³⁻⁵

We had observed informally that venous disease was more common on the left side, yet we found no published reports to confirm that observation. Anatomically, such an occurrence is logical, because the right iliac artery crosses the venous and lymphatic drainage system returning from the left leg (Figure 1). We reasoned that, with age, any compression produced by the right iliac artery might be manifest as an increased occurrence and greater severity of venous varicosities, telangiectasis, and edema on the left side when compared with the right.

To test our hypothesis, we conducted systematic observations on the peripheral vascular status of 215 residents of North Carolina rest homes. These observations were performed by a blinded observer who was gathering observational data as part of a larger, unrelated study.

Methods

The data for this project were collected as part of a larger study conducted by the University of North Carolina Center for Health Promotion and Disease Prevention of homes for the aged (HAs), a type of domiciliary care facility. The purpose of the larger study was to improve the management of medications in HAs through educational inter-

Submitted, revised, 18 August 1992.

From the Department of Family Medicine, School of Medicine (PDS, FH); School of Pharmacy (RB, AH); and Department of Anatomy, School of Medicine (RM); University of North Carolina at Chapel Hill. Address reprint requests to Philip D. Sloane, MD, MPH, Department of Family Medicine, The University of North Carolina, Campus Box 7595, Chapel Hill, NC 27599-7595.

This research was supported in part by a grant from the John Hartford Foundation. Dr. Sloane is a recipient of Academic Award No. 1 K08 AG00341-01 from the National Institute on Aging.

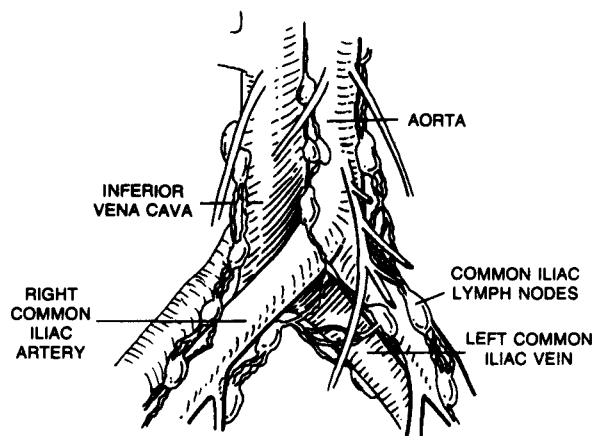


Figure 1. Anatomic relation of the common iliac arteries and veins and their associated lymphatic vessels. Crossing of the left iliac vein and its accompanying lymphatic channels by the right iliac artery could lead to increased pressures in the venous and interstitial systems of the left leg relative to the right.

vention. The study sampling frame consisted of the 194 HAs with more than 20 beds located in North Carolina counties with populations of at least 50,000. A two-stage stratified cluster sampling method was used to obtain a sample of 35 homes.

After homes were selected, between 16 and 26 residents in each home were enrolled in the study. The inclusion criteria for residents were use of two or more medications, at least one of which was a psychoactive, an antihypertensive, or an anti-parkinsonian agent. A total of 826 residents were selected, of which 746 were enrolled. Of these, a subsample was randomly selected for study using direct (observational) methods to verify the indirect (reported) measures that constituted the primary outcome variables of the study. These direct observations included evaluation of mental status, mobility, level of consciousness, and the presence or absence of signs of tardive dyskinesia.

The data reported here were collected as part of these direct observations. A standardized protocol was designed by the investigators for recording observational data on varicosities, edema, and telangiectasis. Edema was defined as soft tissue swelling that pits; varicose veins were defined as visible veins greater than 5 mm observed above the ankle; telangiectasis was defined as a network of bluish, black, or red vessels, usually tortuous, observed on or below the ankle. Before going into the field, the research assistant performing direct observations was trained by the primary author (PDS) in use of the protocol; training involved explanation of the protocol and joint physical assessments in a local nursing home. The data collector was not apprised of the study's goals or hypotheses. Data from the precoded assessment forms were entered into a computerized database and analyzed using the Statistical Analysis System (SAS).⁶ To test for significant differences between groups, the McNemar test for related samples was used.

Results

There were 215 subjects examined. Their mean age was 69.3 years (range, 26 to 98 years); 75 percent were 61 years of age or older. The majority (70.8 percent) were women. Racially, 77.4 percent were white, 18.9 percent were African-American, and 3.8 percent were classified as other. Among the common diagnoses were dementia (29.6 percent), mental retardation (19.9 percent), psychoses (25.9 percent), hypertension (34.3 percent), cardiac diagnoses (31.0 percent), and arthritis (21.3 percent). Most subjects were able to walk independently (62.6 percent) or with assistance (30.8 percent); 6.6 percent were chair-bound or bed-bound patients.

In this largely geriatric population, edema in which 3 mm or greater of pitting could be produced was present in 40.9 percent of subjects

Table 1. Frequency and Laterality of Edema as Percentage of Subjects Observed (n = 213).

Clinical Observation	Right Leg	Left Leg	Right > Left	Left > Right	χ^2 *	P Value
Pitting edema ≥ 3 mm						
Ankle (n = 213)	20.7	23.5	0.9	5.2	4.92	<0.05
Pretibial (n = 212)	28.3	33.4	2.8	8.0	4.35	<0.05
Subjective comparison of leg edema (n = 209)	—	—	5.7	17.7	11.76	<0.001
Laterality of edema among subjects with ≥ 3 mm leg edema (n = 88)	—	—	6.9	34.5	14.79	<0.001

*McNemar's paired comparison chi-square.

Table 2. Frequency and Laterality of Venous Varicosities and Telangiectasias as Percentage of Subjects Observed (n = 213).

Clinical Observation	Right Leg	Left Leg	Right > Left	Left > Right	χ^2 *	P Value
Visible varicose veins						
Below the knee (n = 212)	69.8	70.8	5.7	7.5	0.32	NS
Above the knee (n = 169)	39.6	36.7	7.1	3.0	2.12	NS
Subjective comparison of extent of venous varicosities (n = 212)	—	—	13.6	16.9	0.55	NS
Subjective comparison of extent of telangiectasias around the ankle (n = 206)	—	—	7.8	8.3	0.00	NS
Laterality of visible varicose veins among subjects with bulging varicosities (n = 32)	—	—	28.1	43.7	0.69	NS

*McNemar's paired comparison chi-square.

NS = not significant.

tested. Whether testing was performed in the pretibial region or at the ankle, edema of the left leg was assigned to a more severe category significantly more frequently than was edema of the right leg (Table 1). The observer subjectively rated 76.6 percent of subjects to have either no edema or no asymmetry, 17.7 percent to have left-sided edema, and 5.7 percent to have right-sided edema. When considering the 88 subjects with marked edema (pitting edema of 3 mm or greater in either the ankle or the pretibial region), this laterality of edema was even more striking: 34.5 percent exhibited left-sided predominance, 6.9 percent showed right-sided predominance, and 58.6 percent appeared equal.

Similar left-sided predominance was not noted among venous varicosities and telangiectasis, however (Table 2). Although visible venous varicosities were common, comparison of the extent of varicosities did not reveal statistically significant differences in laterality either below the knee, above the knee, or overall. Similarly, a subjective comparison of the extent of telangiectasis around the ankle indicated no significant difference between sides.

Discussion

Findings from this study confirm that asymmetric, predominantly left-sided edema is quite common among a largely elderly population living in HAs. The study failed, however, to detect laterality in the extent of venous varicosities or telangiectasis in this population. Because the data collector was not aware of the study goals or hypotheses, we believe that these

statistically significant findings represent true differences.

One explanation for preferential swelling of the left leg compared with the right is anatomic. The left common iliac vein and its accompanying lymphatic channels must pass behind the right common iliac artery, whereas their counterparts on the right flow unimpeded into the inferior vena cava (Figure 1). This anatomic configuration has been implicated as a cause of major venous thrombosis, often followed by severe peripheral edema and postphlebotic syndrome, a rare phenomenon called the iliac compression syndrome or the May-Thurner syndrome.^{7,8} In such cases, which have been primarily reported in young adults, chronic pressure by the artery is believed to lead to fibrosis of the intima of the common iliac vein, causing partial venous obstruction.

The explanation for laterality of edema but not of venous varicosities or telangiectasis is not clear. Possibly these findings reflect that the pathological processes underlying edema are different from those underlying varicosities and telangiectasis. For example, perhaps edema generally reflects alterations in circulation of the entire extremity, whereas varicosities and telangiectasis reflect more local problems. An alternative explanation is that pressure from the right iliac artery has a greater impact on lymphatic circulation than on venous circulation. Finally, because there was a trend for left-sided laterality of venous varicosities among those individuals with the most prominent findings (Table 2), it is possible that our sample size was not large enough to detect differences in this area.

Edema caused by venous disease tends to predominate in the subfascial tissues, whereas lymphostasis tends to result in fluid collection primarily in the interstitial tissues.⁹ Thus, one potential avenue for exploring the basis of these clinical observations would be careful anatomic dissections of the lower extremities of older persons who come to autopsy, comparing the cross-sectional surface area of the left and right common iliac veins and lymphatic channels and looking for the predominant location of edema in those patients with predominantly left-sided swelling. In the future, we hope to carry out anatomic studies to define more clearly the pathophysiologic basis underlying our clinical findings.

For clinicians, we believe that these findings offer a rationale for conservative management of unilateral or asymmetric edema, especially if it is left-sided. We recommend that patients with such findings receive a careful physical examination, with the physician looking for (1) enlarged inguinal or supraclavicular lymph nodes; (2) a palpable abdominal or pelvic mass; (3) clinical signs suggesting thrombophlebitis (e.g., deep tenderness of the calf or thigh, a positive Homan's sign, local warmth, or rapid onset in a patient at high risk); and (4) among chair-bound or bed-bound patients, those positioning factors that could lead to

compression of one extremity. If the results of these clinical examinations are negative, we recommend that no further investigation be conducted to detect local disease and that the patient continue to be observed clinically. In patients with bilateral edema, systemic causes (e.g., congestive heart failure, nephrosis) should be considered.

References

1. Rushchaupt WF, Graor RA. Evaluation of the patient with leg edema. *Postgrad Med* 1985; 78:132-9.
2. Degowin RL. DeGowin & DeGowin's bedside diagnostic examination. 5th ed. New York: Macmillan, 1987.
3. Prior JA, Silberstein JS, Stang JM. Physical diagnosis. St. Louis: C.V. Mosby, 1981.
4. Juergens JL, Spittel JA, Fairbairn JF. Peripheral vascular disease. 2d ed. Philadelphia: W.B. Saunders, 1980.
5. Delaney V, Adler S. Edema. In: Hurst JW, editor. *Medicine for the practicing physician*. 2d ed. Boston: Butterworths, 1988.
6. SAS Institute. SAS user's guide: statistics. 5th ed. Cary, NC: SAS Institute, 1985.
7. Cockett FB, Thomas ML. The iliac compression syndrome. *Br J Surg* 1965; 52:816-21.
8. Ferris EJ, Lim WN, Smith PL, Casali R. May-Thurner syndrome. *Radiology* 1983; 147:29-31.
9. Vaughan BF. CT of swollen legs. *Clin Radiol* 1990; 41:24-30.