

# Subcutaneous Emphysema And Pneumomediastinum In The Postpartum Period

*Eric M. Wall, M.D., M.P.H., Scott Fields, M.D., and Camille Pitre, M.D.*

The Hamman syndrome, pneumomediastinum and subcutaneous emphysema complicating labor and delivery, is infrequently encountered in clinical practice. The prevalence estimates have ranged from 1 in 2000 pregnancies to 1 in 100,000 pregnancies. One hundred ninety-two cases have been reported in the medical literature to date.<sup>1</sup> Reeder,<sup>2</sup> in a review of 187 cases, found that most patients with this complication were primiparous women who developed the syndrome during the second stage of labor and that their first and second stages of labor were for the most part of normal duration.

We report an additional case of the Hamman syndrome to focus more on management of this condition during the postpartum period and to alert family physicians of this possible, yet rare, complication of labor.

## Case Report

An 18-year-old primigravida at 42 weeks' gestation was admitted for elective induction of labor after having a questionably abnormal nonstress test despite a normal contraction stress test and a biophysical profile of 10/10. The patient had an uneventful prenatal course, beginning her prenatal care in the first trimester of pregnancy (gestational age was confirmed at 11 weeks by ultrasonography). Her medical history and family history were unremarkable. The patient was unmarried and living with her parents. She admitted to smoking one-half to one pack of cigarettes daily throughout her pregnancy. There was no history of alcohol or drug use, and results of the patient's prenatal laboratory examinations were normal.

On admission to the labor and delivery area, all findings on physical examination of her head and

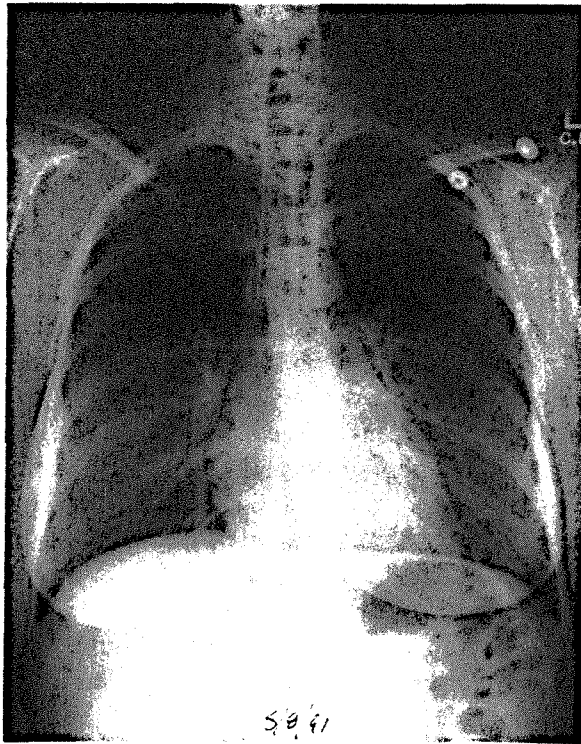
neck were unremarkable. Her lungs were clear, and findings of the cardiovascular examination were within normal limits. Fetal heart tones were in the range of 120 to 130 beats per minute with normal reactivity; her cervix was 2 cm dilated, 80 percent effaced, and the fetus was vertex at 0 station. Oxytocin induction was begun on admission. Epidural anesthesia was administered 4 hours 45 minutes later, when the cervix was 4 cm dilated and 80 percent effaced. Forty-five minutes after the placement of the epidural catheter, the amniotic membranes were ruptured with clear fluid being present. The duration of stage 1 was 3 hours 16 minutes. Stage 2 lasted 3 hours 3 minutes. The patient had a normal spontaneous vaginal delivery requiring vacuum extraction of a male infant weighing 3500 g (7 lb, 13 oz). Apgar scores were 8 at 1 minute and 9 at 5 minutes. The placenta was delivered 6 minutes after stage 2, and the patient had a second-degree midline episiotomy with a third-degree extension.

Three hours after the patient's delivery, she complained to her nurse of upper anterior chest pain and a crackly feeling about her neck and supraclavicular areas. She complained of some inspiratory pain but had no shortness of breath. On physical examination, the patient had normal vital signs with marked crepitus on palpating the anterior and lateral aspects of the neck and anterior chest into the shoulders. Her lungs were clear to auscultation, and results of her cardiovascular examination were normal except for crepitus occurring in synchrony with first and second heart sounds. A radiographic examination was obtained revealing subcutaneous emphysema in the neck and upper chest, as well as a pneumomediastinum (Figure 1). No pneumothorax was noted.

The patient was observed closely for the next 24 hours. After this time, she had partial resolution of her subcutaneous emphysema and reduced inspiratory pain. When she was discharged on the second postoperative day, her

Submitted, revised, 31 October 1991.

From the Department of Family Medicine, School of Medicine, Oregon Health Sciences University, Portland. Address reprint requests to Eric M. Wall, M.D., M.P.H., Department of Family Medicine, Oregon Health Sciences University, 3181 S.W. Sam Jackson Park Road, Mail Code: FP, Portland, OR 97201.



**Figure 1.** Posterior-anterior radiograph revealing subcutaneous emphysema in the neck and upper chest, as well as a pneumomediastinum. No pneumothorax is noted.

symptoms had improved; she had no further complications and subsequently had full resolution of her clinical and radiographic abnormalities.

## Discussion

### *Pathophysiology*

It has been hypothesized that during labor prolonged intense Valsalva maneuvers against a poorly mobile diaphragm might generate sufficient pressures to cause alveolar rupture resulting in subcutaneous emphysema and pneumomediastinum.<sup>3</sup> The air follows the perivascular sheath to the hilum. If air moves between the visceral and parietal pleura, a pneumothorax will result. Although very rare, pneumopericardium has been associated with the Hamman syndrome. Most patients apparently develop the syndrome during the second stage of labor, and the symptoms become evident only a few hours into the postpartum period.

### *Symptoms*

Many symptoms are associated with pneumomediastinum. These include chest pain with

possible radiation to the neck or shoulders, dyspnea, cough, change in voice, anxiety, as well as sounds of crackling in the chest.<sup>3</sup> In addition to her subcutaneous emphysema, the patient also exhibited the presence of the Hamman sign, which is crepitus in synchrony with the heartbeat. No electrocardiogram was performed. Only 25 percent of patients show electrocardiographic abnormalities, and no consistent pattern has been demonstrated.<sup>1</sup>

### *Management*

The treatment of this patient was focused on relief of symptoms. Because the origin of her pneumomediastinum was initially unclear, the patient was placed on intravenous fluids exclusively for the first 12 hours. In retrospect, this approach appeared unnecessary as no suspected esophageal perforation is thought to cause the Hamman syndrome. Treatment with oxygen has been reported to result in a decrease in the patient's symptoms and could increase the speed of resorption of the mediastinal air.<sup>4</sup> More aggressive intervention would be indicated when severe pneumothorax or pneumopericardium is detected. This situation is rarely encountered, however.

We wish to remind family physicians that while this condition is rare, the Hamman syndrome should be suspected in pregnant patients complaining of chest pain, shortness of breath, or dysphagia or who have subcutaneous emphysema immediately after delivery. While the Hamman syndrome is clinically impressive and most certainly unusual, its clinical course is almost always self-limited requiring little or no intervention and only supportive care.

## References

1. Sparacino ML, MacKay PE. Subcutaneous emphysema and pneumomediastinum complicating labor in a twin pregnancy. *J Am Osteopath Assoc* 1989; 89:185-7.
2. Reeder SR. Subcutaneous emphysema, pneumomediastinum, and pneumothorax in labor and delivery. *Am J Obstet Gynecol* 1986; 154:487-9.
3. Aisner M, Franco JE. Mediastinal emphysema. *N Engl J Med* 1949; 241:818-25.
4. Jensen H, Asmussen I, Eliassen B. Labor complicated by spontaneous emphysema. *Acta Obstet Gynecol Scand* 1987; 66:567-8.