

# An Approach To Difficult Management Problems In Otitis Media In Children

James D. Legler, M.D.

**Abstract: Background:** Otitis media is one of the most common pediatric diseases encountered by family physicians. While isolated, acute episodes pose little clinical difficulty, recurrent infections and persistent middle ear effusions can be perplexing problems.

**Methods:** This review presents a clinical approach to the management of recurrent and persistent middle ear disease.

**Results and Conclusions:** Recurrent infections can be treated with a trial of daily prophylactic antibiotics to decrease the rate of recurrence. Should infections continue to recur despite the daily prophylaxis, polyethylene tube placement is warranted to drain surgically the middle ear effusions that give rise to the recurrent infections. Acute episodes of otitis media are commonly followed by prolonged, asymptomatic periods of middle ear effusion. Patients with this disease have decreased hearing leading to potential deficits in their speech and academic development. If such effusions do not spontaneously resolve within 2 months, repeated courses of antibiotics with the possible addition of a course of oral steroids are warranted to speed resolution of the effusion before proceeding to placement of polyethylene tubes. (J Am Board Fam Pract 1991; 4:331-9.)

Otitis media is one of the most common diseases encountered in primary care.<sup>1</sup> Furthermore, the frequency of medical visits and surgery for this disease continue to increase.<sup>2</sup> While isolated, acute episodes pose little therapeutic difficulty, recurrent or persistent infections give rise to a multitude of controversial questions. What is the proper role of the new, potent, but more expensive antibiotics? When and how should one use daily antibiotic prophylaxis? When is the placement of polyethylene tubes warranted? Because little uniformity of opinion exists on these topics, no universally accepted guidelines can be offered to the family physician. By applying what is known about the causes and natural history of middle ear disease, however, a schematic framework can be devised upon which the family physician can begin to address these issues and develop a therapeutic plan for an individual patient.

## Basic Approach

The basic approach to middle ear disease begins with two important questions. First, what is in the

child's middle ear cavity at the time of examination? Second, at what stage is the child's condition in the natural history of middle ear disease? By answering these two questions, an appropriate plan for managing the patient's middle ear disease can be derived.

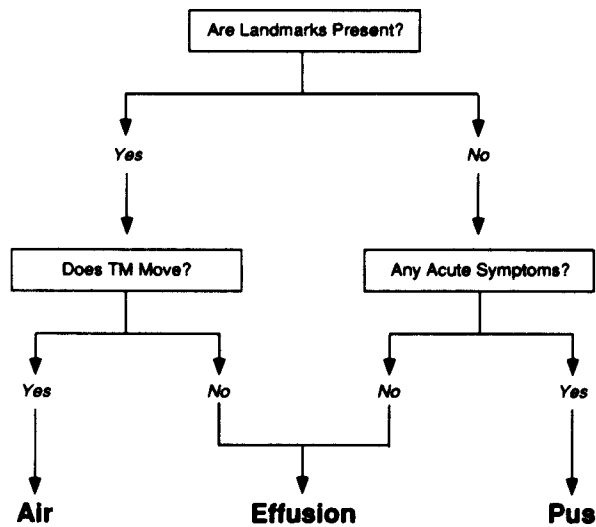
## What Is in the Middle Ear?

Three substances can exist within the middle ear cavity: air, pus, or a noninflamed effusion. The most precise way to distinguish among these three substances is to perform a tympanocentesis on all patients with suspected middle ear disease. A Gram stain and culture of any fluid obtained would then provide an accurate description of the contents of the middle ear cavity. Although this approach is precise, it is hardly practical for most patients. Thus, we are left with indirect methods based upon physical examination and patient history to diagnose middle ear disease. One such method is presented in Figure 1.

Physicians are accustomed to inspecting the tympanic membrane directly to diagnose middle ear diseases. Accordingly, as outlined in Figure 1, physical examination of the tympanic membrane forms the basis of the attempt to determine clinically what is present in the middle ear cavity. Unless scarred from prior infections, the inferior portion of the normal tympanic membrane is

Submitted, revised, 30 April 1991.

From the Departments of Family Practice and Pediatrics, University of Texas Health Science Center, San Antonio, TX. Address reprint requests to James D. Legler, M.D., Department of Family Practice, UTHSCSA, 7703 Floyd Curl Drive, San Antonio, TX 78284-7795.



**Figure 1. A clinical approach to middle ear diagnosis.**

translucent, and the handle of the malleus is clearly identifiable as a bony ridge upon its surface (bony landmark). Unfortunately, clear effusions within the middle ear cavity can also retain the translucency of the membrane's surface, resulting in a tympanic membrane that appears to be perfectly normal. When an examination reveals the normal handle of the malleus upon the tympanic membrane, an assessment of membrane mobility is required to differentiate between those middle ear cavities that contain air and those that contain clear effusions. Normal mobility implies the presence of air in the middle ear cavity. Clear effusions in the middle ear cavity will cause the tympanic membrane to be immobile despite its apparent normalcy on inspection.

Tympanic membrane mobility is most commonly assessed using a pneumatic bulb attached to the otoscope head. The degree of tympanic membrane motion is observed directly as air is pumped back and forth in the external canal. While simple, this procedure can be awkward to perform in a restless child, and subjective interpretation is often required. More definitive quantification of tympanic membrane mobility can be obtained with a tympanometer. This instrument contains a probe that fits into the patient's external auditory canal in much the same way as does the head of an otoscope. The probe emits pressure impulses into the external canal and then measures the mobility of the tympanic membrane in response to these impulses. Earlier versions of these devices required relatively large, stationary

measuring instruments attached to the probe by means of a connecting tube. Fortunately, more recent versions of this instrument combine the probe and measuring instrument into a single hand-held unit, are no more difficult to use than an otoscope, and can give simple, accurate, reliable assessments of tympanic membrane mobility. The hand-held tympanometer should take its place beside the otoscope and stethoscope as basic instruments found in all primary care offices in which pediatric middle ear disease is being managed.

Both pus and effusion within the middle ear cavity can dull the surface of the tympanic membrane and cause its normally translucent surface to become indistinguishable from the handle of the malleus (loss of bony landmarks). Unless the tympanic membrane is scarred from prior infections, failure to identify the handle of the malleus upon the membrane implies that either pus or effusion is present. Differentiation between these two disease processes is based on the patient's immediate clinical history. Does the patient have acute symptoms of middle ear disease? Acute symptoms are chiefly respiratory with a history of recent onset of ear pain being especially indicative of middle ear infection. Chronic respiratory symptoms in allergic children are not of concern unless there has been a recent change in the symptom pattern. Younger children can exhibit nonspecific symptoms, such as recent fussiness, irritability, or ear pulling. Fever will not be present in all cases. Thus, a tympanic membrane on which no landmarks are seen in a child who has a history of acute symptoms suggests that pus is present in the middle ear cavity. On the other hand, a tympanic membrane with no landmarks in a child who is otherwise well and who has no acute symptoms most likely indicates the presence of a middle ear effusion.

Other common, but less useful, physical findings are also used to determine what is present in a patient's middle ear. Acute infection can impart a red color to the tympanic membrane; however, so can a crying child. Although bubbles and air-fluid levels behind the tympanic membrane imply the presence of effusions, they are often difficult to identify with hand-held otoscopes. Tympanic membrane bulging or retraction can be helpful if it can be seen in the extreme; however, the assessment of intermediate degrees of these findings is

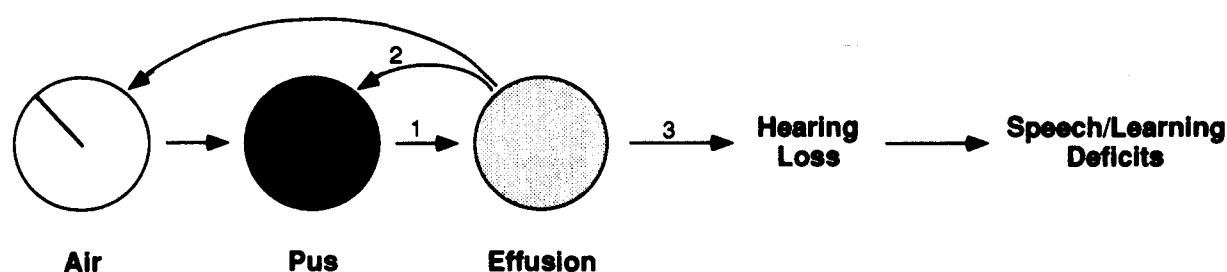


Figure 2. Natural history of middle ear disease.

somewhat subjective. The presence or absence of landmarks and the degree of tympanic membrane mobility therefore form the foundation upon which family physicians can determine what is present in the middle ear.

Much of the terminology surrounding middle ear disease is an attempt to describe what is present in the middle ear cavity. Acute otitis media implies that pus is present. Both serous otitis media and otitis media with effusion imply the presence of an effusion. Because of their common use and acceptance, this review retains the terms acute otitis media (AOM) and otitis media with effusion (OME) as described. It is important to emphasize, however, that these terms are useful only to the extent that they describe what is present in the middle ear cavity at any one time.

#### *At What Stage Is the Child's Condition in the Natural History of Middle Ear Disease?*

The identification of the substance present in the middle ear cavity is important because it provides a starting point from which the physician can determine the child's stage within the natural history of middle ear disease. This knowledge then forms the basis for the therapeutic plan to be used.

A schematic summary of the natural history of middle ear disease is shown in Figure 2. The ability of the middle ear cavity to fill with pus and become acutely infected is well known; however, the tendency of this pus to evolve into a thick, noninflamed effusion that may last for months is less well appreciated. Several investigators have studied the natural history of effusions following AOM.<sup>3,4</sup> Although they found that many of the post-AOM effusions resolved within 1 month, a

substantial number persisted up to 3 months, and rare cases were not resolved after even longer periods of observation. Thus, episodes of pus in the middle ear cavity commonly evolve into relatively prolonged periods of noninflamed middle ear effusions (Figure 2, Arrow 1) before reverting back to the normal, air-filled middle ear state.

In addition to the effusion stage, two other clinically important pathways can occur. In the first, the child can experience a recurrence of AOM within weeks to months after successful treatment of the preceding acute infection. In some cases, the effusion stage of the preceding infection resolves, and an air-filled stage exists before becoming reinfected. In other cases (Figure 2, Arrow 2), the effusion can become reinfected, and the middle ear contents revert to the pus stage before returning to the air-filled state. In such cases, warm, moist, prolonged post-AOM middle ear effusions provide excellent culture media for bacterial growth, thus causing recurrent acute infections. Children with persistent effusions are often caught in a vicious cycle in which pus resolves to effusion after acute therapy only to be followed by later reinfection of the effusion before it has a chance to return to the normal, air-filled stage.

The second pathway (Figure 2, Arrow 3) is found in those rare patients who do not spontaneously resolve their effusions within 1 to 3 months after an episode of AOM. While such children have no symptoms and appear well, this condition is of concern because their tympanic membranes are immobile, leading to potential hearing impairment.<sup>5</sup> Although controversial, some theorize that such impaired hearing can lead to speech and learning difficulties.<sup>6,7</sup>

**Table 1. Approach to Nonresponsive Acute Otitis Media.**

Steps	Notes
1. Rule out associated severe disease	Usually can be done clinically, and rarely requires invasive workup
2. Inquire about compliance with prescribed medication	
3. Change to a broader spectrum antibiotic	
a. Amoxicillin	First-line therapy
b. Sulfa-containing antibiotics	Beware of Stevens-Johnson reaction
-Trimethoprim-sulfamethoxazole (Septra™, Bactrim™)	
-Erythromycin-sulfisoxazole (Pediazole™)	
c. Amoxicillin clavulanate (Augmentin™)	All are expensive and have gastrointestinal side effects
Cefaclor (Ceclor™)	
Cefuroxime axetil (Oral Zinacef™)	
Cefixime (Suprax™)	
4. Refer to otolaryngologist for surgical drainage	Therapeutic and provides definitive diagnosis of middle ear pathogen (culture and stain for fungus as well as bacteria)

### Clinical Problems

The above ideas are applied to the four clinical situations most commonly encountered in children with complicated otitis media.

#### *Clinically Unresponsive Acute Otitis Media*

Children with unresponsive AOM initially have loss of tympanic membrane landmarks in association with the recent onset of new symptoms. They are assessed as having pus within their middle ear cavity and are placed on antibiotics. They then return within 2 to 3 days with no change in their clinical status. Their continued symptoms and continued loss of landmarks indicate that pus is still present in their middle ear cavity.

While antimicrobial resistance to the prescribed antibiotic is commonly suspected in these settings, only a minority of organisms obtained by tympanocentesis from such patients have been found to be resistant to the antibiotic initially chosen.<sup>8</sup> Other factors, such as patient noncompliance with therapy and concurrent viral infection, probably are instrumental in the patient's failure to undergo clinical improvement.<sup>9</sup> Though rare, associated infections (especially meningitis) must also be excluded as diagnostic possibilities.

Based upon these considerations, a suggested approach to clinically unresponsive AOM is presented in Table 1. In all cases, the possibility of a life-threatening disease must be ruled out. In a majority of these cases, this can be done clinically. Rarely, laboratory evaluations, including lumbar puncture, are required. After serious disease has been ruled out, the child's guardians should be

questioned closely about their compliance with the therapy previously prescribed. In the event that compliance has been good, the antibiotic should be changed to cover possible microbial resistance to the initial antibiotic.

Table 1 provides a list of antibiotics suggested for cases of acute otitis media that are clinically unresponsive to initial therapy. Currently, the incidence of  $\beta$ -lactamase-producing *Haemophilus influenzae* and *Moraxella catarrhalis* is still sufficiently low to warrant amoxicillin as first-line therapy for AOM.<sup>10</sup> Should microbial resistance to this antibiotic be suspected, a second-line, sulfa-containing antibiotic is recommended.<sup>8</sup> Should the patient continue without clinical improvement, and serious disease or noncompliance has been eliminated as a diagnostic possibility, a third-line antibiotic is warranted. Finally, should the patient demonstrate clinical resistance to even third-line medical therapy, immediate referral to an otolaryngologist is required for surgical drainage of the infected middle ear cavity both as a therapeutic maneuver and to obtain material for specific bacteriologic diagnosis.

#### *Frequently Recurrent Acute Otitis Media*

The second clinical problem occurs in those children who have frequent recurrences of AOM. These children initially have abnormal tympanic membranes in association with acute symptoms. Pus is thought to be present in the middle ear, and antibiotic therapy is started. Unlike the children with resistant AOM, however, these children improve clinically and their symptoms resolve, implying that the acute infection has also resolved.



Within weeks to months, however, the child again becomes acutely symptomatic with abnormal tympanic membranes, suggesting that the infection in the middle ear has returned to a pus-producing stage.

Although it is commonly presumed that such cases represent resistance to the initial antibiotic used, investigators have reported that the majority of cases that recurred within 1 week to 1 month after termination of the initial antibiotic were caused by organisms sensitive to the original antibiotic.<sup>11,12</sup> Thus, isolated, 10-day courses of the broader-spectrum antibiotics will likely add little to the management of these children. Two therapeutic maneuvers, however, are helpful in this clinical situation: daily antibiotic prophylaxis and placement of polyethylene tubes.

Daily antibiotic prophylaxis has been shown to decrease the rate of reinfection in children with recurrent AOM.<sup>13-15</sup> The diagnostic criteria and antibiotic regimens used in some of these studies are summarized in Table 2. As no uniform opinion exists regarding the proper time to instigate prophylaxis or which antibiotic regimen to use, practitioners are free to choose among the approaches outlined.

While daily antibiotic prophylaxis is beneficial in many cases, some acute infections do recur despite this therapeutic approach. In such cases, the only currently recommended course of action

is the placement of polyethylene tubes. The tubes keep the middle ear free of fluid during the time that they are in place, thereby eliminating the chronic effusion that gives rise to many of these recurrent infections.

### **Persistent Middle Ear Effusions**

This disease process occurs in those children who do not spontaneously clear their effusions after an episode of acute purulent otitis media. Clinically, the children are well and without symptoms; however, their tympanic membranes are either dulled with loss of landmarks, or the landmarks are seen but the tympanic membrane has lost mobility. The effusion persists and hearing decreases, leading to possible speech and learning defects—all in children who appear outwardly well and who may even have normal tympanic membranes on gross inspection. Thus, persistent middle ear effusions are worrisome because they are unheralded by clinical symptoms that bring these children to medical attention.

Whereas the majority of middle ear effusions resolve spontaneously within 3 months, several forms of therapy have been studied to hasten the resolution of these effusions and decrease their potential impact upon the child's hearing and learning. Although popular in the past, decongestants and antihistamines have now been shown to be of no benefit in aiding the resolution of

**Table 2. Approach to Frequently Recurrent Acute Otitis Media (AOM).**

Study	When Started	Regimen Used
1. Begin daily antibiotic prophylaxis		
Liston, et al. <sup>13</sup>	At least 3 AOM episodes occurring at a frequency of at least once every 2 months (6 months–5 years)	Sulfisoxazole, 75 mg/kd/d bid for 3 months
Perrin, et al. <sup>14</sup>	3 or more AOM episodes within the last 18 months or a total of 5 in whole life (11 months–8 years)	Sulfisoxazole, 1000 mg/d bid for 3 months
Lampe and Weir <sup>15</sup>	4 or more AOM episodes within the last 12 months or 3 episodes within the last 6 months (birth–6 years)	Erythromycin, 20 mg/kd/d bid for 2–3 months (found to be more effective than sulfisoxazole, 1000 mg/d bid for 2–3 months)
Marchant <sup>16</sup>	3 or more AOM episodes within the last 18 months	Amoxicillin, 20 mg/kg/d bid or sulfisoxazole, 80 mg/kd/ d bid during the winter and spring months
Bluestone <sup>10</sup>	3 or more AOM episodes in 6 months or 4–5 episodes in 12 months	Amoxicillin, 20 mg/kg/d qd or sulfisoxazole, 50 mg/kg/ d qd during the “respiratory season”
2. Refer to otolaryngologist for possible polyethylene tube placement if acute infections recur while on daily antibiotic therapy.		

**Table 3. Approach to Persistent Middle Ear Effusions in an Asymptomatic Child.**

Time Interval After Episode of Acute Otitis Media	Approach
Effusion persistent at 1-month follow-up	Observe Recheck in 1 month
Effusion persistent at 2-month follow-up	10- to 14-day trial of amoxicillin (or sulfa-containing antibiotic if allergic to penicillin compounds)
Effusion persistent after first antibiotic trial	14- to 30-day trial of step 3c antibiotic (as defined in Table 1) Consider concurrent 7-day course of oral prednisone
Effusion persistent after second antibiotic trial	Consider otolaryngology referral for possible polyethylene tube placement Tube placement most imperative with associated hearing or speech delay May consider continued observation if hearing and speech are normal

persistent effusions.<sup>17</sup> On the other hand, antibiotics have been found to have at least a temporary beneficial effect,<sup>18,19</sup> and broader spectrum antibiotics may be even more useful.<sup>20</sup> Recently, the addition of a short-term course of oral steroids to antibiotic therapy was beneficial in hastening the resolution of persistent effusions and is discussed below.

Table 3 offers a clinical approach to persistent OME. After an episode of AOM, the child is seen monthly until resolution of the resultant effusion is documented by the return of tympanic membrane mobility. Should this resolution not occur by the second monthly visit, a 10- to 14-day trial of amoxicillin can be prescribed. If the effusion persists despite the amoxicillin therapy, a 10- to 30-day trial of a broader spectrum antibiotic can then be undertaken as final medical therapy prior to consideration of polyethylene tube placement. Use of polyethylene tubes is most imperative if the child has deficits in hearing or speech development that are associated with the persistent effusion. On the other hand, if the child's hearing and speech development are normal, some authors would recommend only continued observation for spontaneous resolution of the effusion.<sup>21</sup>

#### ***Incidentally Noted Effusions***

While this review has focused on middle ear disease caused by AOM, middle ear effusions can occur in children at other times as well. Any process that affects the eustachian tube, such as upper respiratory tract infections and respiratory tract allergy, can result in a buildup of effusion within the middle ear. Such effusions commonly are found in children during routine well-child visits.<sup>4</sup> Casselbrant and co-workers<sup>22</sup> looked at the natural history of these effusions in children and found that approxi-

mately one-half of all children observed for 1 year experienced an episode of effusion. Similar to effusions following episodes of AOM, these effusions were largely self-limited, resolving within 3 months, with rare examples lasting up to 6 months. These effusions, when found, warrant the close monthly management outlined in Table 3.

#### **Surgical Issues**

Although current approaches to the therapy of middle ear disease in children emphasize the role of polyethylene tubes in those cases that do not respond to medical management, family physicians should be aware that controversy exists about the use of these tubes.<sup>23</sup> Much of the controversy has centered on the fear that placement of polyethylene tubes will lead to tympanic membrane damage and associated iatrogenic hearing loss. Indeed, infrequent instances of severe sequelae, such as persistent tympanic membrane perforations and cholesteatomas, have been documented.<sup>24</sup> Postoperative hearing loss has also been reported in a certain percentage of those children for whom multiple polyethylene tube placements were required.<sup>25</sup> On the other hand, the most common surgical sequela, tympanosclerosis, has only rarely been associated with significant hearing loss following single polyethylene tube insertions.<sup>26</sup>

In addition to the fears about possible surgical side effects, some physicians doubt the benefits to be gained by polyethylene tube use. Although polyethylene tube placement does result in normalization of hearing,<sup>27</sup> this effect appears to be transient, and little difference in hearing has been found between children with surgically treated and untreated ears after as little as 3 to 6 months of follow-up.<sup>28-30</sup> From a strict audiologic standpoint, therefore, polyethylene tube placement ap-

pears to gain 3 to 6 months of improved hearing before the child's hearing improves on its own. Whether this transient period of improved hearing necessarily results in enhanced long-term speech and intellectual development remains to be determined.

Clearly, the role of polyethylene tubes in the treatment of middle ear disease has yet to be elucidated fully. Single tube insertions appear to be safe in most cases and result in immediate benefits, but long-term benefits are uncertain. It would seem judicious to consider surgical therapy only after time and maximal medical therapy have failed to ameliorate the patient's middle ear disease. In particular, those children who have speech and learning deficits associated with their middle ear disease would be candidates for surgical therapy after all other attempts fail. Further study is needed to define better the role of polyethylene tube placement in children with middle ear disease.

### Future Trends

The preceding approaches to the management of complicated otitis media are based upon current knowledge of the causes and natural history of middle ear disease. Conflicting ideas in the contemporary otitis literature can lead to future alterations in these present recommendations.

The usual treatment of isolated, acute cases of otitis media in the United States consists of a 7- to 10-day course of oral antibiotics. This therapy is based upon bacteriologic studies of the middle ear fluid obtained from children with AOM in which a bacterial pathogen was found in up to 89 percent of cases.<sup>10</sup> On the other hand, European researchers have reported that these infections have a high rate of spontaneous resolution and have recommended antibiotic therapy only in those cases that do not clinically resolve within 3 to 4 days of onset.<sup>31,32</sup> Using this protocol, more than 90 percent of the children studied were managed successfully without antibiotics. No increase in the rate of suppurative complications, such as meningitis or mastoiditis, was noted. Nevertheless, until further data are available, antibiotic therapy should remain the standard for AOM in the United States. If these experimental findings are replicated in the US population, however, we may need to rethink the entire role of antibiotics in the management of middle ear disease.

It is the recommendation of this review to wait 2 months for persistent effusions to clear before introducing antibiotic trials in the presurgical management of OME. Another medical treatment that has been studied before pursuing surgical intervention is the short-term administration of oral steroids. Prospective studies of the use of steroids alone to treat persistent OME have not found such therapy to be beneficial.<sup>33-35</sup> When used in combination with antibiotic therapy, however, oral steroids taken for 7 to 14 days led to increases in the rate of OME resolution that were greater than the increases achieved with antibiotic use alone.<sup>36-38</sup> The steroid-antibiotic combination had no increase in side effects and resulted in low OME recurrence rates. Adding steroids to antibiotic management can be considered, therefore, for any child in whom one wishes to try all possible medical therapies before proceeding to surgery, especially if an allergic diathesis is thought to underlie the persistent OME. Should future research continue to substantiate the value of the steroid-antibiotic combination in the medical treatment of persistent OME, short-term oral steroid therapy may become a routine part of the management of all patients with OME.

At present, most children undergoing surgery for persistent OME receive placement of polyethylene tubes. Since the introduction of these tubes in the 1950s, however, numerous other surgical approaches to the treatment of persistent effusions have been studied, including varying combinations of myringotomy without polyethylene tube placement, tonsillectomy with adenoidectomy, and adenoidectomy alone.<sup>39-42</sup> From this body of data, it should be noted that polyethylene tube placement has never been shown to be consistently superior to the other surgical procedures studied. In fact, the most recent study in this series found myringotomy plus adenoidectomy to be superior to polyethylene tube placement in terms of increased postoperative auditory acuity and reduced need for repeat surgery.<sup>42</sup> As in all surgical fields, the best approach is probably the one with which the particular surgical consultant is most familiar and comfortable. It is important to know, however, that surgical techniques other than insertion of polyethylene tubes are acceptable therapy at this time and may replace polyethylene tube placement as more experience is acquired.

Much of the discussion in this review has been based upon the assumption that the hearing loss associated with persistent middle ear effusions is detrimental to the patient and can lead to subsequent speech and learning difficulties. The extent to which these sequelae actually occur is a subject of controversy, and ample data are available to support both sides of the issue.<sup>6,7</sup> Should future research not substantiate an association between persistent OME and speech and learning difficulties, persistent OME may then be viewed as a benign, self-limiting condition that does not warrant the medical therapies and surgical procedures currently applied in its management. Until further research resolves this issue, however, family physicians must expect that some children with middle ear effusions can suffer significant speech and learning deficits from the hearing loss associated with those effusions. Thus, close monthly monitoring is warranted.

## Summary

### *Importance of Patient's History*

Whereas physical examination of the tympanic membrane is important to determine a course of action for patients with middle ear disease, inspection alone is insufficient evidence on which to base therapy. Knowledge of the patient's history of middle ear pathology is equally important. A patient with loss of landmarks but no symptoms 1 month after an episode of AOM has an effusion and requires nothing more than observation. On the other hand, a patient whose tympanic membrane is normal with good mobility may warrant the instigation of antibiotic prophylaxis if there have been recurrent infections in the past year.

### *Natural History of Otitis Media with Effusion*

OME commonly follows AOM and other processes that interfere with the function of the eustachian tube. Middle ear effusions are frequently found during childhood. Fortunately, the majority of these effusions will resolve spontaneously. Close observation is warranted, however, to diagnose those cases that persist, leading to potential hearing, speech, and learning deficits.

### *Use of Broader Spectrum Antibiotics*

Only a minority of cases of middle ear disease are due to microbes bacteriologically resistant to first-line antibiotics. The broader spectrum anti-

biotics are warranted only in those cases of AOM that do not respond clinically to first-line antibiotics. They can also be used in a last-ditch effort to resolve persistent middle ear effusions medically before recommending polyethylene tube placement.

### *Indications for Polyethylene Tube Placement*

Currently, there are two indications for polyethylene tube placement: (1) frequently recurrent AOM that is not responsive to prophylactic antibiotics, and (2) OME that does not resolve within 3 months of observation despite repeated antibiotic treatments. Because the long-term benefits of polyethylene tubes are uncertain, these clinical indications for polyethylene tube placement may change as we gain greater understanding of middle ear disease.

---

My thanks to Dr. Michael Foulds and Dr. Anita Bowes for their critical review of this manuscript.

## References

1. Kirkwood CR, Clure HR, Brodsky R, Gould GH, Knaak R, Metcalf M, et al. The diagnostic content of family practice: 50 most common diagnoses recorded in the WAMI community practices. *J Fam Pract* 1982; 15:485-92.
2. Croteau N, Hai V, Pless IB, Infante-Rivard C. Trends in medical visits and surgery for otitis media among children. *Am J Dis Child* 1990; 144:535-8.
3. Shurin PA, Pelton SI, Donner A, Klein JO. Persistence of middle-ear effusion after acute otitis media in children. *N Engl J Med* 1979; 300:1121-3.
4. Marchant CD, Shurin PA, Turczyk VA, Wasikowski DE, Tutihasi MA, Kinney SE. Course and outcome of otitis media in early infancy: a prospective study. *J Pediatr* 1984; 104:826-31.
5. Bluestone CD, Beery QC, Paradise JL. Audiometry and tympanometry in relation to middle ear effusions in children. *Laryngoscope* 1973; 83:594-604.
6. Teele DW, Klein JO, Rosner BA. Otitis media with effusion during the first three years of life and development of speech and language. *Pediatrics* 1984; 74:282-7.
7. Wright PF, Sell SH, McConnell KB, Sitton AB, Thompson J, Vaughn WK, et al. Impact of recurrent otitis media on middle ear function, hearing, and language. *J Pediatr* 1988; 113:581-7.
8. Teele DW, Pelton SI, Klein JO. Bacteriology of acute otitis media unresponsive to initial antimicrobial therapy. *J Pediatr* 1981; 98:537-9.
9. Arola M, Ziegler T, Ruuskanen O. Respiratory virus infection as a cause of prolonged symptoms in acute otitis media. *J Pediatr* 1990; 116:697-701.



10. Bluestone CD. Modern management of otitis media. *Pediatr Clin North Am* 1989; 36:1371-87.
11. Harrison CJ, Marks MI, Welch DF. Microbiology of recently treated acute otitis media compared with previously untreated acute otitis media. *Pediatr Infect Dis J* 1985; 4:641-6.
12. Carlin SA, Marchant CD, Shurin PA, Johnson CE, Murdell-Panek D, Barenkamp SJ. Early recurrences of otitis media: reinfection or relapse? *J Pediatr* 1987; 110:20-5.
13. Liston TE, Foshee WS, Pierson WD. Sulfisoxazole chemoprophylaxis for frequent otitis media. *Pediatrics* 1983; 71:524-30.
14. Perrin JM, Charney E, MacWhinney JB Jr, McInerney TK, Miller RL, Nazarian LF. Sulfisoxazole as chemoprophylaxis for recurrent otitis media. A double-blind crossover study in pediatric practice. *N Engl J Med* 1974; 291:664-7.
15. Lampe RM, Weir MR. Erythromycin prophylaxis for recurrent otitis media. *Clin Pediatr* 1986; 25:510-5.
16. Marchant CD. Otitis media today. *Pediatr Consultant* 1990; 8:1-8.
17. Cantekin EI, Mandel EM, Bluestone CD, Rockette HE, Paradise JL, Stool SE, et al. Lack of efficacy of a decongestant-antihistamine combination for otitis media with effusion ("secretory" otitis media) in children. Results of a double-blind, randomized trial. *N Engl J Med* 1983; 308:297-301.
18. Mandel EM, Rockette HE, Bluestone CD, Paradise JL, Nozza RJ. Efficacy of amoxicillin with and without decongestant-antihistamine for otitis media with effusion in children. Results of a double-blind, randomized trial. *N Engl J Med* 1987; 316:432-7.
19. Thomsen J, Sederbert-Olsen J, Balle V, Vejlsgaard R, Stangerup SE, Bondesson G. Antibiotic treatment of children with secretory otitis media. A randomized, double-blind, placebo-controlled study. *Arch Otolaryngol Head Neck Surg* 1989; 115:447-51.
20. Chan KH, Manden EM, Rockette HE, Bluestone CD, Bass LW, Blatter MM, et al. A comparative study of amoxicillin-clavulanate and amoxicillin. Treatment of otitis media with effusion. *Arch Otolaryngol Head Neck Surg* 1988; 114:142-6.
21. Callahan CW Jr, Lazowitz S. Otitis media and language development. *Am Fam Physician* 1988; 37:186-90.
22. Casselbrant ML, Brostoff LM, Cantekin EI, Flaherty MR, Doyle WJ, Bluestone CD, et al. Otitis media with effusion in preschool children. *Laryngoscope* 1985; 95:428-36.
23. Paradise JL, Rogers KD. On otitis media, child development, and tympanostomy tubes: new answers or old questions? *Pediatrics* 1986; 77:88-92.
24. Bluestone C. Surgical management of otitis media with effusion: state of the art. In: Lim D, editor. *Recent advances in otitis media with effusion*. Philadelphia: BC Decker, 1984:293-8.
25. Pichichero ME, Berghash LR, Hengerer AS. Anatomic and audiologic sequelae after tympanostomy tube insertion or prolonged antibiotic therapy for otitis media. *Pediatr Infect Dis J* 1989; 8:780-7.
26. Tos M, Stangerup SE. Hearing loss in tympanosclerosis caused by grommets. *Arch Otolaryngol Head Neck Surg* 1989; 115:931-5.
27. Richards SH, Shaw JD, Kilby D, Campbell H. Grommets and glue ears: a clinical trial. *J Laryngol Otol* 1971; 85:17-22.
28. Kilby D, Richards SH, Hart G. Grommets and glue ears: two-year results. *J Laryngol Otol* 1972; 86:881-8.
29. Brown M, Richards S, Ambegaokar A. Grommets and glue ear: a five-year follow up of a controlled trial. *J Royal Soc Med* 1978; 71:353-6.
30. Lildholdt T. Unilateral grommet insertion and adenoidectomy in bilateral secretory otitis media: preliminary report on the results in 91 children. *Clin Otolaryngol* 1979; 4:87-93.
31. VanBuchem FV, Peeters MF, Van't Hof MA. Acute otitis media: a new treatment strategy. *Br Med J* 1985; 290:1033-7.
32. Bollag U, Bollag-Albrecht E. Otitis media in practice. A different approach to management. *Clin Pediatr* 1990; 29:244-5.
33. Macknin ML, Jones PK. Oral dexamethasone for treatment of persistent middle ear effusion. *Pediatrics* 1985; 75:329-35.
34. Niederman L, Walter-Buckholtz V, Jabalay T. A comparative trial of steroids vs. placebo for treatment of chronic otitis media with effusion. In: Lim D, editor. *Recent advances in otitis media with effusion*. Philadelphia: BC Decker, 1984: 273-5.
35. Giebink GS, Batalden PB, Le CT, Lassman FM, Buran DJ, Seltz AE. A controlled trial comparing three treatments for chronic otitis media with effusion. *Pediatr Infect Dis J* 1990; 9:33-40.
36. Persico M, Podoshin L, Fradis M. Otitis media with effusion: a steroid and antibiotic therapeutic trial before surgery. *Ann Otol Rhinol Laryngol* 1978; 87:191-6.
37. Berman S, Grose J, Zerbe GO. Medical management of chronic middle-ear effusion. Results of a clinical trial of prednisone combined with sulfamethoxazole and trimethoprim. *Am J Dis Child* 1987; 141:690-4.
38. Berman S, Grose K, Nuss R, Huber-Navin C, Roark R, Gabbard SA, et al. Management of chronic middle ear effusion with prednisone combined with trimethoprim-sulfamethoxazole. *Pediatr Infect Dis J* 1990; 9:533-8.
39. Leek J. Middle ear ventilation in conjunction with adenotonsillectomy. *Laryngoscope* 1979; 89: 1760-3.
40. Roydhouse N. Adenoidectomy for otitis with mucoid effusion. *Ann Otol Rhinol Laryngol Suppl* 1980; 89:312-5.
41. Maw AR, Herod F. Otoscopy, impedance, and audiometric findings in glue ear treated by adenoidectomy and tonsillectomy. *Lancet* 1986; 1:1399-402.
42. Gates GA, Avery CA, Prihoda TJ, Cooper JC Jr. Effectiveness of adenoidectomy and tympanostomy tubes in the treatment of chronic otitis media with effusion. *N Engl J Med* 1987; 317:1444-51.