

Collagenous Colitis As A Cause Of Chronic Diarrhea

Charles E. Henley, D.O.

Abstract: When the usual workup for chronic diarrhea fails to provide a diagnosis and the endoscopic findings are normal, alternative etiologies must be considered. This case of collagenous colitis represents such an alternative diagnosis. The patient is a 65-year-old woman who complained of abdominal cramps and watery diarrhea for an 8-month span. The key element to her diagnosis was subepithelial collagen deposits of the mucosa of the colon. Her symptoms were resolved with supportive care, diet, and diphenoxylate. Essential features and treatment of collagenous colitis are reviewed. (J Am Board Fam Pract 1991; 4:55-7.)

For most patients, the problem of diarrhea is a manifestation of an acute viral or bacterial infection and, although unpleasant, is usually short lived. When the diarrhea becomes chronic and debilitating, however, all causes must be explored. Amebiasis, giardiasis and other parasitic diseases, viral and pathogenic bacterial infections, inflammatory bowel disease, scleroderma, malabsorption syndromes, hepatitis, Addison disease, pancreatic insufficiency, hyperthyroidism, amyloidosis, lymphoma, and diseases that affect small bowel intracellular enzymes can produce chronic diarrhea.^{1,2} To this litany of gastrointestinal disorders, collagenous colitis also must be added.

This rare disease was unknown in the medical literature until 1976 when Lindstrom described a case of persistent watery diarrhea showing a band of collagen deposited in the subepithelial layers of the mucosa of the rectum and colon.^{1,3-5} These features—watery diarrhea and subepithelial collagen deposits—remain the essential criteria for diagnosis since this first case.⁶

Case Presentation

A 65-year-old woman had complaints of abdominal cramps and watery diarrhea on several occasions during an 8-month span. She took hydrochlorothiazide and propranolol (Inderal™) for hypertension and short courses of diphenoxylate (Lomotil™) to control her symptoms. Otherwise, she was in good health and quite active.

Her stools were copious and watery; she had moderate cramps, but no fever or bloody diar-

rrhea. Despite having 15 to 20 such stools per day, her appetite was good, and her general physical examination was normal.

During the course of her illness, she was treated empirically once with doxycycline and again with metronidazole (Flagyl™) for 10 days. Because of these antibiotics, she was evaluated for possible pseudomembranous colitis; a 60-cm flexible sigmoidoscopy demonstrated mild irritation but essentially normal mucosa.

Stool cultures for bacterial pathogens, such as *Yersinia*, *Campylobacter*, *Aeromonas*, *Clostridium difficile* and *C. difficile* toxin, and pathogenic *Escherichia coli*, were all negative. Numerous attempts to identify ova and parasites, including *Giardia*, were unsuccessful. Other pertinent negatives for an infectious etiology included a normal blood leukocyte count without eosinophilia, and there were no stool leukocytes. Her liver function and hepatitis profiles were also negative, and urine and serum amylase levels were normal. Initially, assays for fecal fat were negative, but later tests were positive.

The patient was treated with loperamide (Imodium™) to help control diarrhea, and the working diagnosis was malabsorption syndrome of unknown etiology. When her diarrhea worsened, she complained of fatigue and muscle cramping and showed signs of depression. Eventually, she was found to be slightly hypokalemic and hyponatremic and was hospitalized for a more extensive evaluation.

While she was an in-patient, watery diarrhea persisted even after more than 24 hours of fasting. Stool osmolality and electrolytes showed the diarrhea to be secretory in nature (stool Osm = 289, Na = 15, Cl = 26, K = 97). Studies for serum vasoactive intestinal peptide (VIP), serum histamine,

From the Department of Family Practice, Madigan Army Medical Center, Tacoma, Washington. Address reprint requests to Charles E. Henley, D.O., Department of Family Practice, Dewitt Army Community Hospital, Ft. Belvoir, VA 22060.

fasting serum gastrin, and 5-hydroxyindoleacetic acid (5-HIAA) were all normal,² as were an anti-nuclear antibody (ANA) profile and rheumatoid factor. A D-xylose test was performed to help establish an etiology of malabsorption, but this was normal; so were B-carotene levels (140 $\mu\text{g/dL}$ [2.6 $\mu\text{mol/L}$]; normal, 50–250 $\mu\text{g/dL}$ [0.9–4.6 $\mu\text{mol/L}$]), in spite of 3+ qualitative fecal fat on one 48-hour stool collection. Although she previously had a normal flexible sigmoidoscopy, endoscopy was repeated with biopsies at several sites in the sigmoid, descending and ascending portions of the colon. The pathology report described a continuous thickened band of subepithelial collagen in several of the biopsy specimens, and the diagnosis of collagenous colitis was made.

Discussion

Essential Features of Collagenous Colitis

Frequent watery stools are characteristic of collagenous colitis, which is thought to be secretory in nature because it produces large watery stool volumes, (greater than 1 liter per day), persists during fasting, and there is usually a minimal osmotic gap.^{1,2} In this case, the osmolarity gap was 65, which is more consistent with secretory than with osmotic diarrhea. The secretory quality of the diarrhea is thought to occur because the colonic crypts are spared from collagen deposition. The crypts are the sites for colonic secretion, but the impaired surface mucosa cannot reabsorb the fluid.² There is usually no fever or severe cramping, and there are few if any fecal leukocytes as might be expected with an infectious etiology.

Steatorrhea was present in this patient, which might lead one to think of a malabsorption syndrome, except that the standard tests for malabsorption, such as the D-xylose test and small bowel biopsy, were normal. Other indicators of fat malabsorption, such as a low serum calcium, albumin, and B-carotene level, were not found. This condition has been reported in other studies of collagenous colitis; one patient had 18 gms of fat per 24 hours.^{1,2,4,10} Steatorrhea is of questionable significance and is not a diagnostic feature of collagenous colitis.¹ Giardiello suggests, however, that abnormalities of bile salts and fatty acid malabsorption produce the steatorrhea seen in some patients and may also exacerbate the colonic secretion.² Table 1 lists the essential features of this syndrome.

Table 1. Essential Features of Collagenous Colitis.

Copious watery diarrhea
Large stool volumes
Diarrhea is secretory
Absence of blood or fecal leukocytes
Predominantly women aged 50–60 years
Possible association with hyperthyroidism and seronegative arthropathy
Normal appearance to colon mucosa
Presence of subepithelial collagen band
Absence of marked inflammation or crypt abscesses

The key element to the diagnosis of this disease is finding the thickened subepithelial collagen layer in colon biopsies, along with lymphocytes, plasma cells, and eosinophils in the lamina propria.^{1–4,6} These features are readily seen in Figure 1.

Along with these findings, one could include as supportive evidence for the diagnosis, a normal-appearing mucosa on endoscopic examination and pertinent negatives, such as the absence of gastrointestinal pathogens.

Differential Diagnosis

The collagenous thickening of the subepithelia layer has not been described in other diseases of the colon, such as ulcerative colitis, Crohn disease, ischemic colitis, infectious colitis, pseudomeibranous enterocolitis, or collagen disorders, such as amyloidosis. Microscopically, the absence of crypt abscesses especially differentiates collagen colitis from ulcerative colitis, which causes an intraglandular lesion. Moreover, the lesion in ischemic or radiation colitis is diffuse fibrosis of

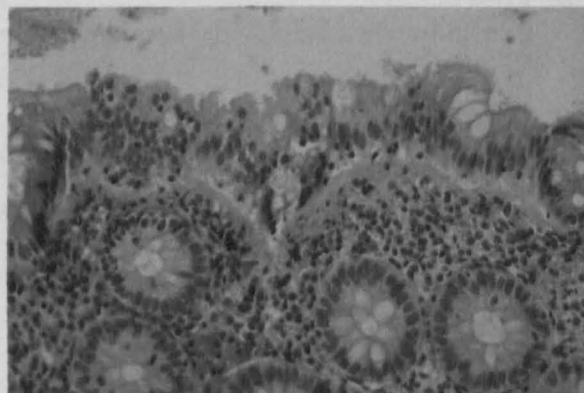


Figure 1. Photomicrograph of biopsy specimen showing thickened collagen band and cellular infiltrates typical of collagenous colitis.

the lamina propria, not limited to the subepithelial zone. In amyloidosis, the basement membranes of surface epithelium and the glands show the collagen; in scleroderma or systemic sclerosis, the fibrous thickening occurs along all basement membranes including the glandular crypts.⁶ In infectious colitis, one sees the inflammatory infiltrate diffusely throughout the lamina propria, not limited to the subepithelial superficial lamina propria as in collagenous colitis.

Another form of idiopathic colonic inflammation is lymphocytic or microscopic colitis. It has striking similarities to collagenous colitis because it also usually affects middle-aged and elderly women, causes chronic watery diarrhea, and has normal endoscopic findings. Microscopically, it shows inflammation of the lamina propria and surface epithelium and may, in fact, be the same disease as collagenous colitis.^{4,9}

In this case, there was no correlation with vasoactive intestinal peptides, 5-hydroxyindolacetic acid or other tests suggesting a hormonal etiology.⁶ Other studies have found the same; several patients also have had hypothyroidism, which suggests an autoimmune link.

Although the etiology of collagenous colitis remains unknown, the literature suggests its association with other conditions. The original article by Lindstrom proposed that immune complexes may be involved, but this was never proved. Teglbjaerg and others were able to show increased levels of prostoglandin E₂ in jejunal aspirates,⁷ and other cases occurred in patients with severe sero-negative, nondestructive arthropathy.^{1,3,8} One patient's arthritis improved along with the symptoms of collagenous colitis after sulfasalazine treatment.³ Other authors have noted the similarity between the histopathology of collagenous colitis and celiac disease.⁴

Treatment for collagenous colitis is mainly supportive; spontaneous remission has occurred in some patients.¹ Our patient's symptoms resolved with supportive care, diet, and diphenoxylate. Although the rate of recurrence has not been established, she has remained symptom free for more than 6 months except for occasional minor episodes of diarrhea.

The results of therapy can be unpredictable, but good results have been achieved with sulfasalazine, 2–3 gms/day, or systemic steroids.³

Prednisone, sulfasalazine, or a combination of both seem to provide the best return of normal bowel function. Other medications have been tried, such as quinacrine, metronidazole, and cholestyramine with varying clinical and histological responses. Therapy in some cases can last 3 to 12 months; some physicians advocate prescribing sulfasalazine first, reserving prednisone for refractory patients,⁴ but others use prednisone as a first-line drug in patients with severe diarrhea and weight loss, because the initial inflammatory reaction may be the trigger for collagen deposition.¹

Because of the preponderance of direct and indirect evidence, most authors believe that collagenous colitis is an inflammatory disorder, possibly autoimmune.^{2,6} Future studies of this rare disorder will no doubt be directed toward a better understanding of its etiology as well as pathogenesis.

References

1. Wang K, Perrault J, Carpenter HA, Schroeder KW, Tremaine WJ. Collagenous colitis: a clinico pathologic correlation. *Mayo Clin Proc* 1987; 62:665-71.
2. Giardiello FM, Bayless TM, Jessurun J, Hamilton SR, Yardley JH. Collagenous colitis: physiologic and histopathologic studies in seven patients. *Ann Intern Med* 1987; 106:46-9.
3. Wengrower D, Pollack A, Okon E, Stanikowicz R. Collagenous colitis and rheumatoid arthritis with response to sulfasalazine. A case report and review of the literature. *J Clin Gastroenterol* 1987; 9:456-60.
4. Jessurun J, Yardley JH, Giardiello FM, Hamilton SR, Bayless TM. Chronic colitis with thickening of the subepithelial collagen layer (collagenous colitis): histopathologic findings in 15 patients. *Hum Pathol* 1987; 18:839-48.
5. Lindstrom CG. Collagenous colitis with watery diarrhea—a new entity. *Pathol Eur* 1976; 11:87-9.
6. Rams H, Rogers AI, Ghandur-Mnaymneh L. Collagenous colitis. *Ann Intern Med* 1987; 106:108-13.
7. Teglbjaerg PS, Thaysen EH. Collagenous colitis: an ultrastructural study of a case. *Gastroenterology* 1982; 82:561-3.
8. Erlendsson J, Fenger C, Meinicke J. Arthritis and collagenous colitis. Report of a case with concomitant chronic polyarthritis and collagenous colitis. *Scand J Rheumatol* 1983; 12:93-5.
9. Salt WB 2nd, Llana PP. Collagenous colitis: a cause of chronic diarrhea diagnosed only by biopsy of normal appearing colonic mucosa. *Gastrointest Endosc* 1986; 32:421-3.
10. Danzi JT, McDonald TJ, King J. Collagenous colitis. *Am J Gastroenterol* 1988; 83:83-5.