

Penetration Of The Pericardium By A Gastric Ulcer – Survival After Pericardiocentesis

Mary N. Hall, M.D., and John M. Little, Jr., M.D.

Abstract: Elderly patients often have unusual manifestations of common illnesses. We describe a geriatric patient having a pneumopericardium from pericardial penetration by a gastric ulcer. Benign gastric ulceration causing perforation of the pericardium or other cardiac structures was recognized as early as 1854; however, until 1964, the condition was invariably fatal. Our patient survived the episode after early pericardiocentesis and medical treatment. Aspects of this uncommon clinical entity and a brief review of the literature are described. (J Am Board Fam Pract 1990; 3:289-91.)

Pneumopericardium, usually produced by injuries or neoplasms, can result from perforation into the pericardium or heart by peptic ulcers. As early as 1854, William Stokes included ulcerative perforation of the pericardium as a well-known cause of secondary pericarditis.¹ Formerly, such penetration was invariably fatal; the first survivor was reported as recently as 1964.² West, et al. after surveying recent literature, reported survival in approximately 20 percent of cases since 1964.³ Given the rising proportion of our elderly population and the apparently increasing frequency of ulcer perforation in geriatric patients, family physicians need to be aware of pericardial complications.⁴ We report the survival of an octogenarian from a hydropneumopericardium caused by penetration of the pericardium by a benign gastric ulcer. This case is even more unusual because no surgical intervention other than pericardiocentesis was necessary.

Case Report

An 88-year-old man with a history of peptic ulcer disease was sent to the hospital on November 30, 1987, with hypotension and increasing confusion. He was well known to us as a resident of the rest home managed by our department for several years. In November 1984, esophagogastroduodenoscopy (EGD) showed a gastric ulcer, two duodenal ulcers, and a bezoar thought to be

chewing tobacco. Brush biopsies and cytology were negative for malignancy then. Subsequently, in October 1985 and September 1986 he was seen because of anemia and hypotension from upper gastrointestinal bleeding. Both episodes required blood transfusion. On both occasions, upper gastrointestinal endoscopy showed bleeding from benign ulcer disease, which responded to conservative medical treatment with H₂ blockers, antacids, and sucralfate.

When examined in the emergency department by the family practice resident on call, the patient denied chest or abdominal pain, shortness of breath, nausea, vomiting, hematemesis, dysphagia, or dyspepsia. He was admitted to the family practice service. Physical examination showed he was alert and afebrile. His blood pressure was 100/60 mmHg (up from 82/50 mmHg measured at the rest home). His pulse was irregularly irregular at 130/minute. Aside from mild left upper quadrant tenderness, his examination, including lungs, otherwise was unremarkable. An ECG showed new-onset atrial fibrillation with lateral ischemia in leads V4–V6. Hemoglobin and hematocrit were 10.1 g/dL (101 g/L) and 31.6 percent (0.316), respectively, with a normal mean corpuscular volume. The BUN and serum creatinine were slightly elevated to 30 mg/dL and 1.4 mg/dL, respectively. Other laboratory results were normal. A chest radiograph showed a hydropneumopericardium (Figures 1,2).

In the emergency department, the patient's arrhythmia did not respond to a total dosage of 0.625 mg of digoxin. The family practice team consulted cardiothoracic surgeons, and the patient was taken to the catheterization laboratory, where 200 mL of straw-colored fluid were

From the Department of Family Practice, Carolinas Medical Center, Charlotte, NC; the Charlotte Area Health Education Center, Charlotte, NC; and the School of Medicine, University of North Carolina at Chapel Hill. Address reprint requests to Mary Nolan Hall, M.D., Department of Family Practice, Carolinas Medical Center, P.O. Box 32861, Charlotte, NC 28232.

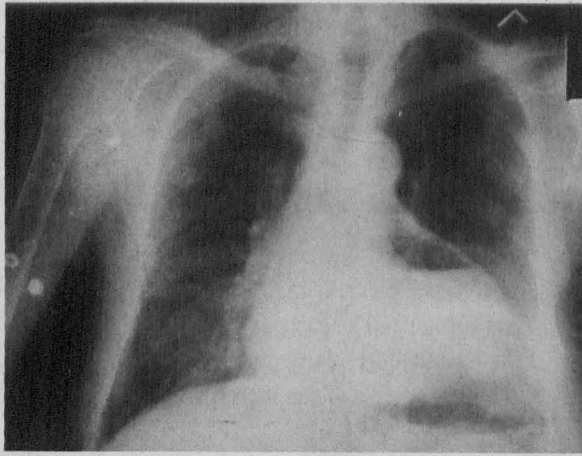


Figure 1. Admission chest radiograph – PA view.

removed from the pericardium. After pericardiocentesis, the atrial fibrillation converted to normal sinus rhythm at a rate of 86/minute. Pericardial fluid studies showed a transudate, with negative cultures, negative cytology, and white cell count was 13,200 μL (69 percent neutrophils, 31 percent mononuclear cells). The cardiology consultant thought that the etiology of the hydropneumopericardium was peptic ulcer disease with erosion into the pericardium.

A computed tomography (CT) scan of the chest and abdomen on the evening of admission showed air within the stomach at the same level as air within the pericardium and a small central communication between the stomach and pericardium. Contrast studies of the gastrointestinal tract showed no extravasation of gastrografin into the pericardium, but the area of suspected ulcer was identified in the gastric fundus.

On the next day, an endoscopy was performed, and the endoscopist confirmed "a 7–8 cm gastric ulcer on the lesser curvature, superficial, except near the gastroesophageal junction where it became deep and appeared to disappear obliquely along the edge of the ulcer." It was noted that the pulsation of the heart was transmitted to this area.

We consulted with the patient and his family and determined that they desired no further surgical intervention. We prescribed ranitidine, sucralfate, and antacids. An echocardiogram 1 week later showed minimal reaccumulation of fluid. The patient was discharged 10 days after admission and returned to the rest home on a regimen

of digoxin, ranitidine, sucralfate, and antacids. We have followed him for 18 months, and he has done well with a stable hemoglobin, maintenance of a regular cardiac rhythm, and no further evidence of gastrointestinal hemorrhage.

Discussion

West, et al. reviewed all reported cases between 1852 and 1986 of pericardial and cardiac penetration by ulcer disease,³ including 91 previously reported cases, and they added 4 new cases for a total of 95 case reports.

Men predominated in the reported cases (the ratio is 1.5:1). Generally, the illness occurs in older persons with a mean age of 51 years for men and 65 years for women. Previous gastroesophageal surgery appeared to be a major predisposing factor, occurring in 47 percent of reported cases. The major indications for the original surgery were benign esophageal strictures and hiatal hernias. Other predisposing conditions included: (1) a history of prolonged, severe peptic ulcer disease, (2) Barrett's esophagus secondary to reflux esophagitis, (3) connective tissue diseases, and (4) Zollinger-Ellison syndrome.

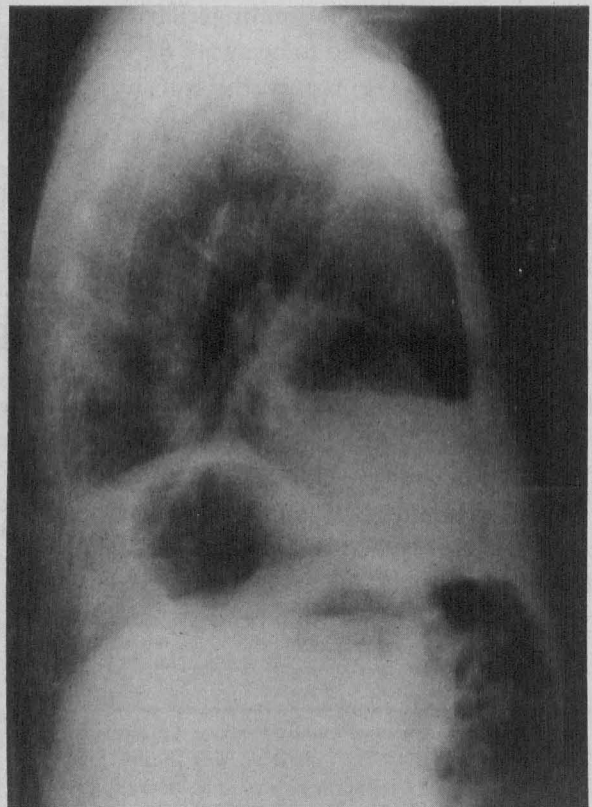


Figure 2. Admission radiograph – lateral view.

Clinical presentations varied according to the anatomic cardiac site affected by the penetrating ulcer. West, et al. divided the cases into three general types based on site of penetration: (1) ulceration into the atria, (2) ulceration into the ventricles, and (3) ulceration into the pericardium alone. Ulceration penetrating into the atria ran a fulminant course with no reported survivors. Distinctive features included hematemesis, pain (predominantly abdominal and chest), and shock. It also was associated with a high frequency of systemic embolization with associated coagulopathy. Atrial fibrillation, found in 75 percent of reported cases for which an EKG was available, was a prominent diagnostic feature.

Ulceration affecting the ventricles was likewise associated with a rapidly declining course and a low survival rate (8 percent). Clinical features were similar to atrial penetration with hematemesis and shock predominating. Electrocardiograms, available for 9 patients, showed abnormalities in all, including a pattern of infarct in 3 patients, ischemia in 1 patient, arrhythmias or heart block in 3 patients, and pericarditis in the remaining 2 patients.

Penetration of the pericardium alone represented the largest number of reported cases (46 percent). The clinical presentation was less acute than penetration of the heart itself, and there was 20 percent survival. Cases involving chest pain (65 percent) and shock (57 percent) were common, and electrocardiograms showed evidence of pericarditis in 58 percent. Approximately one-third had clinical evidence of cardiac tamponade or bruit de moulin.

For pericardial penetration, the chest radiograph was the most important diagnostic test; 90 percent of cases showed pneumopericardium. Contrast studies, when used, showed a fistulous tract in 70 percent of cases. Very little has been reported about the use of CT imaging for diagnosis of hydropneumopericardium in this setting.⁵ It was useful in confirming the diagnosis in our patient.

Our patient was similar in many ways to those in the series reported by West, because he presented subacutely with hypotension and had a

prolonged history of severe peptic ulcer disease as evidenced by two previous episodes of gastrointestinal hemorrhage and endoscopically proved benign gastric ulceration. His ECG showed acute onset atrial fibrillation, which would be more suggestive of atrial, rather than pericardial, penetration. He responded rapidly with clinical improvement and resolution of the arrhythmia after a simple drainage procedure. We surmise that the communication between the gastric ulcer and the pericardium subsequently closed spontaneously.

From the literature review, surgical treatment after pericardial penetration would seem to be indicated for definitive treatment. However, our patient and his family wished no aggressive surgical therapy for this elderly, debilitated man. He has survived without recurrence or sequelae for 18 months, lending credence to the patient's and his family's decision.

Peptic ulcer disease is a common clinical problem, and our case shows the propensity of the elderly to manifest unusual complications of common illnesses. With the increasing number of complications of peptic ulcer disease in the elderly, family physicians must be aware of this unusual manifestation in order to intervene promptly and increase their patients' chances of survival.

We gratefully acknowledge Mark S. Agness, M.D., for his assistance in the care of our patient.

References

1. Stokes W. The diseases of the heart and the aorta. Dublin: Hodges and Smith, 1854:6-7.
2. Dons N, Eriksen KR, Ryssing E, Therkelsen F. Pyopneumopericardium with oesophagopericardial fistula: report of a case with recovery. *Acta Chir Scand* 1964; 128:766-70.
3. West AB, Nolan N, O'Briain DS. Benign peptic ulcers penetrating pericardium and heart: clinicopathological features and factors favoring survival. *Gastroenterology* 1988; 94:1478-87.
4. Walt R, Katschinski B, Logan R, Ashley J, Langman M. Rising frequency of ulcer perforation in elderly people in the United Kingdom. *Lancet* 1986; 1:489-92.
5. Lehmann KG, Blair DN, Siskind BN, Wohlgeleitner D. Right atrial-esophageal fistula and hydropneumopericardium after esophageal dilation. *J Am Coll Cardiol* 1987; 9:969-72.