

# 'Effort' Thrombosis Of The Axillary And Subclavian Vein Associated With Cervical Rib And Oral Contraceptives In A Young Woman Athlete

Brian C. Aquino, M.B.B.S., and Eugene J. Barone, M.D.

**Abstract:** "Effort" thrombosis, also called the Paget-Schroetter syndrome or primary thrombosis of the upper extremity, has been well documented in the literature. However, in our review of the United States, Canadian, and British literature, we found only 52 cases in which it was related to sports participation. We report a case of axillary and subclavian vein "effort" thrombosis in a young woman athlete, who was predisposed to thrombosis by all three postulates of the Virchow triad: namely, (1) stasis caused

by constriction from a cervical rib, (2) increased coagulability as a result of oral contraceptive use, and (3) vessel wall injury because of competitive softball participation.

Of the available therapeutic plans, we believe that athletes with "effort" thrombosis should have aggressive treatment that is initiated as early as possible to prevent swelling, tingling numbness, easy fatigue of the arm, and pain on prolonged use of the affected extremity. (J Am Bd Fam Pract 1989; 2:208-11.)

Thrombosis of the axillary vein is rare, accounting for less than 2 percent of all deep venous thromboses.<sup>1</sup> It has been classified into primary and secondary thrombosis.

Primary thrombosis, or "effort" thrombosis as it is more commonly called, is a result of direct trauma to the vein, or it occurs spontaneously. It has been called "effort" thrombosis because it is usually preceded by a forceful exertion of the upper extremity.<sup>1</sup> The four most common sports that have been associated with it are baseball, gymnastics, tennis, and weightlifting (Table 1). The postulated etiology of spontaneous "effort" thrombosis includes forceful hyperabduction of the shoulder, causing stretching of the axillary vein, or the Valsalva maneuver during vigorous exertion, causing overdistention of the vein. Both cause an intimal tear that promotes venous thrombosis.

Secondary thrombosis of the upper extremity can be caused by a variety of disorders including congestive heart failure, dehydration, polycythemia, sickle cell disease, oral contraceptives, anti-

thrombin III deficiency, inflammatory bowel disease, malignancies, superior venacaval catheters, and transvenous pacemakers. Thrombosis due to extrinsic compression is also considered secondary. Compressions include cervical ribs, clavicular fractures, metastases in the axilla, thoracic outlet syndrome, and fibrosing mediastinitis.

## Case Report

An 18-year-old, right-handed woman who played softball came to the emergency room 2 days after the onset of swelling of her entire right upper extremity and pain on abduction of the shoulder. Her right shoulder had been aching for a week, but despite the discomfort, she competed in a softball tournament. The day following the game, she noticed the swelling and pain.

She had played competitive softball and basketball for the past several years, and in fact, 2 years earlier had complained of elbow pain and tingling numbness in the right thumb and in the index, middle, and ring fingers, especially at night. This was diagnosed as "Little League elbow" (an avulsion of the ossification center of the medial epicondyle) and treated with rest and ice compressions. Her history also included oral contraceptive use for 4 to 5 months preceding her present symptoms.

From the Department of Family Practice, Creighton University, Omaha, Nebraska. Address reprint requests to Brian C. Aquino, M.B.B.S., Department of Family Practice, 601 N. 30th Street, Omaha, NE 68131.

**Table 1.** Reported Number of Sports-Related "Effort" Thrombosis of the Upper Extremity.

Baseball	7
Gymnastics	6
Tennis	5
Weightlifting	4
Basketball	2
Swimming	2
Rowing	2
Ice hockey	2
Field hockey	1
Hurdling	1
Squash	1
Boxing	1
Golf	1
Handball	1
Unspecified sports	16
Total	52

On physical examination, the midarm circumference of the right arm was 6 cm greater than the left, and it was warmer and tender to palpation. A cord could be felt in the right axilla. Normal sensation and good arterial pulses were present in the right upper extremity.

Her chest roentgenogram on admission to the hospital showed bilateral cervical ribs, but it was otherwise unremarkable. A right arm venogram (Figure 1) showed a complete obstruction of the axillary and subclavian veins, with numerous transverse venous collaterals. Laboratory tests for her complete blood count, prothrombin time (PT), partial thromboplastin time (PTT), and fibrin degradation products (FDP) were normal.

Following admission, the oral contraceptives were discontinued. Urokinase was infused intravenously via an 18-gauge, right, long-arm catheter, the tip of which was kept at the distal end of the thrombus. PT, PTT, fibrinogen levels, and FDP were monitored every 6 hours, while urokinase was being administered. An initial bolus of urokinase 4000 U/kg was infused for 20 minutes and then a continuous drip at 100 U/kg/hr was maintained for 8 hours. After this infusion, a repeat venogram showed a decrease in the clot size; hence, the catheter tip was advanced, and the urokinase drip rate was increased to 1600 U/kg/hr. Fifteen hours after the first venogram, a third venogram was done, showing some patency of the vessel. This allowed the catheter tip to advance farther into the subclavian vein.

The urokinase drip was continued at 1600 U/kg/hr, and a 3000 U bolus of heparin sodium was given, followed by a continuous drip at 1000 U/hr. An elevation of the coagulation tests required a reduction of the urokinase rate to 800 U/kg/hr. Fourth and fifth venograms were done at 24 and 36 hours, respectively. A moderate-sized thrombus was still adherent to the vessel wall, and a 4-mm stenotic segment with prestenotic dilatation was seen in the region of the cervical rib. At the fifth venogram, a balloon dilatation of the stenosis was performed, dilating it to 8 mm, which was confirmed by subsequent venograms. The catheter was removed after 36 hours of urokinase continuous infusion and a final bolus of 2000 U/kg for 20 minutes. Heparin sodium was continued until the PT was raised to a therapeutic range by warfarin sodium, given orally.

Lysis of the thrombus was successful, and the patient was discharged and advised to continue warfarin sodium for 3 months. A follow-up

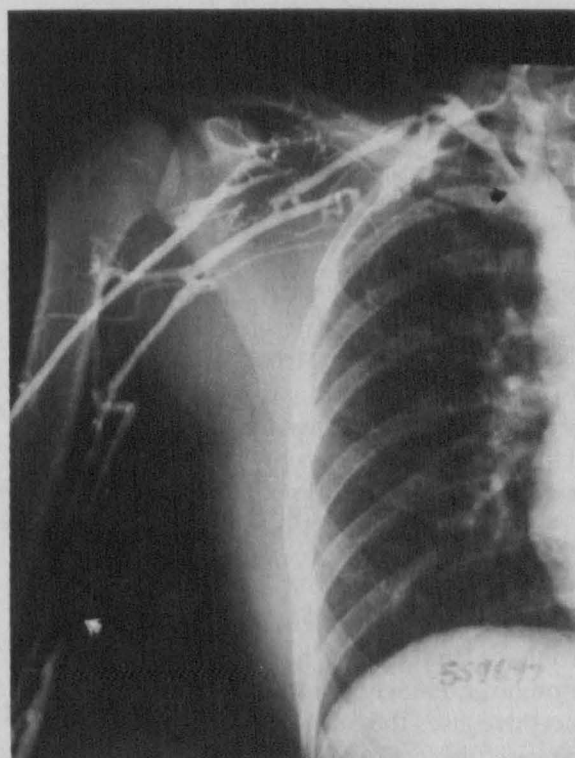


Figure 1. The right upper extremity venogram done on admission prior to treatment with urokinase and balloon angioplasty. The arrows mark the proximal and distal ends of the thrombus that totally occluded the right subclavian and axillary vein. Note the numerous collaterals.



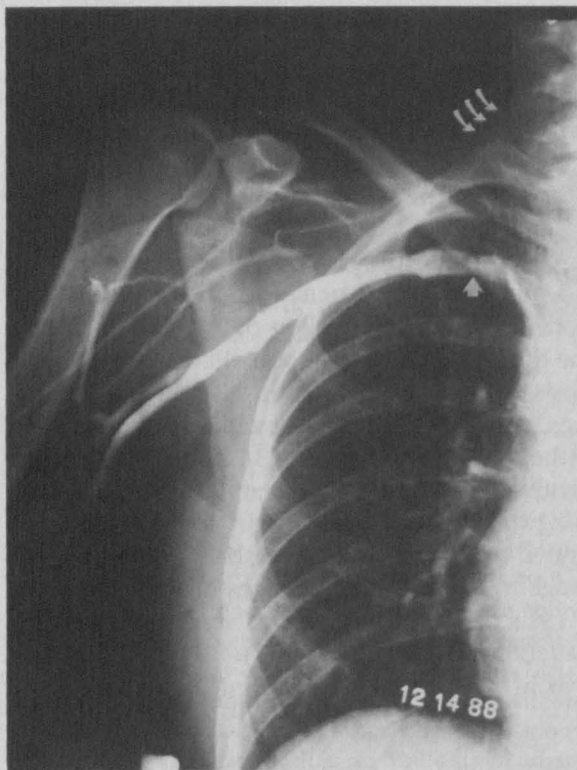


Figure 2. The right upper extremity venogram done 3 months after urokinase therapy and before cervical rib resection. There is no evidence of residual filling defect in the subclavian and axillary vein. A marked decrease in the number of collaterals is seen. The patency of the proximal balloon angioplasty site is marked by the single arrow. The triple arrows mark the cervical rib.

venogram and elective right cervical rib resection was done in 3 months (Figure 2). One month after discharge, there was no swelling or venous claudication symptoms; however, she had numbness in her fingers when her upper extremity was elevated for a prolonged time.

## Discussion

Even though our patient had two underlying problems that could have caused secondary thrombosis, namely, the cervical rib and oral contraceptive use, the softball tournament was the precipitating factor, and our diagnosis was "effort" thrombosis.

This case highlights several points applicable to physicians who do preparticipation sports physical examinations. A history of oral contraceptive use, with its potential to increase coagulability, should make us consider the risk versus benefit,

when used in women athletes. This hypercoagulable state could be further compounded by such practices as precompetition weight loss by sweating and restricting fluid intake. Croyle, et al.<sup>5</sup> reported the case of a 16-year-old high-school wrestler who suffered a massive pulmonary embolism, attributed to attempting prematch weight loss by dehydration.

The site of the thrombosis is related to the sport played. Sports that involve hyperabduction of the arm (baseball pitching, gymnastics, tennis, weightlifting) predispose to upper extremity "effort" thrombosis. Joggers, skiers, soccer players, and martial artists,<sup>15</sup> are predisposed to lower extremity thrombosis. Hence, knowing which sport a patient plays will indicate those who are at risk for "effort" thrombosis.

If a patient has symptoms of peripheral neuropathy, an examination for cervical ribs is indicated. Compression of the medial cord of the brachial plexus by a cervical rib usually causes sensory impairment in the ulnar nerve distribution (C8, T1), namely, the 4th and 5th fingers. Our patient's tingling numbness was in the distribution of the median nerve and therefore was atypical. The Adson test should be performed if a cervical rib is suspected. The Adson test estimates the volume of the radial pulses in various postures and positions of the shoulders and neck.

Choice of treatment is still a debatable issue. The three accepted treatment plans are:

1. Conservative management with intravenous heparin sodium, oral warfarin sodium, rest, and elevation.<sup>11,12</sup>
2. Surgical management with thrombectomy and release of extrinsic pressure by either clavicular resection, division of the anterior scalene muscles, or resection of the first rib or cervical rib.<sup>1,7</sup>
3. Interventional radiological lysis of the thrombus using streptokinase or urokinase.<sup>2,8</sup>

Conservative management is aimed at preventing further thrombus propagation and trying to keep the collaterals patent.<sup>12</sup> However, there is an 11 percent chance of pulmonary embolism<sup>1</sup> and a 60 to 85 percent chance of such residual symptoms<sup>1</sup> as swelling, easy fatigue of the arm, pain on prolonged use, and tingling numbness. We believe that athletes with "effort" thrombosis should be given the benefit of aggressive treatment as early as possible to prevent these sequelae.

## Conclusion

Our case emphasizes the importance of screening for risk factors of "effort" thrombosis in the pre-participation sports physical examination. Future studies need to compare long-term outcome and risk of complications for each treatment choice.

We appreciate the assistance of Mr. Wayne Wagner, Head Athletic Trainer at Creighton University.

## References

1. Adams JT, DeWees JA. "Effort" thrombosis of the axillary and subclavian veins. *J Trauma* 1971; 11:923-30.
2. Becker GJ, Holden RW, Rabe FE, et al. Local thrombolytic therapy for subclavian and axillary vein thrombosis. Treatment of the thoracic inlet syndrome. *Radiology* 1983; 149:419-23.
3. Butsch JL. Subclavian thrombosis following hockey injuries. *Am J Sports Med* 1983; 11:448-50.
4. Coon WW, Willis PW 3d. Thrombosis of axillary and subclavian veins. *Arch Surg* 1967; 94:657-63.
5. Croyle PH, Place RA, Hilgenberg AD. Massive pulmonary embolism in a high school wrestler. *JAMA* 1979; 241:827-8.
6. Demeter SL, Pritchard JS, Piedad OH, Cordasco EM, Taherj S. Upper extremity thrombosis: etiology and prognosis. *Angiology* 1982; 33:743-55.
7. Drapanas T, Curran WL. Thrombectomy in the treatment of "effort" thrombosis of the axillary and subclavian veins. *J Trauma* 1966; 6:107-19.
8. Druy EM, Trout HH 3d, Giordano JM, Hix WR. Lytic therapy in the treatment of axillary and subclavian vein thrombosis. *J Vasc Surg* 1985; 2: 821-7.
9. Huges ES. Venous obstruction in the upper extremity (Paget-Schroetter's syndrome): a review of 320 cases. *Int Abst Surg* 1949; 88:89-127.
10. Kleinsasser LJ. "Effort" thrombosis of the axillary and subclavian veins. *Arch Surg* 1949; 59:258-74.
11. Marks J. Anticoagulant therapy in idiopathic occlusion of the axillary vein. *Br Med J* 1956; 1:11-3.
12. Prescott SM, Tikoff G. Deep venous thrombosis of the upper extremity: a reappraisal. *Circulation* 1979; 59:350-5.
13. Stricker SJ, Sowers DK, Sowers JR, Sirridge MS. "Effort thrombosis" of the subclavian vein associated with oral contraceptives. *Ann Emerg Med* 1981; 10:596-9.
14. Tilney ML, Griffiths HJ, Edwards EA. Natural history of major venous thrombosis of the upper extremity. *Arch Surg* 1970; 101:792-6.
15. Zigun JR, Schneider SM. "Effort" thrombosis (Paget-Schroetter's syndrome) secondary to martial arts training. *Am J Sports Med* 1988; 16:189-90.

## ANNOUNCEMENT

The second examination leading to a **Certificate of Added Qualifications in Geriatric Medicine** will be administered to Diplomates of The American Board of Family Practice and The American Board of Internal Medicine on **April 20, 1990**.

The application period will extend from July 1, 1989, to November 1, 1989. Requirements for this examination are outlined in the ABFP, *Directory of Diplomates, 1989* (pgs. xiv and xv).

Applications may be obtained by writing to:

The American Board of Family Practice  
Geriatric CAQ Registration  
2228 Young Drive  
Lexington, Kentucky 40505-4294