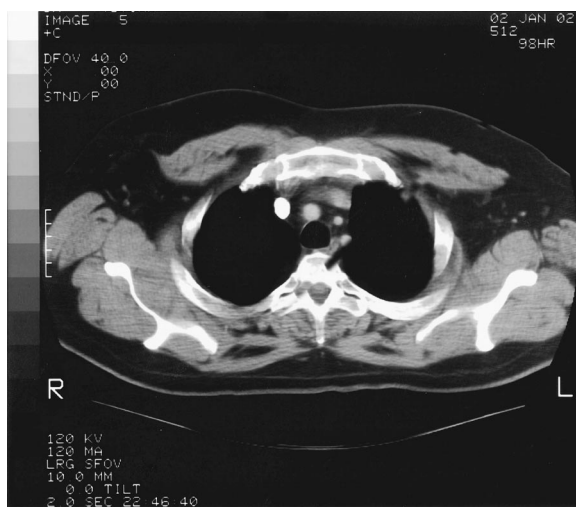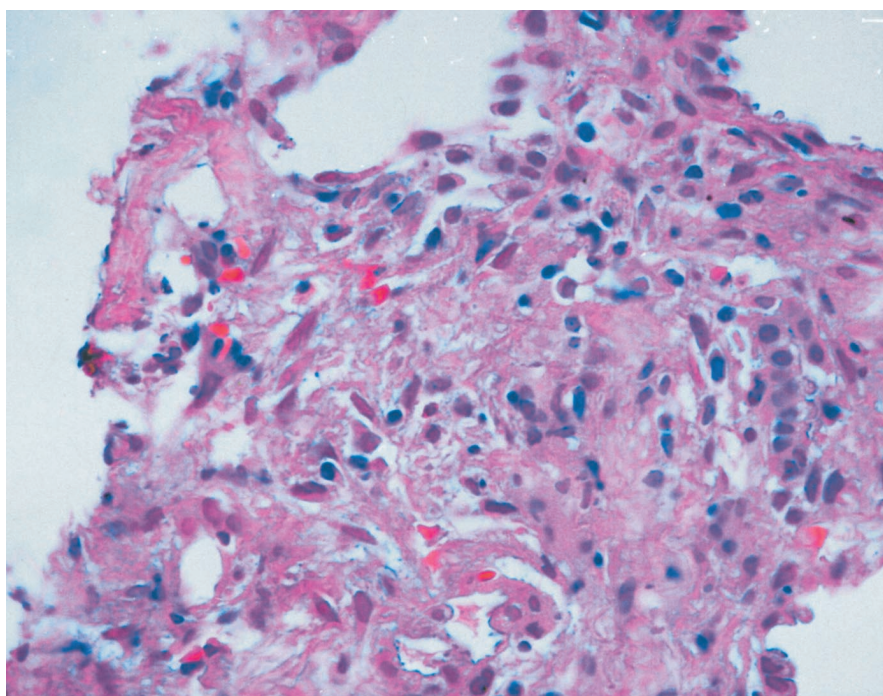






**Figure 3.** Chest CT demonstrating small noncalcified lesions in the left upper lobe.



**Figure 4.** Focus of granulomatous inflammation, lung (hematoxylin and eosin; original magnification, 400 $\times$ ).