

Wegener Granulomatosis 555

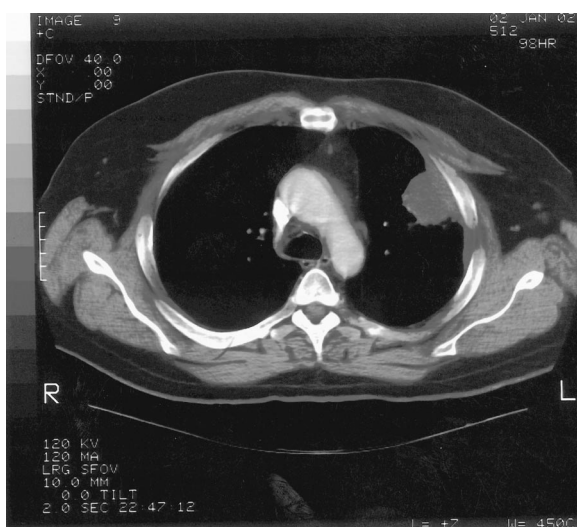

Figure 2. Coronal CT of sinuses demonstrating bilateral ethmoid and maxillary sinus disease.

On day 3, the patient complained of joint pain, mainly in the right shoulder and both hands. The patient's erythrocyte sedimentation rate and C-reactive protein level were elevated. His rheumatoid factor level was 566 IU/mL, and tests for antinuclear antibodies were negative. He was started on indomethacin and his symptoms improved in 2 days. CT-guided biopsy of the lung showed acute and chronic interstitial inflammation suggestive of a granulomatous process (Fig. 4). The patient was put in respiratory isolation until the results of 3 sets of cultures for mycobacteria came

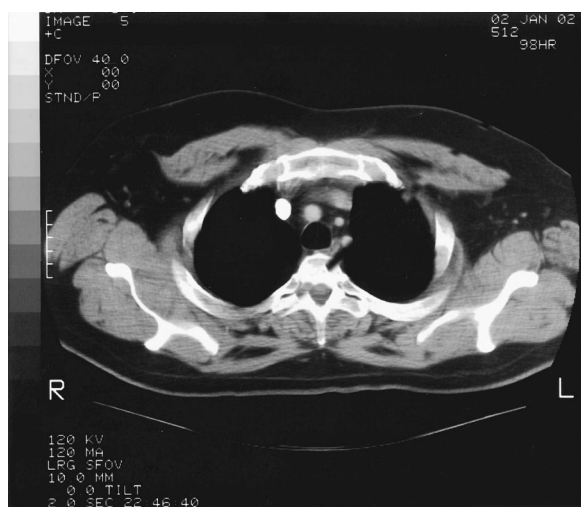

Figure 3. Chest CT demonstrating soft tissue mass in left upper lobe abutting the pleura.

back negative. Sputum cultures were negative for fungus.

On day 10, the patient developed a painful ulcer on the left side of his tongue. Cultures were obtained from the lesion, and serum cytoplasmic antineutrophil cytoplasmic autoantibody (ANCA) levels were evaluated for WG. Results of the test for human immunodeficiency virus were negative. The patient's symptoms improved significantly with indomethacin and levofloxacin. He was discharged from the hospital on day 13 taking levofloxacin, ibuprofen, and loratadine with a follow-up appointment in infectious disease clinic for culture result and evaluation of his lung mass. The patient was also scheduled for an appointment with the ear-nose-throat clinic. C-ANCA level was still pending on discharge.

Two days after discharge, the patient came back with difficulty in swallowing, flank pain, and purpuric rash on both of his lower extremities up to the abdomen. He was also complaining of dysuria and blood in the urine. His urinalysis showed positive nitrites, large amounts of blood, and more than 100 red blood cells per high-power field; 11 to 25 WBCs per high-power field, and moderate bacteria. Repeat erythrocyte sedimentation rate was 55 mm/hr, C-reactive protein level was 22.4 mg/dL, and rheumatoid factor was 1172.7 IU/mL. He had another painful ulcer on his uvula. The patient was admitted again with the diagnosis of Wegener granulomatosis, although ANCA levels were still pending from previous admission. He was started on 125 mg of intravenous methylprednisolone every 8 hours. A nephrologist was consulted.

Discussion

WG was first described by Klinger in 1933, followed by other investigators, including Rossle in 1933, Wegener in 1936 and 1939, and Ringertz in 1947.¹

WG is currently characterized as one of the ANCA-associated small vessel vasculitides. It is distinguished clinically by its predilection for affecting the upper and lower respiratory tracts and kidneys and by the histologic presence of necrosis, granulomatous inflammation, and vasculitis.

There is a strong and specific association with autoantibodies directed against proteinase 3, a constituent of neutrophil azurophilic granules.² The presence of such antibodies is a strong indicator for

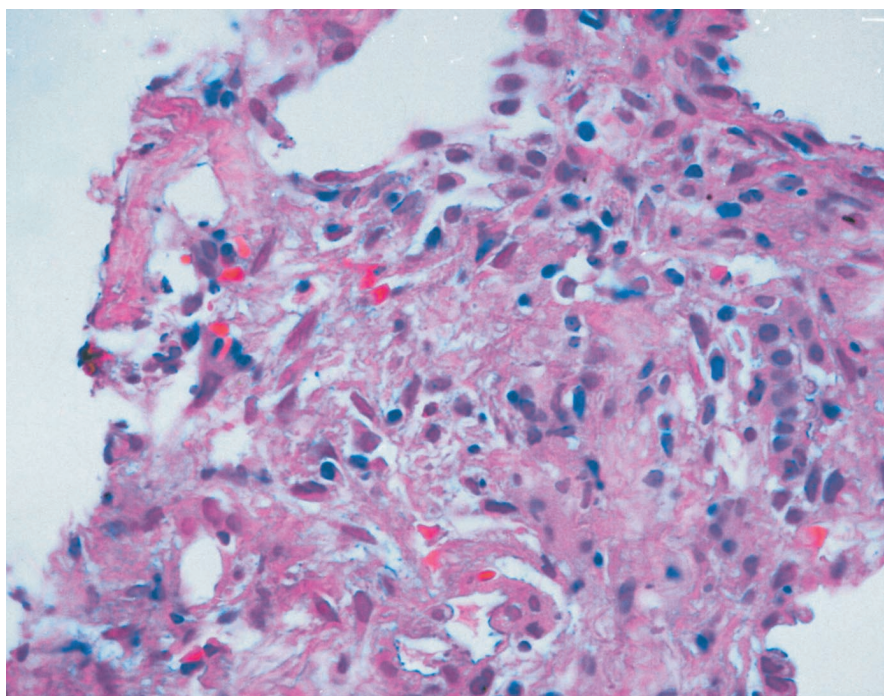


Figure 4. Chest CT demonstrating small noncalcified lesions in the left upper lobe.

a diagnosis of WG, but should not be used in place of a tissue diagnosis. The presence of ANCA is not required to make a diagnosis of WG by either the American College of Rheumatology (ACR) or the Chapel Hill Consensus Conference (CHCC) definitions.³ Occasionally, patients with infections, neoplasms, inflammatory bowel disease, sclerosing cholangitis and other rheumatologic diseases develop ANCA, but these are predominantly perinuclear ANCAs or exhibit an atypical staining pattern.⁴

Most patients are white, the sex distribution is equal, and most present in the fifth decade, although the age range extends to both extremes.⁵ The clinical presentation of WG can be so diverse that the list of differential diagnoses is vast, ranging from infections (fungal, bacterial, and mycobacterial) to other vasculitides, including Henoch-Schönlein purpura, sarcoidosis, Behcet syndrome, and malignancies.⁶

Unexplained constitutional symptoms are often part of the initial presentation. Fever and weight loss may be reported at the onset of the disease and more frequently during the course of the illness.⁵ The upper airway disease is the most common presenting feature of WG. This includes sinusitis, oral lesions (ulcer, gingivitis), otitis media, hearing loss, epistaxis, and saddle nose deformity; sinusitis

is the most frequent initial presentation in about half to two thirds of patients with WG.^{5,7}

Pulmonary involvement is one of the cardinal features of WG. It occurs in 45% of patients at presentation and 87% during the course of the disease.⁵ Cough, hemoptysis, and pleuritis are the most common pulmonary symptoms. The most common radiographic findings include pulmonary infiltrate (67%) and nodules (58%).⁵

Renal disease also may be seen as the initial presentation or during the course of the disease. Once present, renal disease may progress from asymptomatic and mild to fulminant glomerulonephritis within days or weeks, resulting in end-stage renal failure.^{7,8} Even with appropriate therapy, it may lead to chronic renal insufficiency and renal failure.⁵

Ocular manifestations have been reported to occur in 28 to 58% of patients with WG, and they may be part of the initial presentation in 8 to 16% of patients.^{9,10} A complete ophthalmologic examination is an important part of the diagnostic evaluation. Any compartment of the eye may be affected. Keratitis, conjunctivitis, scleritis, episcleritis, nasolacrimal duct obstruction, uveitis, retro-orbital pseudotumor with proptosis, retinal vessel occlusion, and optic neuritis have all been de-

scribed.^{5,9–11} Visual loss has been reported in as many as 8% of patients.⁵ CT or magnetic resonance imaging of the orbit and sinuses may provide useful anatomic information.

Other unusual presentations of WG include salivary gland, cutaneous, gastrointestinal, and cardiac involvement.^{5,7,8,11–18}

Treatment

Traditionally, initial therapy of WG consists of daily oral cyclophosphamide-corticosteroid combination therapy. This treatment has been quite effective in inducing remission in more than 90% of patients who adhere to this regimen; approximately 75% experience complete remission.^{5,19,20} The mean time to complete remission is 12 months, with occasional patients requiring treatment for more than 2 years before all symptoms have resolved. Therefore, patients should not be considered nonresponders until they have been monitored on this regimen for more than several months. Response to this regimen is defined as a lessening or resolution of the inflammatory manifestations.¹⁹ This is important because new patients may have persistent abnormalities that are not caused by active disease. For example, patients in whom the systemic symptoms and signs resolve and their urinalyses become inactive are considered to be in remission, but they may have persistent or even slowly worsening renal insufficiency.

The use of aggressive immunotherapy in this disease is justified because survival in patients with untreated WG is extremely poor; up to 90% of patients die within 2 years, usually because of respiratory or renal failure.^{5,19,20} Mortality, however, can be significantly reduced with the introduction of a cyclophosphamide-corticosteroid therapy combination. The two routes of administration are oral and intravenous. Direct comparisons between oral and intravenous cyclophosphamide also have been performed in small prospective and randomized trials.^{20–23} Intravenous and oral cyclophosphamide have similar efficacy in terms of inducing remission.^{22,23} Intravenous therapy was associated with less toxicity but a trend toward a higher rate of relapse.^{23,24} In the medical literature, the daily oral cyclophosphamide and corticosteroid regimen is the preferred method of managing these patients. However, in patients who have limited or non-life-threatening disease, monthly intravenous cyclophosphamide pulse therapy can be effective and can

minimize some of the side effects.^{21,22,24} Pulse therapy is given in conjunction with prednisone, usually starting at 1 mg/kg/day and given at this dosage for at least 1 month, then tapering by 5 to 10 mg per week until prednisone is stopped or the patient is placed on maintenance therapy of 5 to 15 mg every other day.

Other therapies for WG include methotrexate and prednisone, which is another alternative for patients with active but not immediately life-threatening disease and normal or near-normal renal function.^{25,26} This particular regimen may be attractive in patients who have limited bone marrow reserve from past cyclophosphamide therapy or a history of cyclophosphamide-induced bladder injury. Prednisone alone is not a recommended therapy for WG.^{5,24}

In those with severe disease at presentation, pulmonary hemorrhage, or worsening disease despite immunosuppressive therapy plasmapheresis may be indicated.^{27,28} There is not much clinical data to address the long-term outcome in patients who undergo plasmapheresis for WG.^{29,30}

In our case, the patient began therapy with monthly intravenous cyclophosphamide pulse therapy. The use of monthly intravenous pulse therapy is primarily to lower the overall cumulative dose of cyclophosphamide and thereby avoid some of the toxic side effects of the oral regimen. Our patient responded to intravenous pulse cyclophosphamide therapy and steroids with marked improvement in his urinalysis, decreased numbers of red blood cells per high power field, improvement in his serum creatinine level, and improvement of his inflammatory symptoms. He received a total of 6 months of intravenous pulse therapy, which he tolerated quite well, and has so far not had any signs of relapse.

References

1. Lie JT. Illustrated histologic classification criteria for selected vasculitis syndromes. *Arthritis Rheum* 1990; 33:1074–87.
2. Hewins P, Tervaert JW, Savage CO, Kallenberg CG. Is Wegener's granulomatosis an autoimmune disease? *Curr Opin Rheumatol* 2000;12:3–10.
3. Watts RA. Wegener's granulomatosis: unusual presentations. *Hosp Med* 2000;61:250–3.
4. Gross WL. Antineutrophil cytoplasmic autoantibody testing in vasculitides. *Rheum Dis Clin North Am* 1995;21:987–1011.
5. Hoffman GS, Kerr GS, Leavitt RY, et al. Wegener

- granulomatosis: an analysis of 158 patients. *Ann Intern Med* 1992;116:488–98.
6. Schmacher HR, Klippel JH, Koopman WJ, editors. *Primer on the rheumatic disease*. Atlanta: Arthritis Foundation; 1993. p. 136–48.
7. Fauci AS, Haynes BF, Katz P, Wolff SM. Wegener's granulomatosis: prospective clinical and therapeutic experience with 85 patients for 21 years. *Ann Intern Med* 1983;98:76–85.
8. Fauci AS, Wolff SM. Wegener's granulomatosis: studies in eighteen patients and a review of the literature. *Medicine (Baltimore)* 1973;52:535–61.
9. Anderson G, Coles ET, Crane M, et al. Wegener's granuloma. A series of 265 British cases seen between 1975 and 1985. A report by a sub-committee of the British Thoracic Society Research Committee. *Q J Med* 1992;83:427–38.
10. Bullen CL, Liesegang TJ, McDonald TJ, DeRemee RA. Ocular complications of Wegener's granulomatosis. *Ophthalmology* 1983;90:279–90.
11. Haynes BF, Fishman ML, Fauci AS, Wolff SM. The ocular manifestations of Wegener's granulomatosis. Fifteen years experience and review of literature. *Am J Med* 1977;63:131–41.
12. Klinger H. Grenzforman der periarteritis nodosa. *Frankfurt Z Pathol* 1931;42:455–80.
13. De Oreo GA. Wegener's granulomatosis. *Arch Dermatol* 1960;81:169–74.
14. Walton EW. Giant-cell granuloma of the respiratory tract (Wegener's Granulomatosis). *Br Med J* 1958;2:265–70.
15. Aymard B, Bigard MA, Thompson H, Schmutz JL, Finet JF, Borrelly J. Perianal ulcer: an unusual presentation of Wegener's granulomatosis. Report of a case. *Dis Colon Rectum* 1990;33:427–30.
16. Wilson RT, Dean PJ, Upshaw JD, Wruble LD. Endoscopic appearance of Wegener's granulomatosis involving the colon. *Gastrointest Endosc* 1987;33:388–9.
17. Grant SC, Levy RD, Venning MC, Ward C, Brooks NH. Wegener's granulomatosis and the heart. *Br Heart J* 1994;71:82–6.
18. Schiavone WA, Ahmad M, Ockner SA. Unusual cardiac complications of Wegener's granulomatosis. *Chest* 1985;88:745–8.
19. Hoffman GS, Leavitt RY, Fleisher TA, Minor JR, Fauci AS. Treatment of Wegener's granulomatosis with intermittent high-dose intravenous cyclophosphamide. *Am J Med* 1990;89:403–10.
20. Gross WL, Rasmussen N. Treatment of Wegener's granulomatosis: the view from two non-nephrologists. *Nephrol Dial Transplant* 1994;9:1219–22.
21. Guillevin L, Cordier J-F, Lhote F, et al. A prospective multicenter randomized trial comparing steroids and pulse cyclophosphamide versus steroids and oral cyclophosphamide in the treatment of generalized Wegener's granulomatosis. *Arthritis Rheum* 1997;40:2187–98.
22. Haubitz M, Schellong S, Gobel U, et al. Intravenous pulse administration of cyclophosphamide versus daily oral treatment in patients with antineutrophil cytoplasmic antibody-associated vasculitis and renal involvement: a prospective randomized study. *Arthritis Rheum* 1998;41:1835–44.
23. Adu D, Pall A, Luqmani RA, et al. Controlled trial of pulse versus continuous prednisone and cyclophosphamide in the treatment of systemic vasculitis. *QJM* 1997;90:401–9.
24. de Groot K, Adu D, Savage CO. The value of pulse cyclophosphamide in ANCA-associated vasculitis: meta-analysis and critical review. *Nephrol Dial Transplant* 2001;16:2018–27.
25. Langford CA, Sneller MC, Hoffman GS. Methotrexate use in systemic vasculitis. *Rheum Dis Clin North Am* 1997;23:841–53.
26. Langford CA, Talar-Williams C, Sneller MC. Use of methotrexate and glucocorticoids in the treatment of Wegener's granulomatosis. Long-term renal outcome in patients with glomerulonephritis. *Arthritis Rheum* 2000;43:1836–40.
27. Pusey CD, Rees AJ, Evans DJ, Peters DK, Lockwood CM. Plasma exchange in focal necrotizing glomerulonephritis without anti-GBM antibodies. *Kidney Int* 1991;40:757–63.
28. Cole E, Cattran D, Magil A, et al. A prospective randomized trial of plasma exchange as additive therapy in idiopathic crescentic glomerulonephritis. *Am J Kidney Dis* 1992;20:261–9.
29. Zauner I, Bach D, Braun N, et al. Predictive value of initial histology and effects of plasmapheresis on long-term prognosis of rapidly progressive glomerulonephritis. *Am J Kidney Dis* 2002;39:28–35.
30. Guillevin L, Lhote F, Cohen P, et al. Corticosteroids plus pulse cyclophosphamide and plasma exchanges versus corticosteroids plus pulse cyclophosphamide alone in the treatment of polyarteritis nodosa and Churg-Strauss syndrome patients with factors predicting poor prognosis. A prospective, randomized trial in sixty-two patients. *Arthritis Rheum* 1995;38:1638–45.