

Office Management of Penile Skin Bridges with Electrocautery

Sody A. Naimer, MD, Roni Peleg, MD, Yevgeni Meidvidovski, MD, Alex Zvulunov, MD, Arnon Dov Cohen, MD, and Daniel Vardy, MD

Background: Penile skin bridges are an uncommon complication of circumcision that are often found in general practice. This condition can be treated successfully in the office, avoiding referral for a surgical procedure.

Methods: Four case reports of the technique of treating penile skin bridges are described, and the literature on the cause and treatment of skin bridges is reviewed.

Results and Conclusions: Using local anesthesia and bipolar diathermy, penile skin bridges were successfully treated in the office on 4 patients of different ages. There was no bleeding and the wounds healed without complication. This brief and simple technique, described in detail, is appropriate for an office procedure in family practice. (J Am Board Fam Pract 2002;15:485–8.)

Penile skin bridges are an uncommon complication of circumcision. They are often found in general practice and referred to the hospital for inpatient treatment. Skin bridge formation is usually recognized in infancy and often treated by excision under general anesthesia. This report describes our recent experience in treating four cases of broad skin bridges. The technique is described in detail because we expect that others adopting this method will join our satisfaction with the simplicity and feasibility of its individual components.

Methods

Four case reports of the technique of treating penile skin bridges are described, and the literature on the cause and treatment of skin bridges is reviewed.

Case 1

A 20-year-old male patient came to our clinic complaining of a chronic condition that disturbed him recently. He claimed that the shape of his genital organ “just didn’t seem right.” He had emigrated from Ethiopia a number of years earlier and was

told that he underwent traditional circumcision as a baby. He recalled this condition for as long as he can remember.

There were no specific symptoms, except for a foul odor that disturbed him little. He denied involvement in any sexual activity in the past or present. The young man chose not to consult any medical professional about this peculiarity until this point.

On examination, the anatomy of the penis appeared normal aside from the absence of the corona, which seemed completely obscured dorsally (Figure 1). There were no signs of inflammation. Close examination showed two separate adhesions, or skin bridges, orientated dorsolaterally and horizontally toward either side of the shaft. The skin bridge was inseparably confluent with the normal glans on the distal aspect and to the shaft skin proximally. An attempt to probe the virtual canals with wooden probes lubricated by white petrolatum proved successful (Figure 2). This procedure recovered underlying smegma. The area was painted with a povidone solution, and then anesthetized with 3 mL of 1% lidocaine solution without epinephrine in a 5-mL syringe by a subcutaneous injection with a 23-gauge needle at the base of the bridge. With the surface of the shaft skin safeguarded by the intact probes secure in position, electrocautery was performed over the dorsal bridges along the probes.

The whole procedure was completed within 5 minutes without any immediate or late bleeding. Complete bridge release was successfully achieved

Submitted, revised, 19 December 2001.

From the Goosh Katif Health Centre (SAN), Goosh Katif; the Department of Family Medicine (SAN, RP), Sial Research Center for Family Medicine and Primary Care, Ben Gurion University, Faculty of Health Sciences, Beer-Sheva; the Regional Specialist Center C (YM, AZ, ADC, DV), Beer-Sheva; and the Ben Gurion University, Faculty of Health Sciences (YM, AZ, ADC, DV), Beer-Sheva, Israel. Address reprint requests to Sody A. Naimer, MD, Department of Family Medicine, Ben-Gurion University of the Negev, PO Box 653, Beer-Sheva, Israel 84105.

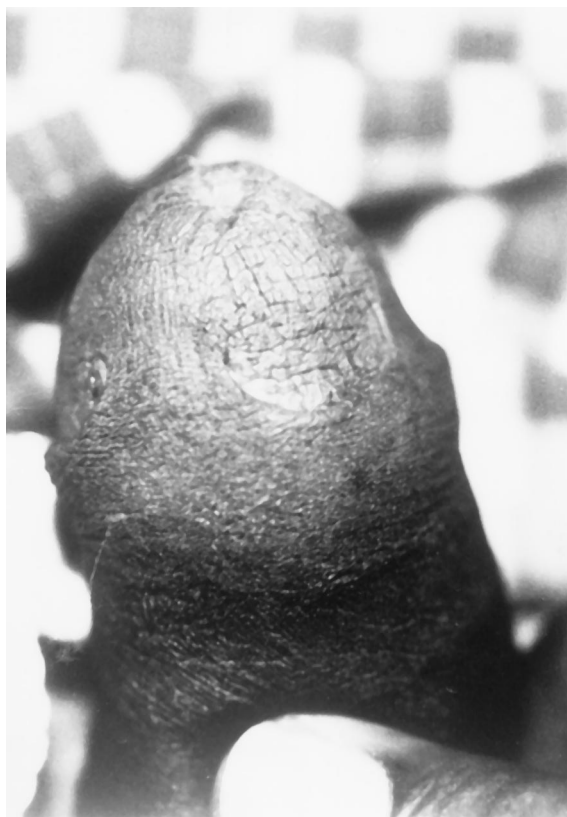

Figure 1. Double skin bridges causing complete dorsal concealment of dorsal corona.

with little discomfort to the patient (Figure 3). Gradual improvement continued until full healing was apparent at follow-up visits.

Case 2

A 62-year-old married gentleman came to our clinic complaining of a common skin condition. Before leaving, he called the physician's attention to a seemingly trivial, long-term finding. He claimed to suffer from this problem since early childhood. His main symptoms were pain during erection, which was greatly enhanced during sexual activity. He recalled being told he was circumcised normally shortly after birth in Morocco, his birthplace. When he was examined, a single dorsal skin bridge was apparent. After he consented to a therapeutic procedure, the bridge was treated as described in case 1 and released that same session, free of any bleeding whatsoever. At the follow-up visit, he told of relief of symptoms he suffered from for the past 60-odd years.

Case 3

An overweight 8-day-old newborn (above 95th percentile) underwent traditional circumcision by the first author (SAN). At the time, the genital organ was observed buried inside the skin of the mons pubis. The prepuce was successfully removed by traditional circumcision and healed normally. Two months after the procedure the baby was examined again at the mother's request since she claimed "the penis seems to disappear." The body of the penis was fully sunken into the surrounding soft tissue. After extraction by local pressure, the skin of the

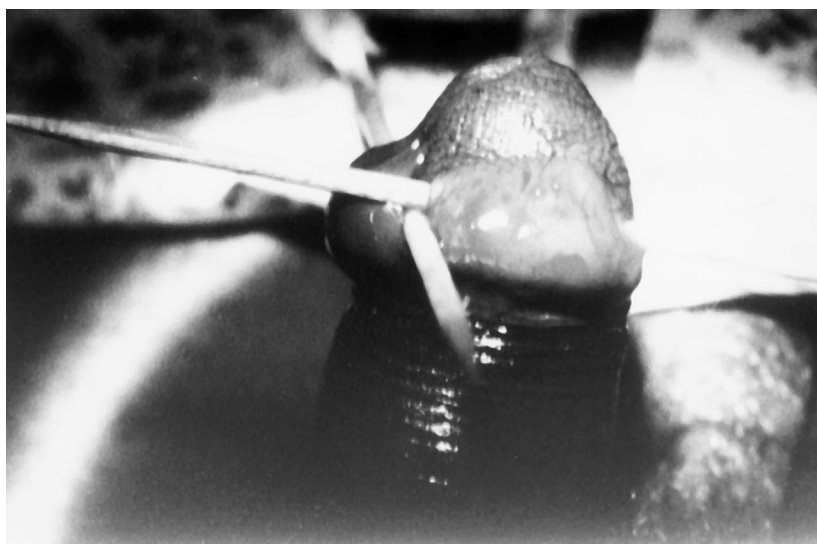


Figure 2. Wooden "probes" secure in position, the bridges appear edematous immediately following local anesthesia.

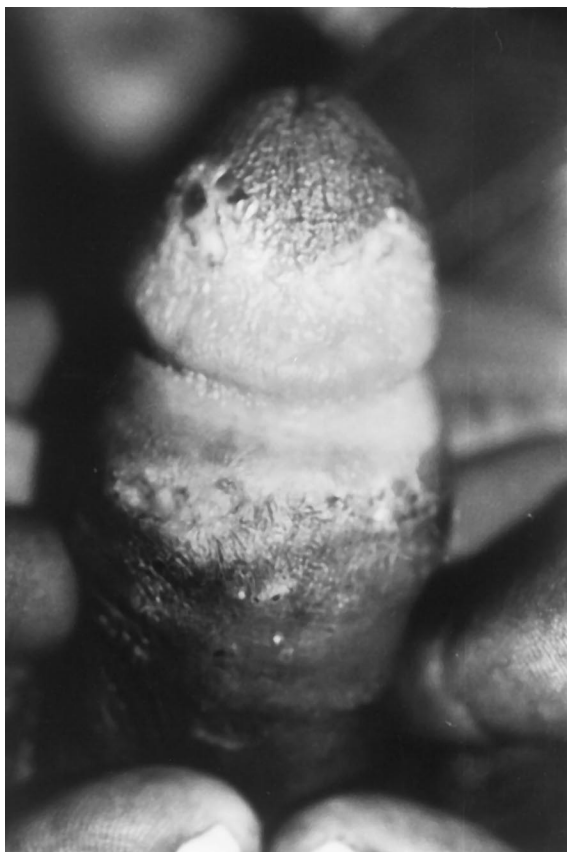

Figure 3. Spontaneous bridge regression apparent a number of days after hyfrecation incision.

proximal shaft was found circumferentially adherent to the corona. Forceful retraction of the shaft skin resulted in pain and minor bleeding and a gauze bandage was applied to maintain separation of the skin from the surface of the corona. The mother was instructed to perform daily manual retraction of the skin in a soap bath.

One month later at a follow-up visit, the situation was similar to the previous examination except for a genuine skin bridge, which had completely materialized on the dorsal aspect. The release procedure was performed when the infant was 5 months old, using the same technique as outlined above. Complete cure was appreciated with no recurrences as the baby grew older and became more active.

Case 4

A 51-year-old devout Jewish gentleman arrived at the dermatology clinic complaining of a dermatologic condition in the inguinal area. Examination showed a solitary skin bridge. On questioning, he

admitted to years of suffering from tightening and tugging of the anterior aspect of his genital organ when erect. He was immediately offered treatment as described and was both surprised and relieved when the procedure was completed in such a brief and simple fashion.

Discussion

The pathogenesis of penile skin bridges is still under dispute. To date, the debate converges on whether it stems from incomplete prepuce excision at the time of circumcision.^{1,2} As case 3 shows, we advocate that it is caused by adhesion of a remnant of fully excised foreskin to the healthy skin of the dorsal glans penis. We report two extreme cases of broad skin bridges primarily in the adult. This exaggerated phenomenon might have easily been prevented in infancy had the skin adhesions been recognized early enough, and satisfactory retraction of the proximal skin performed regularly.³

Further dispute has been raised in the literature whether electrocautery offers a safe and effective method of treating surgical penile conditions.⁴⁻⁷ An unpublished quoted survey of the American Academy of Pediatrics Urology Section found 94% of respondents advocate use of electrical current for procedures of the penis, whereas only 26% apply this mode in practice.⁵ Fears of harm caused by electric current are raised by concern that heat might accumulate at the base of the penis as electrons flow from the generator to the patient and back, thus causing tissue necrosis.⁷ The proponents claim clear safety of electrocautery provided it is not applied directly to the Gomco clamp.^{8,9} In our technique this disputed technique is bypassed altogether, since the chosen utensil for nonhemorrhagic skin avulsion is the less-expensive bipolar diathermy. In addition, as opposed to our predecessors when dealing with this condition, the procedure was performed outside the operating room under local anesthesia alone.

Skin bridges can appear in a variety of sizes and shapes. The minor bridges are narrow and essentially avascular, allowing hemostasis using 20% aluminum chloride solution (Drysol) or a silver nitrate stick. The thicker, more vascular bridges demand electrocautery, as in case 1. A disposable battery-powered office cautery unit, which is sometimes more easily accessible, is equally as effective as the more expensive wall-mounted units. It should be

remembered that to avoid potentially harmful vasoconstriction, adrenaline must not be added to an anesthetic solution. The anesthetic can be injected comfortably through a 25-, 26- or 30-gauge needle, if available. Reattachment of the adhesion can be prevented by strict adherence to a daily manual retraction routine or by lubrication with antiseptic ointment until healing.

We have described our experiences in treating penile skin bridges in four different cases. This complaint can be found at the extreme of age-groups and yet be treated identically by the illustrated technique. Our success was achieved using local anesthesia, and the bridge excision was performed free of bleeding by means of electrocautery. When a penile skin bridge was recognized, an immediate and simple solution was accomplished without any further complications.

These cases show the advantages of this mode of therapy as a simple, brief, painless, safe, and inexpensive option. We recommend this intervention as a convenient measure for this type of condition. Furthermore, we believe that such a complaint falls in the scope of the ambulatory setting and should confidently be dealt with as an office procedure.

In the era of managed care, with insurers dictating which procedures are to be covered, expense often becomes a major determinant in deciding whether a procedure is performed or abandoned. Reducing costs by altering technique, as in this example, is of prime importance, particularly when the changes do not jeopardize patients any further.

Performing a definitive intervention on the premises of casual consultation saves time and energy while enhancing trust and comfort between the patient and his physician. Familiarity with this clinical condition, as described in this report, is sufficient to guide the family physician precisely how to manage it and provide full satisfaction.

References

1. Ritchey ML, Bloom DA. Re: Skin bridge - a complication of pediatric circumcision. *Br J Urol* 1991; 68:331.
2. Sathaye UV, Goswami AK, Sharma SK. Skin bridge - a complication of pediatric circumcision. *Br J Urol* 1990;66:214.
3. Gracely-Kilgore KA. Penile adhesion: the hidden complication of circumcision. *Nurse Pract* 1984;9: 22-4.
4. Azmy A, Boddy SA, Ransley PG. Successful reconstruction following circumcision with diathermy. *Br J Urol* 1985;57:587-8.
5. Peters KM, Kass EJ. Electrosurgery for routine pediatric penile procedures. *J Urol* 1997;157:1453-5.
6. Aragona F, Ferrarese P, Glazel GP. Urological use of a disposable bipolar diathermy probe: an experimental in vivo study. *Int Urol Nephrol* 1990;22: 493-7.
7. Gearhart JP, Rock JA. Total ablation of the penis after circumcision with electrocautery: a method of management and long-term followup. *J Urol* 1989; 142:799-801.
8. Metzgar MR, Stoudsburg PA. A quick method of circumcision. *Am J Obstet Gynecol* 1955;70:14.
9. Belman AB. Electrocautery circumcision. *Urology* 1981;18:506-7.