

Large, Complex, Benign Cystic Teratoma in an Adolescent

Mark K. Huntington, MD, PhD, Robert Kruger, MD, and David W. Ohrt, MD

Germ cell tumors make up 15% to 20% of all ovarian tumors, 95% of which are dermoid cysts, also known as benign cystic teratomas.^{1,2} Primarily ectodermally derived, tissues can grow from any of the germ cell layers. Tumors occur bilaterally in 10% of cases, and there appears to be an increased rate of sterility in patients with cystic teratomas.³ These tumors are found in women of reproductive age, undergo malignant transformation only rarely (<1%), and are most conducive to surgical cure.

We report an unusual case of an asymptomatic, advanced benign cystic teratoma in a young adolescent.

Case Report

A 14-year-old girl, who was born at home, had her first interaction with the medical system when she arrived complaining of a possible abdominal tumor. During the previous 6 months she had noticed an increasing fullness in her abdomen, which had progressed to the point that it was difficult for her to take a deep breath. Other than a physically enlarged abdomen, there had been no dyspepsia or nausea, pain, constipation or diarrhea, fever, fatigue, or other constitutional symptoms. She reported no unusual weight gain or loss. Her menses had been regular, and she was not sexually active.

The patient was in no acute distress; she was alert and oriented, pleasant, with a full affect, and exhibited a more mature interaction than many adolescents her age. When examined, she had a distended abdomen consistent with a full-term pregnancy. Her abdomen was not tender and had normal bowel sounds. There was an equivocal fluid wave. Findings on examination of her heart and lung were unremarkable. She had a normal vulva with an intact hymenal ring. Her cervix was nulli-

parous, and there was no cervical motion tenderness or discharge. Her adnexa were not tender, and her ovaries were not palpably distinct from a pelvic abdominal mass. A urine chorionic gonadotropin assay was negative for pregnancy, and an abdominal plain film (Figure 1) showed left-sided opacities consistent with Rokitansky nodules. The diagnosis of a large dermoid cyst was made.

The patient was subsequently admitted for surgical removal of her cyst. A low Pfannenstiel incision exposed a large intra-abdominal cystic mass attached to the left fallopian tube; there was no evidence remaining of the left ovary. A 1-cm incision, equipped with a 0-nylon purse-string suture, was made in the cyst, and a suction catheter was inserted with negligible spillage of the cyst contents. Five liters of fluid were aspirated before the mass could be removed through the abdominal incision. After the cyst was aspirated, the suction catheter was removed, and the incision into the cyst was closed with the purse-string suture. The right ovary and tube were of normal size and appearance. The mass was dissected to separate it from the fallopian tube, leaving the tube and fimbriae intact. Copious irrigation was used to minimize the risks associated with the introduction of dermoid material into the peritoneum.⁴⁻⁶ The wound was then closed, and the patient was transferred to recovery in good condition but having lost more than 10 kg from her preoperative weight (Figure 2). Her recovery was uneventful. She was released on postoperative day 3 and has been entirely compliant with scheduled follow-up care.

The cyst, which was opened in the operating room, was an exceptionally complex structure of multiloculation and cysts within cysts, each filled with fluids of differing colors, consistencies, and viscosities. There was more than 2.5 L of additional fluid. The cyst also contained a great amount of sebaceous material and hair (Figure 3). Several tooth-like structures were grossly apparent.

Histologically, this large dermoid cyst was composed of tissues derived from all germ layers: re-

Submitted 22 March 2001.

From the Northside Medical Center (MKH), Ortonville, and the Affiliated Community Medical Center (RK), Wilmar, Minn; and the Laboratory of Clinical Medicine (DWO), Sioux Falls, SD. Requests for reprints should be addressed to Mark K. Huntington, MD, PhD, Northside Medical Center, 435 Eastvold Ave, Ortonville, MN 56278.

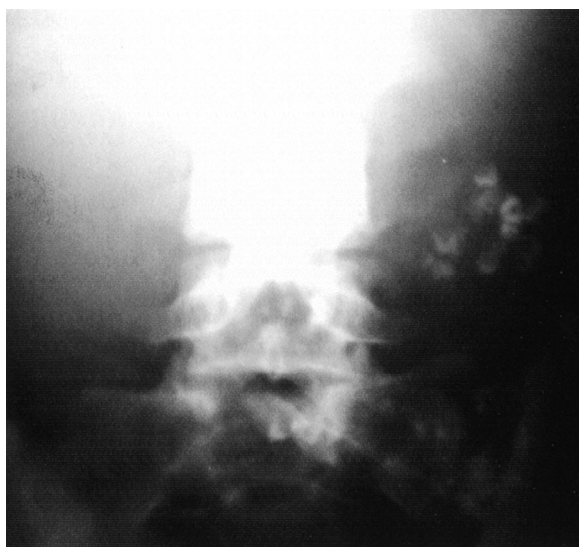

Figure 1. Abdominal plain film showing Rokitsky nodules.

spiratory mucosa with bronchial type cartilage, squamous mucosa, gastric mucosa, intestinal mucosa, prominent skin and skin adnexal structures, fat, smooth muscle, tooth-like structures, and mature central nervous system-type tissue. There was no evidence of immature elements or malignancy.

Discussion

The origin of dermoid cysts, originally blamed on adultery with the devil, is currently believed to be a

primordial germ cell. All dermoid cysts have a 46,XX karyotype, and it has been suggested that they arise from an ovum after the first meiotic division.^{3,7} One report of a mother and her two daughters, all with ovarian dermoid cysts, suggests chromosomal instability might play a role in some cases.⁸

Although dermoid cysts often cause abdominal pain and mass, their symptoms occasionally include gastrointestinal complaints and menstrual disturbances.³ Torsion has been reported in nearly 10% of cases, and 13% to 66% are asymptomatic.^{9,10}

This case is noteworthy for several reasons. First, the size of the tumor was unusual. Seventy-five percent of dermoid cysts are less than 10 cm in diameter at the time of resection.³ Its massive dimensions can be attributed to a delay in seeking care. Before the patient came to the clinic, she had had no previous contact with the medical profession. She had been born at home to respected members of a primarily agricultural community, had experienced excellent overall health, and had participated in no competition sports. Thus, she had had no recent examinations that might have detected the mass at a smaller stage. There was no concern of abnormal family dynamics, and when they realized their daughter had an abdominal mass, her parents sought appropriate care promptly.

Laparoscopy is the preferred method of treatment for dermoid cysts.¹¹⁻¹³ Ordinarily, sonography and magnetic resonance imaging are recommended in evaluating the suitability of a patient for possible laparoscopic resection of these tumors,¹⁴ but the size of the tumor in this case rendered such evaluation largely moot. Indeed, because of its size, a midline incision was the easiest approach to removal. For cosmetic reasons, the cyst was removed through a low transverse incision. Although the incision was not large enough to remove the cyst intact, aspiration of a portion of the cyst's contents allowed delivery of the partially deflated cyst without having to resort to a large midline incision. The importance of such cosmetic considerations to the psychological well-being of a young adolescent woman cannot be overemphasized. This approach allowed the removal of a large tumor through a relatively small incision without endangering the patient's safety. Dissecting the tumor to separate it from the fallopian tube, rather than performing a hemisalphingectomy, minimized the adverse effects

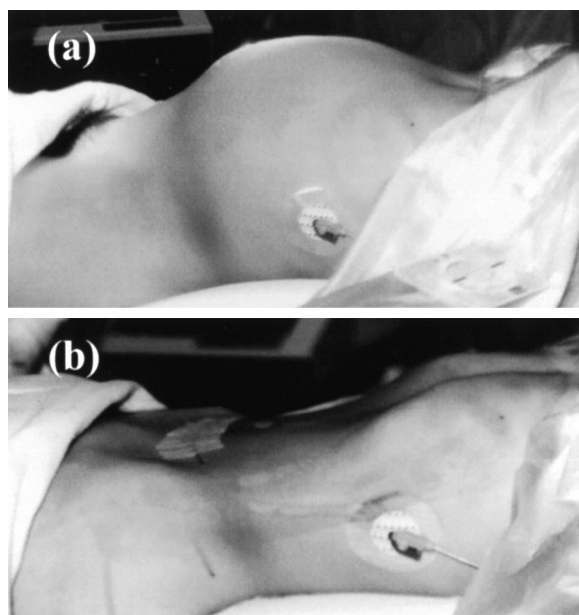


Figure 2. Patient's abdominal profile (a) before and (b) after excision of the dermoid cyst.

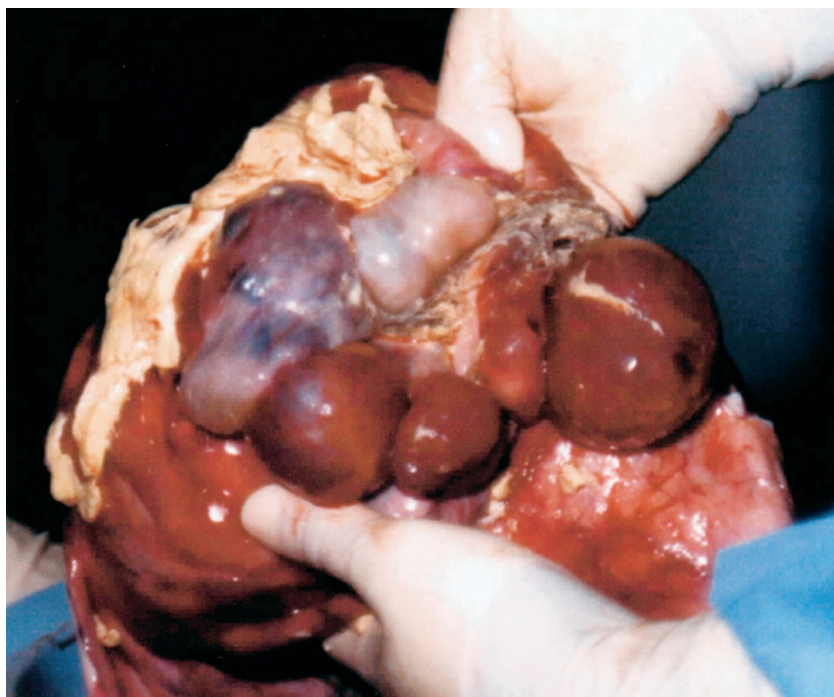


Figure 3. Gross appearance of the dermoid cyst with large quantities of hair and sebaceous material.

of the tumor and its treatment on the patient's future fertility, another important consideration in this type of patient.

The complex architecture of this teratoma was also unusual. Characteristically, benign (mature) teratomas are unilocular, whereas malignant (immature) teratomas contain many small loculi or cystic spaces. Additionally, the tissues of benign teratomas are predominantly ectodermal; malignant teratomas contain a wide variety of tissues deriving from all three germ layers. Malignant teratomas are graded according to the degree of tissue immaturity and the presence of neuroepithelium.³ Although in our case all layers were represented, with a preponderance of central nervous system tissue, there was no evidence of immature neural elements. Benign cystic teratomas have a low malignant potential, which increases with an increase in the proportion of the solid component of the tumor.^{3,15} In postmenopausal patients, as opposed to younger patients such as ours, evaluation of tumor markers can be helpful as part of the preoperative workup.¹⁴

We have described a case of a massive ovarian teratoma that, although predominately cystic and histologically benign, had gross features more commonly associated with immature teratomas. Despite its magnitude, we were able to remove the

tumor through a low Pfannenstiel incision after intraperitoneal partial evacuation of cyst contents. The result was an improved cosmetic outcome while not compromising the patient's safety.

Kyla Powell contributed technical assistance in obtaining the intraoperative photographs.

References

1. Kurman R, Norris HJ. Germ cell tumors of the ovary. *Pathol Annu* 1978;13(Pt 1):291-325.
2. Talerman A. Germ cell tumors of the ovary. In: Blaustein A, editor. *Pathology of the female genital tract*. New York: Springer-Verlag, 1982:602-4.
3. Robbins SL, Cotran RS, Kumar V. *Pathologic basis of disease*. 3rd ed. Philadelphia: WB Saunders, 1984: 1149-51.
4. Yani-Inbar I, Scully RE. Relation of ovarian dermoid cysts and immature teratomas: an analysis of 350 cases of immature teratoma and 10 cases of dermoid cyst with microscopic foci of immature tissue. *Int J Gynecol Pathol* 1987;6:203-12.
5. Edwards AG, Lawrence A, Tsaltas J. Ovarian dermoid cyst leakage—a cautionary tale. *Aust N Z J Obstet Gynaecol* 1998;38:332-3.
6. Fielder EP, Guzik DS, Guido R, Kanbour-Shakir A, Krasnow JS. Adhesion formation from release of dermoid contents in the peritoneal cavity and effect of copious lavage: a prospective, randomized,

- blinded, controlled study in a rabbit model. *Fertil Steril* 1996;65:852–7.
7. Linder D, McCaw BK, Hecht F. Parthenogenic origin of benign ovarian teratomas. *N Engl J Med* 1975;292:63–6.
8. Gustavson KH, Rune C. Familial ovarian dermoid cysts. *Ups J Med Sci* 1988;93:53–6.
9. Pepe F, Panella M, Pepe G, Panella P, Pennisi F, Arikian S. Dermoid cysts of the ovary. *Eur J Gynaecol Oncol* 1986;7:186–91.
10. Bloomfield TH. Benign cystic teratomas of the ovary: a review of seventy-two cases. *Eur J Obstet Gynecol Reprod Biol* 1987;25:231–7.
11. Albini SM, Benadiva CA, Haverly K, Luciano AA. Management of benign ovarian cystic teratomas: laparoscopy compared with laparotomy. *J Am Assoc Gynecol Laparosc* 1994;1:219–22.
12. Chapron C, Dubuisson JB, Samouh N, et al. Treatment of ovarian dermoid cysts. Place and modalities of operative laparoscopy. *Surg Endosc* 1994; 8:1092–5.
13. Yuen PM, Yu KM, Yip SK, Lau WC, Rogers MS, Chang A. A randomized prospective study of laparoscopy and laparotomy in the management of benign ovarian masses. *Am J Obstet Gynecol* 1997;177: 109–14.
14. Simon P, Noterman D, Anaf V. Diagnostic and therapeutic approach of dermoid cysts: retrospective study of 30 cases. *Acta Chir Belg* 1998;98:154–7.
15. Young RH. New and unusual aspects of ovarian germ cell tumors. *Am J Surg Pathol* 1993;17: 1210–24.