

Ramsay Hunt Syndrome in a Patient With Human Immunodeficiency Virus Infection

Augustine J. Sohn, MD, MPH, and Patrick A. Tranmer, MD, MPH

Ramsay Hunt syndrome consists of herpetic eruption of the skin of the external ear and varicella zoster virus (VZV) involvement in the geniculate ganglion of the ipsilateral facial nerve. Although it is rare, it is more commonly found with immunodeficiency conditions. With the growing incidence of human immunodeficiency virus (HIV) infection, we could see more cases of Ramsay Hunt syndrome in the future.

We had a case of Ramsay Hunt syndrome in an HIV-infected patient at the Department of Family Medicine, the University of Illinois at Chicago. The purpose of this report is to increase the awareness of this clinical entity among family physicians who are now taking care of HIV-infected patients.

Case Report

A 33-year-old male patient was admitted to the University of Illinois Hospital because of headache, severe otalgia, and vesicular lesions on the right ear canal and the pinna of his right ear. HIV infection had been diagnosed by enzyme-linked immunosorbent assay (ELISA) and Western blot HIV serum antibody tests 20 months before this admission. His initial CD4⁺ lymphocyte count was 390/ μ L in May 1994. He had never been on antiretroviral therapy and had a history of chickenpox. He had been vaccinated against influenza viruses in the fall of 1995, and his most recent CD4⁺ cell count before this event was 560/ μ L. The patient had a peripheral right facial nerve palsy 4 months before admission, which resolved spontaneously in 2 weeks. At that time, a gadolinium-enhanced magnetic resonance imaging (MRI) study showed enhancement of the geniculate ganglion of the right facial nerve (Figure 1).

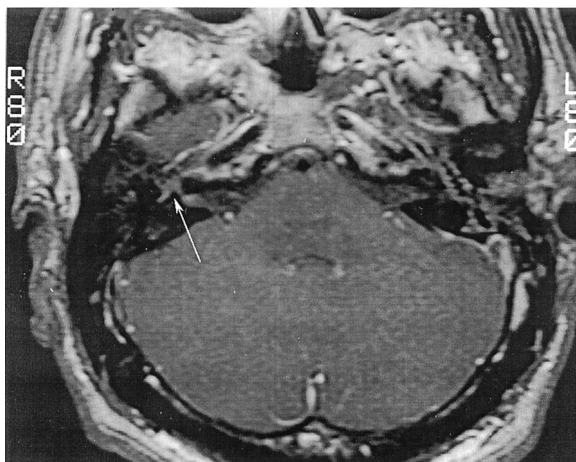


Figure 1. Enhancement of the geniculate ganglion of the right facial nerve (4 months before admission).

One day before his admission, the patient was seen at our outpatient center with the complaint of severe right ear pain and headache. When examined, he had considerable erythematous swelling on his right ear canal and vesicles on the pinna. A herpes culture was taken. The right tympanic membrane could not be seen because of inflammation of the ear canal. The left ear was normal. The patient was given prescriptions for acyclovir, 800 mg every 4 hours 5 times a day, and hydrocodone bitartrate and acetaminophen every 4 hours for pain. The patient began vomiting and could no longer tolerate oral acyclovir; he was admitted to the hospital the next day.

At admission his temperature was 99.2°F, blood pressure 125/90 mm Hg, pulse 92 beats per minute, and respirations 18/min. He had erythematous swelling of the right ear, and the auricle was extremely tender. There were numerous small vesicles on the auricle and the pinna. His right ear canal was closed. His left ear was normal. He was given acyclovir 5 mg/kg intravenously every 8 hours and meperidine hydrochloride 50 mg intramuscularly every 4 hours. The patient still had headaches and photosensitivity the next day and continued vomiting despite no oral intake. He had vertigo and

Submitted, revised, 29 December 2000.

From the Department of Family Medicine (AJS, PAT), University of Illinois at Chicago. Address reprint requests to Augustine J. Sohn, MD, MPH, Department of Family Medicine, University of Illinois at Chicago, 1919 W Taylor, Chicago, IL 60612.

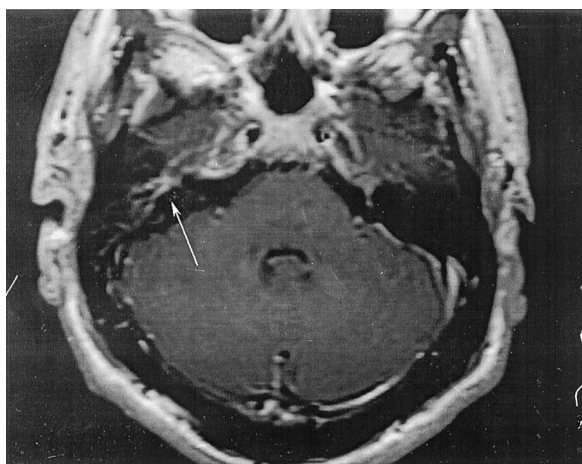


Figure 2. Enhancement of the geniculate ganglion of the right facial nerve (at the time of admission).

decreased hearing in the right ear. He was found to have horizontal nystagmus with fast component to the right. Computerized tomography (CT) of the brain was negative for intracranial mass. On the 4th hospital day, he was able to tolerate oral acyclovir. On the 5th hospital day, a gadolinium-enhanced MRI scan of the brain showed enhancement of the geniculate portion of the right facial nerve (Figure 2). A viral culture from the right ear obtained before admission was negative for herpes simplex virus after 7 days of incubation. The patient was released on the 7th hospital day.

The patient continuously had tinnitus and vertigo, as well as decreased hearing, after he was released from the hospital. Two weeks after the onset of the auricular vesicles, the lesions and otalgia were almost completely gone. Two months and 8 months after the onset of the disease, audiograms showed he still had moderate sensorineural hearing loss on the right side, and he had minimal tinnitus with good speech discrimination. When the patient was admitted to the hospital, the serum samples were drawn to determine herpes viruses titers. An immunoglobulin G (IgG)-specific antibody titer for herpes zoster was 6.76. An IgG-specific antibody titer for herpes simplex type 1 was 4.67, and an IgG-specific antibody titer for herpes simplex type 2 was 5.27. All were highly positive. There were no follow-up titers measured.

Discussion

In 1907 J. Ramsay Hunt¹ suggested that the syndrome be divided into three clinical groups: (1)

herpes zoster auricularis, (2) herpes zoster in any of the zoster zones of the head and neck (herpes auricularis, herpes facialis, and herpes occipito-collaris) with facial palsy, and (3) herpes zoster in any of the zoster zones with facial palsy and auditory symptoms (tinnitus, deafness, vertigo, vomiting, nystagmus, and disturbance of equilibrium).

Herpes zoster auricularis is the simplest form of the three. After a prodrome, the skin of the ear can become red and swollen, until on the third or fourth day, typical patches of herpetic vesicles make their appearances in the concha and on the lobule, the tragus, the auditory canal, and rarely, the tympanic membrane itself. Herpes zoster with facial palsy manifests itself with typical herpes zoster in the head and neck region with facial palsy (the second category). The last category of the Ramsay Hunt syndrome is herpes zoster in the head and neck region with facial palsy and auditory symptoms. Disturbances of equilibrium, vertigo, nausea, vomiting, and nystagmus were described. In the course of a few weeks, acute symptoms such as vertigo, gait disturbance, and dysequilibrium disappear, but tinnitus often persists for a considerable time, and hearing can be permanently impaired, as was the case with our patient.

Even though Ramsay Hunt suggested the syndrome can be divided in three clinical groups, it is obvious that different combinations of the clinical findings can exist in patients with the Ramsay Hunt syndrome. Our patient is unique in that he had an ipsilateral facial palsy 4 months before the development of the classic zoster eruption in the right ear and symptoms of eighth cranial nerve involvement. Although our patient had classic symptoms of eighth cranial nerve involvement, the MRI did not show any abnormality of the eighth cranial nerve. Tada and others² reported that of 7 patients with cochlear or vestibular symptoms, only 1 patient showed abnormal enhancement of the eighth cranial nerve in addition to seventh cranial nerve enhancement. This finding suggests that clinical symptoms of eighth cranial nerve involvement do not always correlate with MRI findings.

The facial nerve (the seventh cranial nerve) has two parts, a facial nerve proper and adjacent nerve root (the intermediate nerve, or the intermediate root of the facial nerve). The geniculate ganglion is the center of the sensory function of the facial nerve. It contains cell bodies of all afferent fibers. Because the geniculate ganglion is involved in the

Ramsay Hunt syndrome, patients can have variable symptoms and signs of the general visceral afferent, special visceral afferent, and general somatic afferent components of the facial nerve.

Treatment of Ramsay Hunt syndrome follows the general treatment goal of varicella zoster virus infection. In the normal host, the primary goal of treatment is to reduce acute pain and postherpetic neuralgia. Clinical trials show that treatment within the first 72 hours is beneficial.³ Several controlled studies verified that high-dose oral acyclovir speeds resolution of the acute lesional events and seems to reduce the risk of prolonged pain.^{4,5} Recent studies showed valacyclovir to be more convenient than and slightly superior to acyclovir.⁶ Famciclovir is also more convenient and is comparable, if not superior, to acyclovir.⁷ The choice among these three drugs should be based on convenience, availability, and cost. For the immunocompromised host, intravenous acyclovir has been shown to prevent disease progression in patients at high risk for dissemination.⁸ For mildly to moderately immunocompromised persons, however, oral valacyclovir or famciclovir might be acceptable alternatives to intravenous treatment. A study by Wood and others⁹ showed no long-term benefit when corticosteroids were added to an acyclovir regimen.

There have been 5 reported cases of Ramsay Hunt syndrome in patients with HIV infection in the literature up to 2000.¹⁰⁻¹³ All patients were in their 20s or 30s. Herpes zoster is often the first clinical manifestation of HIV infection.¹⁴ As many more family physicians take care of patients with HIV infection, Ramsay Hunt syndrome might be seen more frequently by them.

References

- Hunt JR. On herpetic inflammation of the geniculate ganglion and its complications. *J Nerv Ment Dis* 1907;34:73-96.
- Tada Y, Aoyagi M, Tojima H, et al. Gd-DTPA enhanced MRI in Ramsay Hunt syndrome. *Acta Otolaryngol Suppl* 1994;511:170-4.
- Wood MJ, Shukla S, Fiddian AP, Crooks RJ. Treatment of acute herpes zoster: effect of early (<48 h) versus late (48-72 h) therapy with acyclovir and valacyclovir on prolonged pain. *J Infect Dis* 1998; 178(Suppl 1):S81-4.
- Liesegang TJ. Diagnosis and therapy of herpes zoster ophthalmicus. *Ophthalmology* 1991;98:1216-29.
- McKendrick MW, McGill JL, White JE, Wood MJ. Oral acyclovir in acute herpes zoster. *Br Med J (Clin Res Ed)* 1986;293:1529-32.
- Beutner KR, Friedman DJ, Forszpaniak C, Andersen PL, Wood MJ. Valacyclovir compared with acyclovir for improved therapy for herpes zoster in immunocompetent adults. *Antimicrob Agents Chemother* 1995;39:1546-53.
- Tyring S, Barbarash RA, Nahlik JE, et al. Famciclovir for the treatment of acute herpes zoster: effects on acute disease and postherpetic neuralgia. A randomized, double-blind, placebo-controlled trial. Collaborative Famciclovir Herpes Zoster Study Group. *Ann Intern Med* 1995;123:89-96.
- Shepp DH, Dandliker PS, Meyer JD. Treatment of varicella-zoster virus infection in severely immunocompromised patients. A randomized comparison of acyclovir and vidarabine. *N Engl J Med* 1986;314: 208-12.
- Wood MJ, Johnson RW, McKendrick MW, Taylor J, Mandal BK, Crooks J. A randomized trial of acyclovir for 7 days or 21 days with and without prednisone for treatment of acute herpes zoster. *N Engl J Med* 1994;330:896-900.
- Li J, Xiong L, Jinkins JR. Gadolinium-enhanced MRI in a patient with AIDS and the Ramsay-Hunt syndrome. *Neuroradiology* 1993;35:269.
- Mishell JH, Applebaum EL. Ramsay-Hunt syndrome in a patient with HIV infection. *Otolaryngol Head Neck Surg* 1990;102:177-9.
- Mansour AM, Bailey BJ. Ocular findings in Ramsay Hunt syndrome. *J Neuroophthalmol* 1997;17:199-201.
- Johnson KB, Blazes DL, Keith M, Decker CF, Ohl CA. Ramsay Hunt syndrome in a patient infected with human immunodeficiency virus. *Clin Infect Dis* 1996;22:1128-9.
- Wilkerson MG, Jordan WP, Kerkering TM. Herpes zoster as a sign of AIDS-related complex. *Am Fam Physician* 1987;36:233-5.