

Toothpaste Allergy With Intractable Perioral Rash in a 10-year old Boy

Kathryn E. H. Reilly, MD, MPH, and Laine H. McCarthy, MLIS

Allergic reactions and contact dermatitis caused by the ingredients in toothpaste have been reported.¹ Some studies have documented allergic reactions to the flavorings used, especially cinnamic aldehyde.^{2,3} Others have reported skin reactions to the preservatives, especially sodium benzoate,⁴⁻⁶ and to aluminum.⁷ Still others have shown contact dermatitis caused by sodium lauryl sulfate and propylene glycol, both common ingredients in every commercial toothpaste brand, even the all-natural brands.⁸ Allergy to toothpaste ingredients is considered rare, but its rarity might be because it is hard to diagnose. Treatment options are linked to the symptom (the rash) as opposed to the cause (the allergen). Oral antibiotics and metronidazole have been prescribed for children with perioral rash.⁹ We report here a case of an intractable perioral rash of long duration that we eventually determined to be allergy to toothpaste.

Case Report

A 10-year-old boy complained to his family physician of rash around his mouth for approximately 4 years. The rash always had the same progression, beginning at the corners of the mouth and erupting downward in a distinctive pattern toward the chin and then across the chin under the lip (Figure 1 and Figure 2). If left untreated, the rash spread up into the perinasal folds and became very painful.

Upon initial presentation, the rash was thought to be impetigo, although it lacked the blistering that usually accompanies impetigo. Cefadroxil, 250 mg twice a day for 7 days, was prescribed. When the rash did not resolve, the boy returned. Next, his rash was diagnosed as contact dermatitis of unknown origin and was treated with a 1% cortico-

steroid cream. The rash resolved within 2 to 3 days but returned within 2 to 3 days if treatment with the cream was discontinued. The pattern of eruption and treatment with topical corticosteroids continued for 3 years. The parents even reported using the cream prophylactically to prevent the rash from recurring.

After nearly 4 years of repeated rash eruption, treatment with corticosteroid cream, and recurrence, the boy's parents expressed concern about applying the cream to their son's face and frustration with the long duration of the problem. They asked for a referral to a dermatologist in the hopes of finding a permanent solution to the problem. The rash was allowed to develop for several days before examination by the dermatologist.

The dermatologist diagnosed the boy's rash as a simple case of perioral dermatitis, probably the result of a systemic bacterial infection caused by his saliva. A 3-week regime of oral antibiotics in combination with topical application of an antifungal cream mixed with the corticosteroid cream was prescribed. The dermatologist instructed the parents to continue applying the cream for the full 3 weeks even if the rash resolved. The dermatologist assured the parents that if the prescribed regimen was followed precisely, the boy's rash would not return.

The boy took the full course of antibiotics and applied the combination cream for 3 weeks; then stopped all treatment. The rash returned within 3 days of completion of the treatment. The parents reported following the prescribed treatment exactly and were very frustrated. The child was angry and tired of the entire process.

At this point, a literature search looking for possible causes of perioral dermatitis in children was performed.

Literature Search

A search of the MEDLINE database from 1966 to the present was conducted looking for answers to the clinical question, "What are the possible causes

Submitted, revised, 1 December 1998.

From the Department of Family and Preventive Medicine (KEHR, LHM), University of Oklahoma College of Medicine. Address reprint requests to Laine H. McCarthy, MLIS, Department of Family and Preventive Medicine, University of Oklahoma College of Medicine, 900 NE 10th St, Oklahoma City, OK 73104.

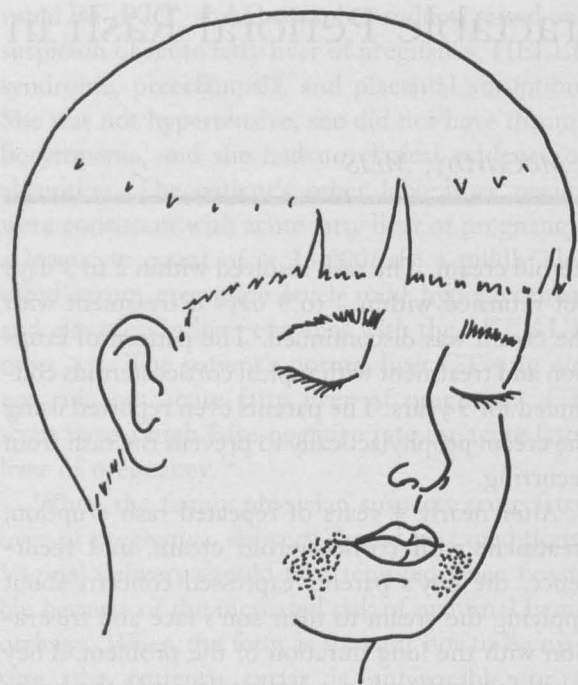


Figure 1. Rash pattern. Initially the rash erupts at the corners of the mouth and spreads downward in a distinctive flaring pattern. Left untreated, the rash progresses across the chin under the lower lip and eventually spreads upward from the corners of the mouth into the perinasal folds.

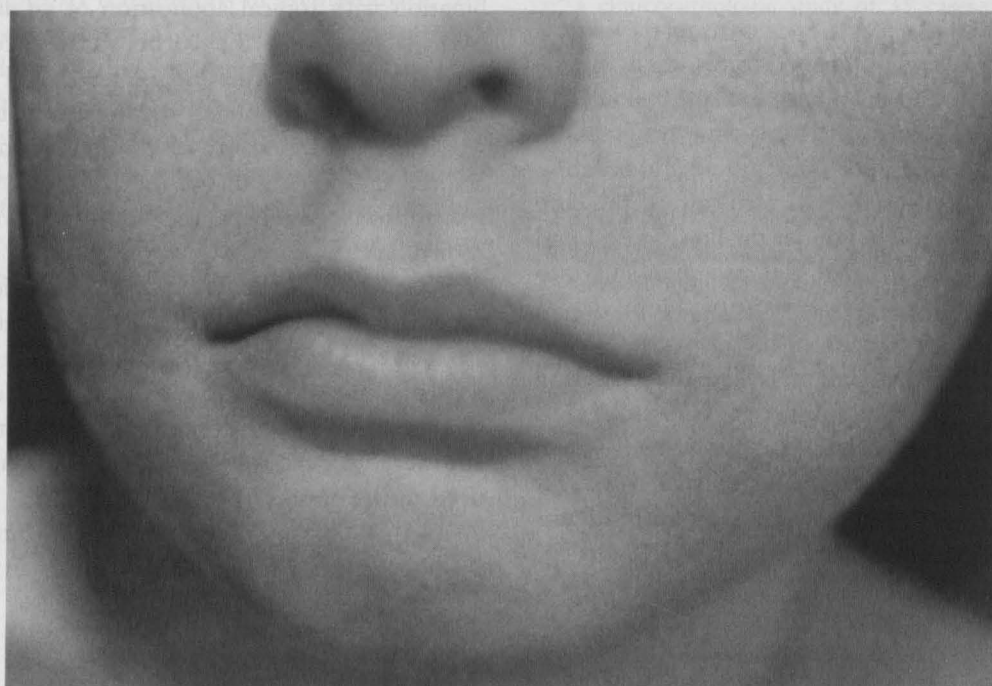

Figure 2. Photograph of perioral rash caused by toothpaste allergy. Initially the rash is red and slightly rough to the touch. Left untreated, the redness spreads and becomes painful and raw. The lack of blistering or pustules is important when considering possible toothpaste allergy.

of perioral dermatitis in a child?" The medical subject heading (MeSH) "dermatitis, perioral" yielded several studies describing the incidence of facial and perioral eruptions caused by allergic reaction to various ingredients in toothpaste.

Discussion

Given the background and pattern of the rash and the case history (the child began brushing his own teeth about the time the rash began), it seemed possible that this condition was a case of contact dermatitis caused by allergy to toothpaste. The easiest and least costly treatment approach in terms of time, dollars and disruption to the child and his family seemed to be a simple lifestyle change. The child was instructed to use less toothpaste (about a quarter inch), and to rinse his mouth and wash his face thoroughly after brushing. Topical corticosteroids were prescribed until the current rash resolved. The rash resolved within 3 days and the boy has remained free of rash for more than 18 months.

Had this approach not worked, the next step would have been to stop toothpaste altogether to rule out other causes of the rash. After a more than 4-year-long, continuous cycle of perioral eruption, treatment, and recurrence, however, the rash did

not return when the boy made this simple lifestyle change. To save the parents and the child further anguish, time, and money, we made no attempt to determine which ingredients in the toothpaste caused the boy's rash.

Recognizing allergy to toothpaste can be difficult and costly. In this case, several years elapsed before an appropriate diagnosis was reached and a treatment plan that worked for the child and his family was implemented. The child suffered disfigurement and pain, and the family bore the time and cost of repeated visits to the clinic and to a specialist before the problem was resolved. Since establishing the cause of the rash as toothpaste allergy in the boy, we have seen at least one other child with similar symptoms. Physicians who see a child with perioral rash of similar history and description should consider toothpaste allergy in their differential diagnosis.

References

1. Sainio EL, Kanerva L. Contact allergens in toothpastes and a review of their hypersensitivity. *Contact Dermatitis* 1995;33:100–5.
2. Romaguera C, Grimalt F. Sensitization to cinnamic aldehyde in toothpaste. *Contact Dermatitis* 1978;4:377–8.
3. Andersen KE. Contact allergy to toothpaste flavors. *Contact Dermatitis* 1978;4:195–8.
4. Machackova J, Smid P. Allergic contact cheilitis from toothpastes. *Contact Dermatitis* 1991;24:311–2.
5. Aguirre A, Izu R, Gardezabal J, Diaz-Perez JL. Edematous allergic contact cheilitis from a toothpaste. *Contact Dermatitis* 1993;28:42.
6. Munoz FJ, Bellido J, Moyano JC, Alvarez M, Fonseca JL. Perioral contact urticaria from sodium benzoate in a toothpaste. *Contact Dermatitis* 1996;35:51.
7. Veien NK, Hattel T, Laurberg G. Systematically aggravated contact dermatitis caused by aluminum in toothpaste. *Contact Dermatitis* 1993;28:199–200.
8. Skaare A, Kjaerheim V, Barkvoll P, Rolla G. Skin reactions and irritation potential of four commercial toothpastes. *Acta Odontol Scand* 1997;55:133–6.
9. Boeck K, Abeck D, Werfel S, Ring S. Perioral dermatitis in children—clinical presentation, pathogenesis-related factors and response to topical metronidazole. *Dermatology* 1997;195:235–8.