

Stridor in a 6-Week-Old Infant Caused by Right Aortic Arch With Aberrant Left Subclavian Artery

Leon McDougale, MD

Background: Persistent infant stridor, seal-like cough, and difficulty feeding can be the initial signs of right aortic arch with an aberrant left subclavian artery. This congenital cardiovascular abnormality results in the development of a vascular ring that encircles the trachea and esophagus.

Methods: A case report is presented that describes the evaluation and care of a 6-week-old male infant whose condition was diagnosed as right aortic arch and aberrant left subclavian artery after he was brought to the family practice clinic with a history of persistent stridor. This case report involved a patient seen in the author's outpatient clinic during a well-child check. Data were obtained from the patient's medical record and review of his radiologic diagnostic tests. MEDLINE and Index Medicus literature searches were conducted for the years 1966 to the present, using the key words "stridor" and "vascular ring," with cross-references for earlier articles.

Results and Conclusions: Persistent or recurrent stridor associated with feeding difficulties should prompt an investigation for a vascular ring. In general, an anteroposterior and lateral neck radiograph and a posteroanterior and lateral chest radiograph are usually the initial diagnostic tests to evaluate stridor. Persistent stridor and new-onset regurgitation of formula in a 6-week-old infant prompted an escalation of the patient's workup to include a barium swallow, which subsequently showed compression of the esophagus caused by a vascular ring. In some cases direct observation with a laryngoscope or bronchoscope might be necessary to determine the cause of stridor. Indications for hospitalization of patients with stridor include stridor at rest, dyspnea, actual or suspected epiglottitis, repeatedly awakening from sleep with stridor, a history of rapid progression of symptoms, toxic appearance, and apneic or cyanotic episodes. The primary care provider should be familiar with the evaluation and management for patients with the complaint of persistent or recurrent stridor. (J Am Board Fam Pract 1999;12:219-24.)

Stridor is a noise produced by the obstruction of air in any part of the upper respiratory tree. Persistent infant stridor, seal-like cough, and difficulty feeding can be the signs of right aortic arch with an aberrant left subclavian artery.¹ This congenital cardiovascular abnormality results in the development of a vascular ring that encircles the trachea and esophagus. The following case report describes the evaluation and care of a 6-week-old male infant who was found to have a right aortic arch and an aberrant left subclavian artery after being brought to the family practice clinic with a history of persistent stridor.

Methods

A case report is presented that describes the evaluation and care of a 6-week-old male infant whose condition was diagnosed as right aortic arch and aberrant left subclavian artery after he was brought to the family practice clinic with a history of persistent stridor. This case report involved a patient seen in the author's outpatient clinic during a well-child check. Data were obtained from the patient's medical record and review of his radiologic diagnostic tests. MEDLINE and Index Medicus literature searches were conducted for the years 1966 to the present, using the key words stridor and vascular ring with cross-references for earlier articles.

Case Report

The 6-week-old boy was born at 39 weeks' estimated gestational age by an uncomplicated spon-

Submitted, revised, 17 June 1998.

From the Department of Family Medicine, University of Michigan, Ypsilanti. Address reprint requests to Leon McDougale, Department of Family Medicine, University of Michigan, 200 Arnet St, Suite 200, Ypsilanti, MI 48198.

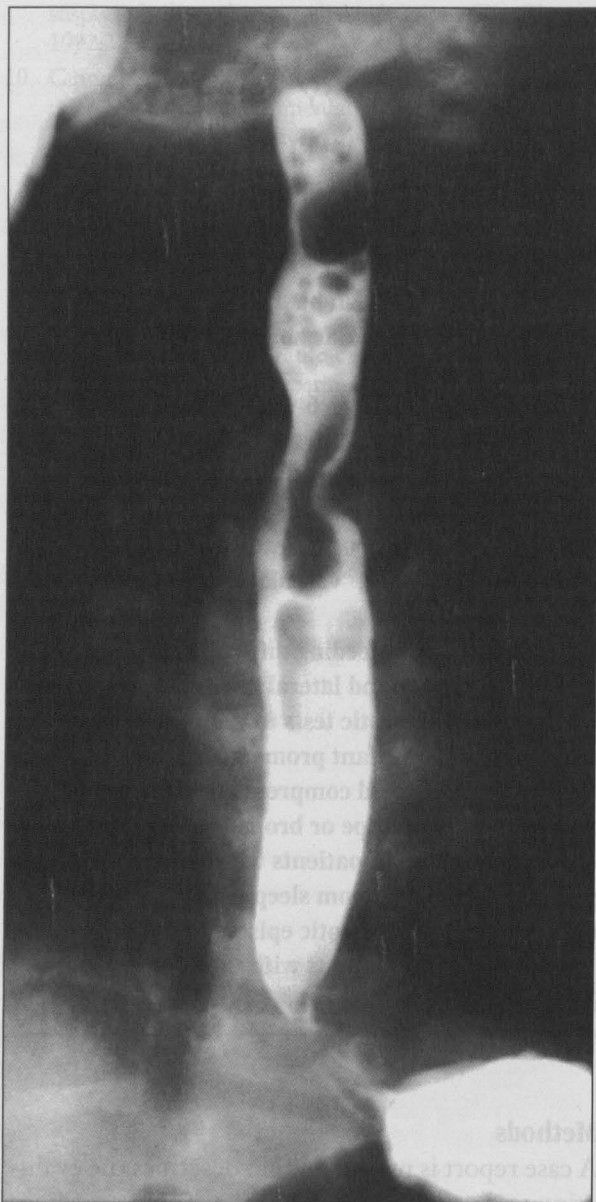


Figure 1. Image of right aortic arch with aberrant left subclavian artery in a 10-week-old infant. Esophagram shows indentation in right side of esophagus by right-sided aortic arch. On left side and caudal to indentation of right-sided aortic arch is another vascular indentation that represents the aberrant left subclavian artery.

taneous vaginal delivery with Apgar scores of 8 and 9 at 1 minute and 5 minutes, respectively. During the routine 6-week well-baby checkup, the mother complained that the infant had developed noisy inspiration and an occasional cough at about 2 weeks of age. The infant was afebrile and feeding well. He had a rectal temperature of 99.6°F and a respiratory rate of 40/min. Mild inspiratory stridor was noted when the infant cried, which did not

change when he was moved to a prone position. No drooling, retractions, or facial dysmorphic features were noted. He had a regular heart rate and rhythm without murmur, rub, or gallop, and his lungs were clear. The infant's height, weight, and head circumference were between the 50th to 55th percentile for age. Findings on the remainder of the physical examination were unremarkable. Findings on an anteroposterior and lateral neck radiographs, as well as a posteroanterior and lateral chest radiograph, were normal.

The infant was treated empirically for the possibility of early onset laryngotracheobronchitis (croup); the mother was instructed to obtain a bedside cool mist vaporizer, and a 5-day course of 2 mg/kg/d of methyl prednisolone was prescribed. A follow-up appointment was recommended in 1 week. The patient was brought to the clinic 4 weeks later, however, because his stridor had continued and had not improved. In addition, the mother stated that he was regurgitating some formula after feedings and had developed a clear runny nose. His respiratory rate was 34/min, and his temperature was 98.5°F; pulse oximetry showed 100 percent oxygen saturation on room air. Findings of the remainder of the examination were unchanged.

A pediatric pulmonologist, consulted by telephone, recommended that the child undergo a barium swallow. The esophagram showed an indentation in the right side of the esophagus that was caused by a right-sided aortic arch. On the left side and caudal to that indentation was another indentation, probably representing an aberrant left subclavian artery (Figure 1). The child subsequently underwent cardiac catheterization, which confirmed the diagnosis of right aortic arch with aberrant left subclavian artery. At 3 months of age he had a left thoracotomy for division of the ligamentum arteriosum. A preoperative bronchoscopy showed a diagnosis of segmental secondary tracheomalacia. There were no complications during the procedures, and the patient's stridor had resolved when seen on follow-up appointments.

Discussion

The incidence of right aortic arch with aberrant left subclavian artery is 1 in 2500 births.² According to Edwards' hypothetical scheme of the double aortic arch and bilateral ductus arteriosi,³ the formation of the vascular ring depends on the

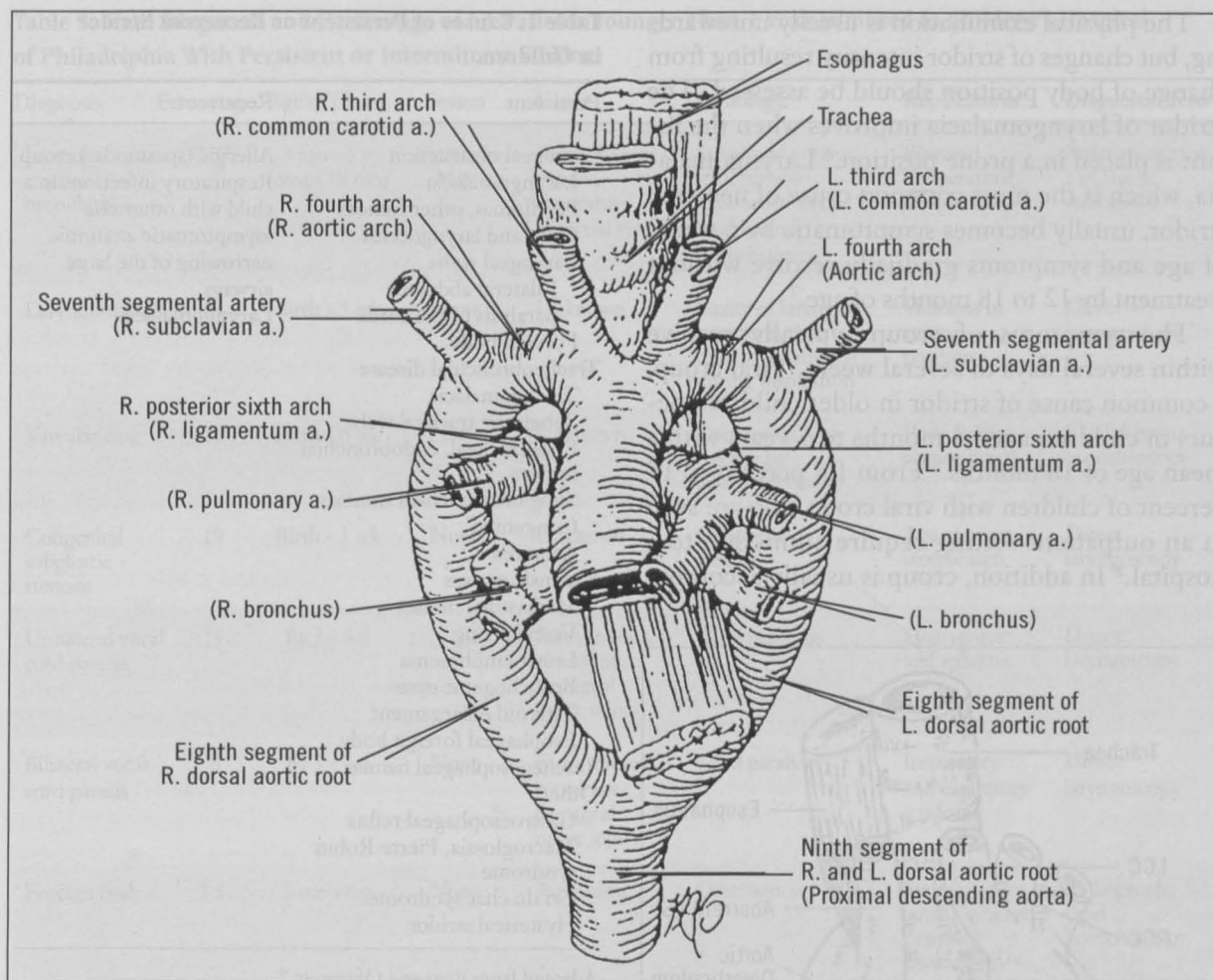


Figure 2. The embryonic aortic arch complex surrounding the trachea and the esophagus. Structures in the diagram labeled with embryonic names (with eventual names included in parenthesis). From Idriss FS: Vascular ring. In Raffensperger JG, editor. Swenson's pediatric surgery. Stamford, Conn: Appleton & Lange, 1990:690. Reprinted with permission.

preservation or deletion of specific segments of the rudimentary aortic arch complex (Figure 2). Involution of the right fourth arch normally occurs at day 36 to 38 in the 1-mm embryo, with persistence of the left fourth arch that leads to normal single left aortic arch anatomy. The right aortic arch with a retroesophageal left subclavian artery, however, results from persistence of the right fourth arch and deletion of the left between the carotid and subclavian arteries. The subclavian artery originates from the descending aorta and courses to the left behind the esophagus. The ligamentum extends from the descending aorta anterior to the left pulmonary artery completing the ring (Figure 3).^{3,4}

Persistent stridor, a seal-like cough, and difficulty feeding can be the initial signs of the resul-

tant vascular ring that encircles the trachea and esophagus. Apnea or cyanosis can be precipitated by swallowing a bolus of solid food that presses the soft posterior trachea within the restrictive confines of a ring.¹ A simple cold might precipitate severe respiratory difficulty. Recurrent pneumonia and frequent respiratory tract infection are not unusual. Dysphagia usually develops in older children. When patients are symptomatic, vascular rings should be repaired. A left thoracotomy in the fourth interspace is preferred for most vascular rings. The surgical risk is minimal, and the long-term results are excellent. It should be noted that complete relief of symptoms might not be noted immediately, and a period of a few months to 1 to 2 years can pass before the noisy respiration will disappear.^{1,5}

The physical examination is usually unrewarding, but changes of stridor intensity resulting from change of body position should be assessed. The stridor of laryngomalacia improves when the infant is placed in a prone position.⁶ Laryngomalacia, which is the most common cause of neonatal stridor, usually becomes symptomatic by 6 weeks of age and symptoms gradually resolve without treatment by 12 to 18 months of age.⁷

The symptoms of croup typically resolve within several days to several weeks. Viral croup, a common cause of stridor in older children, occurs in children aged 3 months to 5 years with a mean age of 18 months.⁸ From 1.5 percent to 15 percent of children with viral croup who are seen in an outpatient setting require admission to a hospital.⁸ In addition, croup is usually accompa-

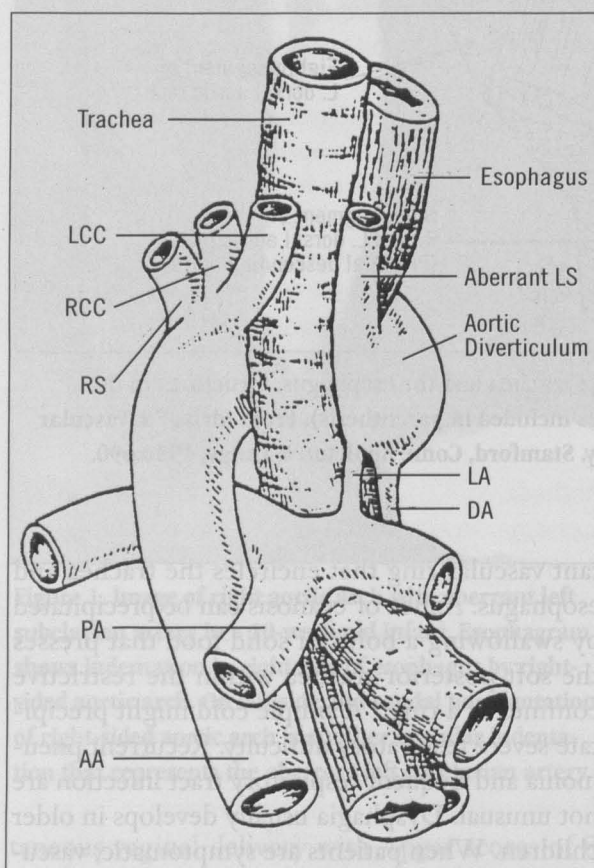


Figure 3. Diagram of right aortic arch with aberrant left subclavian artery and left esophageal indentations. The aortic diverticulum indents the posterolateral aspect of the esophagus.

AA - ascending aorta, DA - descending aorta, LA - ligamentum arteriosum, LCC - left common carotid artery, LS - left subclavian artery, PA - pulmonary artery, RCC - right common carotid artery, RS - right subclavian artery

Table 1. Causes of Persistent or Recurrent Stridor in Children.

Persistent	Recurrent
Laryngeal obstruction	Allergic (spasmodic) croup
Laryngomalacia	Respiratory infections in a child with otherwise asymptomatic anatomic narrowing of the large airways
Papillomas, other tumors	Laryngomalacia
Cysts and laryngoceles	
Laryngeal webs	
Bilateral abductor paralysis of the cords	
Foreign body	
Tracheobronchial disease	
Tracheomalacia	
Subglottic tracheal webs	
Endotracheal, endobronchial tumors	
Subglottic tracheal stenosis	
Congenital	
Acquired	
Extrinsic masses	
Mediastinal masses	
Vascular ring	
Lobar emphysema	
Bronchogenic cysts	
Thyroid enlargement	
Esophageal foreign body	
Tracheoesophageal fistulas	
Other	
Gastroesophageal reflux	
Macroglossia, Pierre Robin syndrome	
Cri du chat syndrome	
Hysterical stridor	

Adapted from Boat and Orenstein.⁹

nied by a seal-like cough and temperature elevation, and the anteroposterior radiographic findings of the neck can show subglottic narrowing (steep sign).

The differential diagnosis of persistent or recurrent stridor in children is extensive (Table 1).⁹ Children's Hospital of Philadelphia listed the final diagnosis of children who were younger than 1 year and admitted to the hospital because of persistent or intermittent stridor. In all of their cases, the initial stridor began before the age of 7 months (Table 2).¹⁰

Of the 63 patients admitted for persistent or intermittent stridor, one case of each of the following diagnoses was seen: laryngotracheobronchitis-subglottic mass, foreign body, Pierre Robin syndrome, tracheolaryngoesophageal cleft, aryepiglottic fold cyst, laryngeal mass (not biopsied), subglottic stenosis with tracheoesophageal fistula, and postintubation vocal cord granuloma. It is important to note, however, that Table 2 shows the

Table 2. Final Diagnosis and Percentage of 63 Patients Younger Than 1 Year Admitted to Children's Hospital of Philadelphia With Persistent or Intermittent Stridor.

Diagnosis	Percentage*	Age of Onset	Season	Cause	Pathology	Key Features	Diagnostic Tests
Laryngo-tracheo-bronchitis	1.5 [†]	3 mo - 5 y (mean 18 mo)	October - May	Parainfluenza viruses, respiratory syncytial virus	Subglottic edema with variable inflammation of trachea and bronchial tree	Elevated temperature, steeple sign	Anteroposterior and lateral radiograph
Laryngomalacia	14	Birth - 3 wk	None	Unknown	Laxity of laryngeal structures that tend to fall inward during inspiration	Worsens in supine position	Direct laryngoscopy
Vascular ring	11	Birth - 6 wk	None	Unknown	Compression of trachea by abnormal vessels	Poor feeding, regurgitation	Esophagram, bronchoscopy
Congenital subglottic stenosis	19	Birth - 3 wk	None	Unknown	Subglottic stenosis	Age of onset, steeple sign	Direct laryngoscopy
Unilateral vocal cord paresis	14	By 3 - 4 d	None	Birth trauma, recurrent laryngeal nerve injury	Cord paralysis	Hoarseness and aphonia	Direct laryngoscopy
Bilateral vocal cord paresis	6	By 3 - 4 d	None	Birth trauma, recurrent laryngeal nerve injury	Cord paralysis	Inspiratory and expiratory stridor	Direct laryngoscopy
Foreign body	1.5	3 mo - 6 y	None	Aspiration	Obstruction	Sudden-onset cough, wheeze, cyanosis, choking	Radiograph, rigid bronchoscopy

Adapted from Quinn-Bogard and Potsic.¹⁰

*Relative incidence of patients < 1 y with persistent or intermittent stridor admitted to Children's Hospital of Philadelphia, 1971-76.

[†]This case was also complicated by a subglottic mass.

percentage of diagnoses in hospitalized patients, which is undoubtedly different from the frequency found in unselected infants seen in the office setting.

Conclusions

The findings of persistent stridor and new-onset regurgitation of formula prompted an escalation of the patient's workup to include a barium swallow, which subsequently showed compression of the esophagus caused by a vascular ring. In general, an anteroposterior and lateral neck radiograph and a posteroanterior and lateral chest radiograph are usually the initial diagnostic tests. Direct observation with a laryngoscope or bronchoscope or evaluation with a barium swallow might be necessary, however, to determine the cause of stridor, as noted in Table 2.^{10,11} Persistent or recurrent stridor associated with feeding diffi-

culties should prompt a search for a vascular ring. Indications for hospitalization of patients with stridor include stridor at rest, dyspnea, actual or suspected epiglottitis, repeatedly awakening from sleep with stridor, a history of rapid progression of symptoms, toxic appearance, and apneic or cyanotic episodes.¹² The primary care provider should be familiar with the evaluation and management for patients with the complaint of persistent or recurrent stridor.

References

1. Backer CL, Idriss FS. Tracheoesophageal compressive syndromes of vascular origin: Rings and slings. In Baue A, editor. Glenn's thoracic and cardiovascular surgery. 5th ed. Vol 2. Stamford, Conn: Appleton & Lange, 1990:963-70.
2. Dahnert W, Dahnert WF. Radiology review manual. 2nd ed. Baltimore: Williams & Wilkins, 1993:363.
3. Edwards JE. Anomalies of the derivatives of the aortic

- arch system. *Med Clin North Am* 1948;32:925-49.
4. Kleinman PK, Spevak MR, Nimkin K. Left-sided esophageal indentation in right aortic arch with aberrant left subclavian artery. *Radiology* 1994;191:565-7.
5. van Son JA, Julsrud PR, Hagler DJ, Sim EK, Pairolero PC, Puga FJ, et al. Surgical treatment of vascular rings: the Mayo Clinic experience. *Mayo Clin Proc* 1993;68:1056-63.
6. Handler SD. Stridor. In Fleisher GR, Ludwig S, editors. *Textbook of pediatric emergency medicine*. Baltimore: Williams & Wilkins, 1983:243-5.
7. McGill TJ, Healy GB. Congenital and acquired lesions of the infant larynx. A refresher survey. *Clin Pediatr Phila* 1978;17:584-9.
8. Skolnik NS. Treatment of croup. *Am J Dis Child* 1989;143:1045-9.
9. Boat TF, Orenstein DM. Chronic or recurrent respiratory symptoms. In Behrman RE, Kliegman RM, Arvin AM, Nelson WE, editors. *Nelson textbook of pediatrics*. 15th ed. Philadelphia: WB Saunders, 1996:1235-9.
10. Quinn-Bogard AL, Potsic WP. Stridor in the first year of life. The clinical evaluation of the persistent or intermittent noisy breather. *Clin Pediatr Phila* 1977;16:913-9.
11. Cressman WR, Myer CM 3rd. Diagnosis and management of croup and epiglottitis. *Pediatr Clin North Am* 1994;41:265-76.
12. Orenstein DM. Acute Inflammatory upper airway obstruction. In Behrman RE, Kliegman RM, Arvin AM, Nelson WE, editors. *Nelson textbook of pediatrics*. 15th ed. Philadelphia: WB Saunders, 1996:1203-4.