

# Cervical Pregnancy— A Forgotten Entity in Family Practice

David A. Acosta, MD

**Background:** Cervical pregnancy is a rare form of ectopic pregnancy that is associated with considerable maternal morbidity and a high mortality rate if early diagnosis and treatment are not carried out in a timely fashion.

**Methods:** The current medical literature was reviewed by searching MEDLINE files from 1985 to 1996, using the key words "ectopic pregnancy" and "cervical pregnancy." Older articles were accessed from cross-reference of the more recent publications.

**Results:** The incidence of cervical pregnancy is 1 in 2400 deliveries and represents less than 1.0 percent of all ectopic pregnancies. No clear cause of cervical pregnancy has been described, and criteria for the clinical, pathologic, and sonographic diagnosis have been well established. The most common clinical complaint is painless vaginal bleeding. Routine transvaginal sonography early on allows for conservative management and avoids adverse outcomes. Methotrexate administered systemically and by intra-amniotic instillation are the therapeutic options of choice. Gestational age and the presence or absence of fetal cardiac activity are major prognostic factors for its success.

**Conclusion:** Earlier diagnosis of cervical pregnancy using sonography and conservative management of this condition have reduced considerably the morbidity and mortality associated with this rare form of ectopic pregnancy and have helped preserve a woman's future fertility. (J Am Board Fam Pract 1997;10:290-95.)

Cervical pregnancy is a rare form of ectopic pregnancy, yet it is a devastating condition when encountered, and all physicians practicing obstetrics should have some awareness regarding this problem. It is interesting that in a review of the literature on this subject, cervical pregnancy has never been reported in any of the family practice literature. As a family physician who has been practicing obstetrics for the past 14 years, I have delivered more than 1000 babies. The following is a report of the single case of cervical pregnancy that I encountered; it is one case that I will never forget.

## Methods

A case of a young woman who had a cervical pregnancy and survived using conservative treatment is described. The current medical literature

was reviewed by searching MEDLINE files from 1985 to 1996, using key words "ectopic pregnancy" and "cervical pregnancy" to investigate the possible causes and management of this rare form of ectopic pregnancy. Older articles were accessed from cross-reference of the more recent publications. Interestingly, the search did not yield any findings on this subject from any of the published family practice literature.

## Case Report

A 39-year-old woman, gravida 4, para 1, aborta 2, came to the emergency department with painless vaginal bleeding 20 days before admission. The patient's serum  $\beta$ -human chorionic gonadotropin ( $\beta$ -hCG) was 6622 mIU/mL, but a transabdominal sonogram did not reveal any products of conception within the uterine cavity. The emergency department physician made a presumed diagnosis of a completed abortion, and the patient was sent home with instructions for outpatient follow-up in 2 to 3 days. Her discharge hematocrit was 38.5 percent. When she was seen 3 days later, her only complaint was mild weakness and a

Submitted, revised, 27 February 1997.

From the Tacoma Family Medicine Family Practice Residency, Tacoma, and the Department of Family Medicine, University of Washington, Seattle. Address reprint requests to David A. Acosta, MD, 521 Martin Luther King Jr. Way, Tacoma, WA 98405-4238.

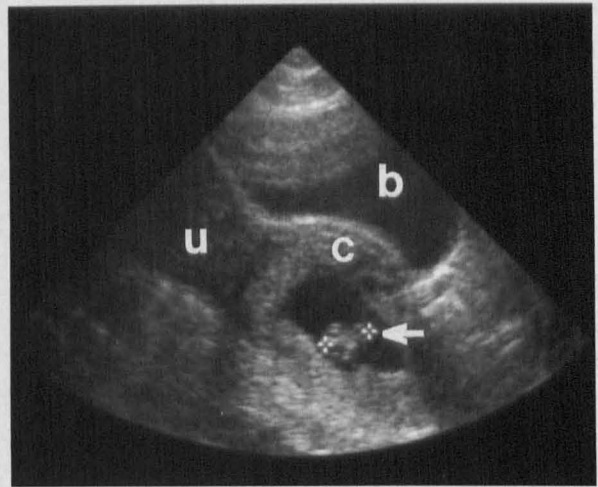
small amount of vaginal spotting with a brownish discharge. She denied any active vaginal bleeding. At that time her  $\beta$ -hCG was 14,580 mIU/mL. A second transabdominal sonogram showed a 4-mm yolk sac embedded in the proximal portion of the endocervical canal. Cardiac activity was seen. The patient adamantly refused any medical or surgical intervention because of her strong desire to continue with this pregnancy (the patient had been infertile since her last pregnancy 11 years earlier).

On the day of admission, she again complained of painless vaginal bleeding. She claimed to have soaked six pads in 1 hour and had passed some clots 1 day earlier, but did not notice any tissue that might have passed. She denied fever, chills, sweats, or any history of dizziness. Her medical history was notable for two spontaneous miscarriages, each followed with dilatation and curettage, and one primary cesarean section delivery 11 years earlier for failure to progress. Otherwise, she had no other important illnesses. The patient was very interested in bringing this pregnancy to term, if possible, and in preserving her future fertility.

On examination, she was not in any acute distress. Findings of the abdominal examination were normal. On a sterile speculum examination, the cervix appeared ballooned out and boggy, approximately 0.5-cm dilated, with a clot extruding out of the os. There was a small amount of dark blood in the vaginal vault. No products of conception were seen. On a bimanual examination her uterus was nontender to palpation and of normal contour, and its size was consistent with a 14- to 16-week gestation. No masses were felt in the adnexa or in the cul-de-sac. She was admitted for further care.

The patient's hematocrit was 29.4 percent on admission, a drop of 8.6 percent from her hematocrit measurement 3 weeks earlier. The  $\beta$ -hCG measurement was not repeated. A transabdominal sonogram confirmed an 8-week gestational sac located in the proximal posterior portion of the cervix (Figure 1). Cardiac activity was evident. There was a large amount of fluid within the uterine cavity, but fetal parts were not seen within the uterine cavity, and no free fluid was seen in the cul-de-sac. A diagnosis of a cervical pregnancy was made, and an obstetrician was consulted.

Because of her history of recurrent sponta-



**Figure 1.** Transabdominal sonogram showing an intracervical pregnancy at 8.1 weeks gestation. **b** - bladder, **c** - cervix, **u** - uterus, white arrow - fetal pole within gestational sac.

neous bleeding, the large amount of fluid (presumably blood) accumulating in her uterine cavity, and the drop in her hematocrit, the decision was made to take the patient to the operating room. A dilatation and suction curettage was performed and, as expected, there was profuse bleeding. Initial measures to control the bleeding included intravenous methergine, followed by vaginouterine massage and compression. Subsequently, the descending branches of the uterine arteries were ligated with 2-0 chromic sutures, but without much success in controlling the bleeding. A 36-French Foley catheter was then inserted into the endocervical canal, and 30 cc of saline were instilled into the catheter balloon. Tamponade was successfully achieved.

The interoperative blood loss was estimated to be 500 cc. Her immediate postoperative hematocrit was 25.5 percent. She continued to have mild oozing intermittently during the next 6 hours, with a subsequent drop in her hematocrit to 21.2 percent. She received 2 units of packed red blood cells. The Foley catheter was deflated and removed completely approximately 13 hours after the initial procedure. There were no signs of bleeding. The rest of her postoperative course was uneventful, and she was discharged on the second postoperative day with a hematocrit of 26 percent.

When the patient was seen in clinic 1 day and 1 week after discharge, she had no clinical evidence of bleeding on examination. At 2 weeks she still

**Table 1. Clinical Diagnostic Criteria for Cervical Pregnancy.**

---

Closed internal cervical os
History of painless uterine bleeding after amenorrhea (presumptive pregnancy)
Partially open external cervical os
Products of conception are entirely confined within the endocervix
Softened and disproportionately enlarged cervix palpably equal to or larger than the uterus

---

Derived from Yankowitz et al.<sup>2</sup>

had no further bleeding, and her uterus had reverted back to its normal size. At her 1-month follow-up visit, results of her examination were normal, and her  $\beta$ -hCG had decreased to 50 mIU/mL. She was counseled to avoid pregnancy for at least 3 to 6 months.

## Discussion

### Incidence

Cervical pregnancy is a rare form of ectopic pregnancy that can be associated with serious maternal morbidity and a high mortality rate. In earlier studies mortality rates were reported to be between 40 to 45 percent,<sup>1</sup> but recent reports suggest that the mortality rate has decreased considerably. That no maternal deaths have been reported since 1953<sup>1</sup> is believed to be the result of earlier diagnosis by sonography and the earlier utilization of conservative management. The reported incidence of cervical pregnancy has been variable but has been estimated to range from 1 in 1000 to 1 in 18,000 deliveries.<sup>2</sup> Generally, it is considered to occur at a rate of at least 1 in 2400 deliveries and represents less than 1.0 percent of all ectopic pregnancies.<sup>1</sup>

### Etiology

There is no clear explanation for cervical pregnancy, although several contributing factors have been proposed: (1) induced abortion with sharp curettage,<sup>3</sup> (2) intrauterine devices,<sup>4</sup> (3) Asherman syndrome (severe intrauterine adhesions secondary to uterine curettage),<sup>4</sup> (4) cesarean section,<sup>4</sup> (5) structural uterine and cervical anomalies,<sup>5</sup> (6) uterine fibroids and malformations,<sup>6</sup> (7) endometrial atrophy and chronic endometritis,<sup>7</sup> and (8) abnormal transport and secondary attachment of the fertilized ovum.<sup>8,9</sup>

### Diagnosis

Cervical pregnancy is defined as the implantation of a fertilized ovum in the endocervix. The following are accepted pathologic criteria for making a diagnosis of cervical pregnancy: (1) the cervical glands must be opposite the placental attachment, (2) the attachment of the placenta to the cervix must be intimate, (3) the placenta must be below the peritoneal reflection of the anterior and posterior surfaces of the uterus, and (4) fetal elements must not be found within the uterine cavity.<sup>2</sup> Because these criteria are based on pathologic specimens, however, other more clinically useful criteria have been established for the diagnosis of cervical pregnancy (Table 1).

The most common clinical manifestation is painless vaginal bleeding, which most studies show almost always occurs in the first trimester, although there have been reports of vaginal bleeding occurring even as late as 19 weeks' gestation.<sup>10</sup> The differential diagnosis includes an inevitable, incomplete, or complete abortion; cervical neoplasia; advanced fundal malignancy; degenerative cervical leiomyoma; trophoblastic tumor; or a low-lying placenta and placenta previa.<sup>11</sup> The clinical criteria for the diagnosis of cervical pregnancy that have been established include (1) a history of uterine bleeding after amenorrhea without cramping pain (presumptive pregnancy), (2) a softened and disproportionately enlarged cervix that appears to be equal to or larger than the palpable position of the uterus, (3) the products of conception being entirely confined within and firmly attached to the endocervix, (4) a snug internal os, (5) a partially open external os.<sup>2</sup>

The initial examination of the patient should include a complete blood count, a quantitative  $\beta$ -hCG titer, and blood typing and screening. The quantitative  $\beta$ -hCG along with findings from a transvaginal or transabdominal sonogram will help estimate the gestational age, which in turn will help in the decision making for the most appropriate treatment. The routine use of sonography has made it possible to diagnose cervical pregnancy much earlier, which gives the physician the option of conservative management.

The accepted sonographic (transabdominal) criteria for the diagnosis of cervical pregnancy are well established (Table 2).<sup>12</sup> Timor-Tritsch et al<sup>13</sup> recently proposed a new set of criteria specific for

transvaginal sonographic examinations: (1) the placenta and the entire chorionic sac containing a live fetus should be below the internal os (they locate the internal os at the level of the insertion of the uterine arteries), (2) the uterine cavity should be empty, and (3) the cervical canal should be barrel-shaped and noticeably dilated. Rosenberg and Williamson<sup>14</sup> further suggest that duplex Doppler scanning of the lower uterine segment be considered if no gestational sac is seen within the cervical canal on a sonogram during the initial evaluation. Finding trophoblastic-type blood flow and marked vascularity would suggest cervical pregnancy.

### Management

Treatment of cervical pregnancy has changed dramatically since it was first reported. Historically, most diagnoses of cervical pregnancy were made at the time of surgical instrumentation of the cervix, unfortunately resulting in profuse hemorrhage, shock, and an emergency hysterectomy. The diagnosis is now generally made before the onset of complications, and with the experience of nonsurgical treatment of tubal ectopic pregnancies, conservative management has become the therapeutic choice. This approach becomes especially important for those patients who wish to preserve their childbearing capacity.

Conservative management can be both surgical and nonsurgical. Reported options include (1) local excision and curettage<sup>15</sup>; (2) curettage, vaginobdominal compression of the cervix or uterus, and tamponade with packing<sup>10</sup>; (3) cervical cerclage<sup>16</sup>; (4) curettage and tamponade with Foley catheter placed into the cervical canal<sup>17,18</sup>; (5) ligation of the descending branches of the uterine artery and curettage<sup>19</sup>; (6) preoperative angiographic uterine artery embolization prior to curettage<sup>20</sup>; (7) methotrexate administered systemically<sup>21-25</sup>; (8) potassium chloride administered by intra-amniotic injection<sup>26</sup>; and (9) methotrexate administered by intra-amniotic instillation.<sup>1,27,28</sup> Even with conservative management, the potential remains for hemorrhage, shock, and the possibility of an emergency abdominal hysterectomy.<sup>29</sup>

Because of the reported successes with methotrexate when treating tubal ectopic pregnancies and other trophoblastic diseases, more attention has been drawn to the use of chemotherapeutic

**Table 2. Diagnostic Criteria by Sonography (Transabdominal) for Cervical Pregnancy.**

Absence of intrauterine pregnancy
Diffuse amorphous intrauterine echoes
Enlarged cervix
Uterine enlargement

Derived from Kobayashi et al.<sup>12</sup>

agents in the treatment of cervical pregnancy. Methotrexate has been used systemically in the same dosing regimen as for tubal ectopic pregnancies with some success (1 mg/kg intramuscularly on day 1, 3, 5, and 7, followed with folinic acid rescue, 0.1 mg/kg, on day 2, 4, 6, and 8), but there have been serious side effects associated with its use: stomatitis, pharyngitis, gastritis, transient elevation of liver function tests, and transient bone marrow suppression. Two case studies have even reported good results with etoposide<sup>30</sup> and actinomycin-D<sup>31</sup> administered systemically. Unfortunately, there were major side effects associated with these agents: severe global alopecia and bone marrow suppression with etoposide; nausea, vomiting, and skin and subcutaneous tissue necrosis with actinomycin-D.

Recently several authors have reported success with methotrexate instilled directly into the amniotic sac using transvaginal sonographic guidance.<sup>1,27,28</sup> The procedure entails using sonography to guide a needle through the anterior cervical wall into the amniotic sac. Both the transvaginal and transabdominal approaches have been described as successful. Entering the amniotic sac by means of the cervical canal has been reported to have led to the rupture of the amniotic sac with subsequent failure. Consequently, this technique has not been recommended. Two milliliters of 10 percent potassium chloride<sup>32</sup> are usually injected first into the amniotic sac to stop cardiac activity, aspiration follows, and then methotrexate (1 mg/kg body weight) is instilled directly into the amniotic sac. No side effects have been reported with methotrexate used in this manner, although considerable technical skill is required to perform this procedure. None of the patients who received this therapeutic option required curettage or a hysterectomy.

Not all cervical pregnancies have been successfully treated with methotrexate, however. There

appear to be two important factors that influence the success of treatment with methotrexate: gestational age at the time of treatment, and fetal cardiac activity. Mantalenakis et al<sup>28</sup> suggest that methotrexate therapy is most successful for cervical pregnancies of less than 9 weeks' gestation. He also suggests that cardiac activity is an important prognostic factor. If cardiac activity is absent before treatment, intramuscular or intravenous administration of methotrexate can be effective. With fetal cardiac activity, however, this approach has been ineffective. Intramuscular administration of methotrexate, combined with intracervical or intra-amniotic injection, is considered to be more effective.

Serial serum  $\beta$ -hCG levels and sonographic findings can be used as markers for treatment effectiveness. The average time interval between treatment and the resolution of serum  $\beta$ -hCG levels ranges from 8 to 59 days.<sup>32</sup> If these markers have not indicated regression of the cervical pregnancy, conservative surgical treatment (eg, curettage) is recommended.

There are reports of subsequent pregnancies occurring after treatment of cervical pregnancy, some successfully going to term<sup>16,26</sup> and others resulting in spontaneous abortions.<sup>2</sup> Recently, Kaplan et al<sup>27</sup> and Mantalenakis et al<sup>28</sup> have each reported successful term pregnancies in women who have had a cervical pregnancy treated with intra-amniotic injection of methotrexate.

It is also unclear how long the patient should wait to conceive after having methotrexate therapy. Methotrexate has been reported to remain in human tissue for at least 8 months after being administered systemically.<sup>33</sup> There is no evidence in the literature suggesting that methotrexate used to treat trophoblastic disease is associated with an increased rate of congenital anomalies or spontaneous abortions in subsequent pregnancies. No study makes any recommendations regarding the timing of conception following the treatment with methotrexate.

The technique of administering methotrexate directly into the amniotic sac has several obvious advantages compared with administering methotrexate systemically. The technique has greater efficacy rates, shorter treatment intervals, and no serious side effects.<sup>1</sup> In any case, the overall benefit of conservative management strategies is preservation of the uterus and the woman's ferti-

ity, and they should be considered in every case.

Our case met both the clinical and the sonographic criteria for the diagnosis of cervical pregnancy. Possible causative factors that might have predisposed this patient to cervical pregnancy include two surgical curettages and one cesarean section delivery—both consistent with findings from previous studies. Several of the reported modes of conservative management were attempted in this case: curettage, ligation of the descending branches of the uterine arteries, vaginal-abdominal compression of the uterus, and finally, tamponade with the placement of a Foley catheter into the endocervix. Methotrexate therapy was not considered in this case because we had limited experience treating tubal ectopic pregnancies with this chemotherapeutic agent at our facility. Our patient would have been a likely candidate for methotrexate administered by intra-amniotic injection. We were still fortunate in this case to have avoided hysterectomy and to have preserved the patient's fertility. She has been cared for in the clinic for the last 5 years and unfortunately has not yet conceived.

### Conclusion

Cervical pregnancy is a rare but serious form of ectopic pregnancy that most family physicians who practice obstetrics have not witnessed or even considered. The key to successful management is early diagnosis using transvaginal sonography. Early diagnosis allows the physician to manage the pregnancy conservatively and to possibly avoid an emergency hysterectomy. Methotrexate, administered (with folinic acid) either systemically or by instillation into the amniotic sac, has been shown to be an excellent alternative to surgery. Preserving the patient's capacity to bear children is a goal that can be achieved by conservative management.

### References

1. Marcovici I, Rosenzweig BA, Brill AI, Khan M, Scommegna A. Cervical pregnancy: case reports and a current literature review. *Obstet Gynecol Surv* 1994;49:49-55.
2. Yankowitz J, Leake J, Huggins G, Gazaway P, Gates E. Cervical ectopic pregnancy: review of the literature and report of a case treated by single-dose methotrexate therapy. *Obstet Gynecol Surv* 1990; 45:405-14.
3. Shinagawa S, Nagayama M. Cervical pregnancy as a

- possible sequela of induced abortion. Report of 19 cases. *Am J Obstet Gynecol* 1969;105:282-4.
4. Dicker D, Feldberg D, Samuel N, Goldman JA. Etiology of cervical pregnancy: association with abortion, pelvic pathology, IUDs and Asherman's syndrome. *J Reprod Med* 1985;30:25-7.
  5. Mieszczerski J, Smielowski B, Dabrowski Z. [Use of hystero-graphy for confirmation of cervix pregnancy.] *Zentralbl Gynakol* 1971;93:483-90.
  6. Dees HC. Cervical pregnancy associated with uterine leiomyomas. *South Med J* 1966;59:900 passim.
  7. Fahmy K, Zikry AM, Hassan S. Cervical pregnancy. *Int Surg* 1971;55:127-30.
  8. Studdiford WE. Cervical pregnancy: a partial review of the literature and a report of two probable cases. *Am J Obstet Gynecol* 1945;49:169.
  9. Iffy I. Contribution to the etiology of ectopic pregnancy. *Obstet Gynaecol Br Commonwlt* 1961;8:441.
  10. ten Kate-Booij MJ, Wallenburg HC. Conservative treatment of postpartum hemorrhage in a second-trimester cervical pregnancy. *Am J Obstet Gynecol* 1984;150:103-4.
  11. Parente JT, Ou CS, Levy J, Legatt E. Cervical pregnancy analysis: a review and report of five cases. *Obstet Gynecol* 1983;62:79-82.
  12. Kobayashi M, Hellman LM, Fillisti LP. Ultrasound. An aid in the diagnosis of ectopic pregnancy. *Am J Obstet Gynecol* 1969;103:1131-40.
  13. Timor-Tritsch IE, Monteagudo A, Mandeville EO, Peisner DB, Anaya GP, Pirrone EC. Successful management of viable cervical pregnancy by local injection of methotrexate guided by transvaginal ultrasonography. *Am J Obstet Gynecol* 1994;170:737-9.
  14. Rosenberg RD, Williamson MR. Cervical ectopic pregnancy: avoiding pitfalls in the ultrasonographic diagnosis. *J Ultrasound Med* 1992;11:365-7.
  15. Farghaly SA, Mathie JG. Cervical pregnancy managed by local excision. *Postgrad Med J* 1980;56:789.
  16. Bachus KE, Stone D, Suh B, Thickman D. Conservative management of cervical pregnancy with subsequent fertility. *Am J Obstet Gynecol* 1990;162:450-1.
  17. Patchell RD. Cervical pregnancy managed by balloon tamponade. *Am J Obstet Gynecol* 1984;149:107.
  18. Nolan TE, Chandler PE, Hess LW, Morrison JC. Cervical pregnancy managed without hysterectomy: a case report. *J Reprod Med* 1989;34:241-3.
  19. Kuppawami N, Vindekilde J, Sethi CM, Seshadri M, Freese UE. Diagnosis and treatment of cervical pregnancy. *Obstet Gynecol* 1983;61:651-3.
  20. Lobel SM, Meyerovitz MF, Benson CC, Goff B, Bengtson JM. Preoperative angiographic uterine artery embolization in the management of cervical pregnancy. *Obstet Gynecol* 1990;76(5 Pt 2):938-41.
  21. Skannal D, Burkman RT. Cervical pregnancy treated with methotrexate. A case report. *J Reprod Med* 1989;34:496-8.
  22. Stovall TG, Ling FW, Smith WC, Felker R, Rasco BJ, Buster JE. Successful nonsurgical treatment of cervical pregnancy with methotrexate. *Fertil Steril* 1988;50:672-4.
  23. Oyer R, Tarakjian D, Lev-Toaff A, Friedman A, Chatwani A. Treatment of cervical pregnancy with methotrexate. *Obstet Gynecol* 1988;71(3 Pt 2):469-71.
  24. Kaplan BR, Brandt T, Javaheri G, Scommegna A. Successful treatment of a live cervical pregnancy with methotrexate and folinic acid. A case report. *J Reprod Med* 1989;34:853-6.
  25. Palti Z, Rosenn B, Goshen R, Ben-Chitrit A, Yagel S. Successful treatment of a viable cervical pregnancy with methotrexate. *Am J Obstet Gynecol* 1989;161:1147-8.
  26. Frates MC, Benson CB, Doubilet PM, DiSalvo DN, Brown DL, Laing FC, et al. Cervical ectopic pregnancy: results of conservative treatment. *Radiology* 1994;191:773-5.
  27. Kaplan BR, Brandt T, Javaheri G, Scommegna A. Nonsurgical treatment of a viable cervical pregnancy with intra-amniotic methotrexate. *Fertil Steril* 1990;53:941-3.
  28. Mantalenakis S, Tsalikis T, Grimbizis G, Aktsalis A, Mamopoulos M, Farmakides G. Successful pregnancy after treatment of cervical pregnancy with methotrexate and curettage. A case report. *J Reprod Med* 1995;40:409-14.
  29. Sepulveda WH, Vinals F, Donetch G, Ciuffardi I, Varela J. Cervical pregnancy. A case report. *Arch Gynecol Obstet* 1993;252:155-7.
  30. Segna RA, Mitchell DR, Misas JE. Successful treatment of cervical pregnancy with oral etoposide. *Obstet Gynecol* 1990;76(5 Pt 2):945-7.
  31. Brand E, Gibbs RS, Davidson SA. Advanced cervical pregnancy treated with actinomycin-D. *Br J Obstet Gynaecol* 1993;100:491-2.
  32. Hsu JJ, Chiu TH, Lai IM, Soong YK. Methotrexate treatment of cervical pregnancy with different clinical parameters. A report of three cases. *J Reprod Med* 1995;40:246-50.
  33. Walden PA, Bagshawe KD. Reproductive performance of women successfully treated for gestational trophoblastic tumors. *Am J Obstet Gynecol* 1976;125:1108-14.