

Isolated Traumatic Rupture of the Subscapularis Tendon

Russell J. Clark, MD, Jeffrey Marchessault, MD, Phillip S. Sizer, Jr., MEd, PT, and James Slauterbeck, MD

Background: Although rotator cuff tears are well documented in the literature, there have been relatively few reported cases of isolated subscapularis tears. To our knowledge, no case has been reported that describes an isolated subscapularis tear in a woman without anterior shoulder dislocation or bony avulsion.

Methods: This report outlines the case of a healthy 46-year-old woman with no history of shoulder problems who sustained injury to her right shoulder while hanging a light fixture. We highlight several key points to early diagnosis and underscore operative management for a successful outcome.

Results and Conclusions: Isolated subscapularis tendon ruptures are uncommon in women. Increased vigilance during the history and physical examination is necessary to detect these injuries. Subscapularis tendon ruptures are commonly mistaken for degenerative rotator cuff tears or subacromial impingement syndrome. The lift-off test can isolate a subscapularis injury. Pertinent radiographic and magnetic resonance imaging findings are described. (J Am Board Fam Pract 2002;15:304–8.)

Rotator cuff tears are well documented in the literature and typically involve the tendons of the supraspinatus, infraspinatus, and teres minor.^{1–3} Until recently there have been few reported cases of subscapularis tears. These tears typically occur with simultaneous damage to other muscles of the rotator cuff and are commonly discovered at the time of surgery. Subscapularis injuries are also frequently found in association with avulsion of the lesser tuberosity and anterior dislocation of the shoulder.^{4–6}

The occurrence of isolated traumatic rupture to the subscapularis tendon, without avulsion or anterior shoulder dislocation, is relatively rare.⁷ In the previous 10 years an increasing number of such injuries has been documented, all of which occurred in men.^{8–10} To our knowledge, no case has been reported that describes an isolated subscapularis tear without anterior shoulder dislocation or bony avulsion in a woman. This case report highlights several key points to early diagnosis and underscores operative management for successful outcomes.

Methods

The case of a healthy 46-year-old woman who sustained injury to her right shoulder while hanging a light fixture is described. The woman had no history of shoulder problems.

Case Report

A healthy 46-year-old right-hand-dominant woman, with no history of shoulder problems, sustained injury to her right shoulder while hanging a 20-pound light fixture. She was working in the overhead position when the fixture began to fall. In an attempt to catch the fixture, her right shoulder was forced into a direction of extension (from the overhead flexed position) and external rotation, at which time she heard a “pop” in the shoulder region. She immediately experienced shoulder pain, which gradually worsened throughout the night.

When examined the next day, she had point tenderness to the anterior shoulder and severe pain on all active movements. The pain was provoked most with active internal rotation. She was limited to 160 degrees of active forward flexion and 160 degrees of abduction with pain elicited during both movements. Additionally, she was unable to lift her hand off the buttocks when her arm was behind her back in a position of shoulder internal rotation (positive lift-off test). The patient experienced weakness (grade 4/5) and pain during right shoul-

Submitted, revised, 1 November 2001.

From the Department of Orthopedics (RJC, JM, PSS, JS), Texas Tech University School of Medicine, Lubbock. Address reprint requests to James Slauterbeck, MD, Department of Orthopedics, Texas Tech University Health Science Center, 3601 4th St, Stop 9436, Lubbock, TX 79430-9436.

der internal rotation, external rotation, and forward flexion. The impingement signs of Hawkins and Neer were mildly positive, and there was no ligamentous instability of the shoulder. No deficiency of sensation was found in any area of the right arm. Magnetic resonance imaging showed a full-thickness tear of the subscapularis tendon with no other rotator cuff abnormalities, and findings on plain film radiographs were unremarkable (Figure 1).

The right shoulder was subsequently examined while the patient was under general anesthesia. The humeral head could be translated to but not over the anterior and posterior edges of the glenoid rim. The sulcus examination (affected arm is pulled toward floor with the patient standing in the anatomic position) was less than 5 mm, indicating that the laxity in the patients shoulder was within normal limits. Through a deltopectoral approach, the subscapularis tendon was isolated. The superior 5% of the tendon was loosely attached at its insertion, but the inferior portion was torn from its humeral attachment (Figure 2). The subscapularis was subsequently mobilized from inferior to superior and anatomically reattached to the humerus using the superior fibers as a guide. Suture anchors were used for the fixation. No appreciable damage to the glenoid labrum or the other muscles of the rotator cuff was detected during the surgery.

The patient was then placed in a shoulder immobilizer and referred to physical therapy. For the first month after surgery, the patient was instructed to perform pendulum and passive pulley exercises with no external rotation beyond midline. She began isometric exercises at week 4, and strengthening exercises at week 6. Four months after the operation she recovered full active range of motion (equal to the left side). Strength assessment showed equal strength in the right and left shoulders in all planes including the subscapularis lift-off test.

Discussion

Although isolated subscapularis ruptures are not commonly reported in women, early diagnosis and surgical repair can produce an excellent result. The examiner must secure a careful account of the mechanism of injury as well as perform a thorough physical examination to make the correct diagnosis.

Smith¹¹ first described two isolated subscapularis tears in 1835 among his seven cadaver shoulders with rotator cuff tears. Codman's subsequent

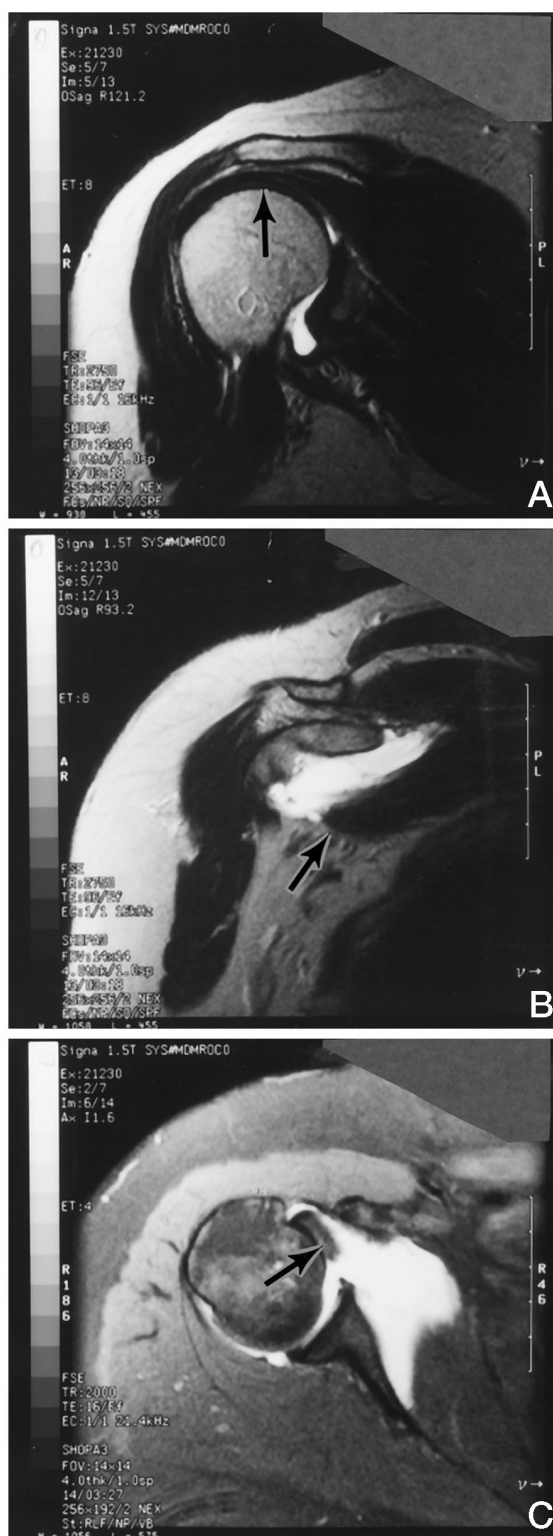


Figure 1. Three magnetic resonance imaging views of the right shoulder. **A,** Oblique sagittal plane of the right shoulder showing no involvement of the supraspinatus muscle. **B,** Oblique sagittal plane showing torn subscapularis tendon. **C,** Axial plane showing torn subscapularis tendon.

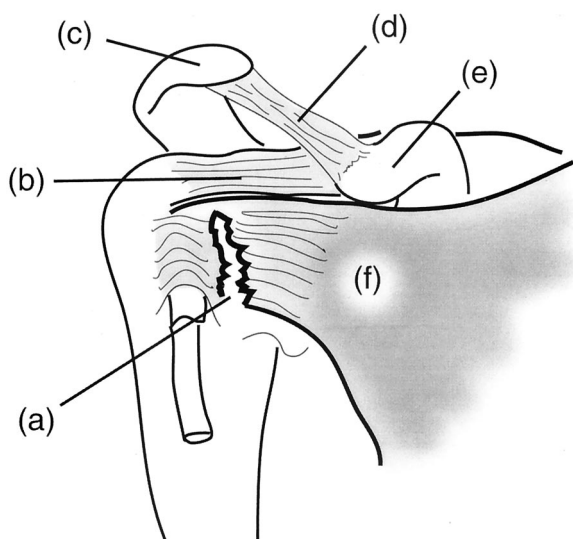


Figure 2. Subscapularis tear: (a) tear of the subscapularis tendon, (b) supraspinatus tendon, (c) acromion process, (d) coracoacromial ligament, (e) coracoid process, and (f) subscapularis muscle belly on the ventral scapula. Not pictured: subscapularis origin – medial subscapular fossa; insertion – lesser tubercle of the humerus; action – medial rotation of humerus.

work³ showed a much lower incidence of subscapularis tears with rotator cuff injuries. Little more than case reports^{1,2,5,7} were written on isolated subscapularis tears until Gerber and Krushell's series of 16 patients in 1991.¹² Neviasser et al¹³ highlighted the role of subscapularis tears in shoulders with recurrent instability after traumatic dislocations and the successful surgical outcomes from isolated repair of the subscapularis.

A review of the English literature found that women rarely sustain isolated traumatic subscapularis tears. Previous studies include women with subscapularis tears associated with anterior shoulder dislocation and recurrent instability.^{13,14}

Clinical diagnosis of isolated subscapularis tears can be a diagnostic challenge for the physician for several reasons. Because these tears are often associated with a traumatic event, the exact mechanism of injury might not be easily elicited, as, for example, from a patient who participates in an athletic sport. Conversely, the older patient with a mild injury could mislead the examiner toward a degenerative rotator cuff tear. Deutsch et al⁸ discovered that most of their patients had isolated subscapularis tears (10 of 14 shoulders) initially diagnosed as

subacromial impingement syndrome. They observed that the correct diagnosis was delayed by an average of 9 months, after all patients failed to respond to nonoperative treatment with physical therapy.

Although pain is a consistent complaint of patients with subscapularis tears, it must be differentiated from pain caused by impingement syndrome, subacromial bursitis, biceps tendon injury, shoulder dislocation, and subluxation. Clinical findings on shoulder examination will often yield multiple positive findings with isolation tests. Duetsch et al⁸ found considerable supraspinatus weakness in 35% of their patients and a painful impingement sign in 71%. They observed weakness on internal rotation and an increase in passive external rotation, as well as negative findings with instability testing, in all but 1 patient.

Gerber and Krushall¹² originally described the lift-off test for isolating a subscapularis injury. The test is performed by passively internally rotating the arm behind the back and off the patient's spine. A positive test occurs when the examiner releases the maximally internally rotated arm, and it falls to the patient's back (Figure 3). A weak test result is observed when the patient can maintain the position of maximal internal rotation but is unable to apply resistance to the examiner's hand. In their original series, 13 patients had a positive lift-off test, and the remaining 3 patients had a weak result. All 16 patients were found to have complete tears of the subscapularis muscle at the time of surgery.

A plain radiograph of the shoulder might yield a lesser tuberosity avulsion, denoting a subscapularis tear, but is generally not helpful in making the diagnosis.^{2,15} Computed tomographic arthrography will show full tears when the injected dye reaches the lesser tuberosity and has the added benefits of showing the surrounding soft tissue anatomy. In particular, subluxation of the biceps tendon medially is believed to be pathognomonic for subscapularis rupture.¹⁶ Fatty degeneration of the subscapularis muscle, noted by some to be a prognostic indicator of poorer outcomes, can be observed on magnetic resonance imaging views in the oblique sagittal plane.^{1,8,16} Although arthroscopy has been used for diagnosis of rotator cuff tears, partial tears of the subscapularis are underestimated when using this tool. Because the musculotendinous insertion is difficult to view with the

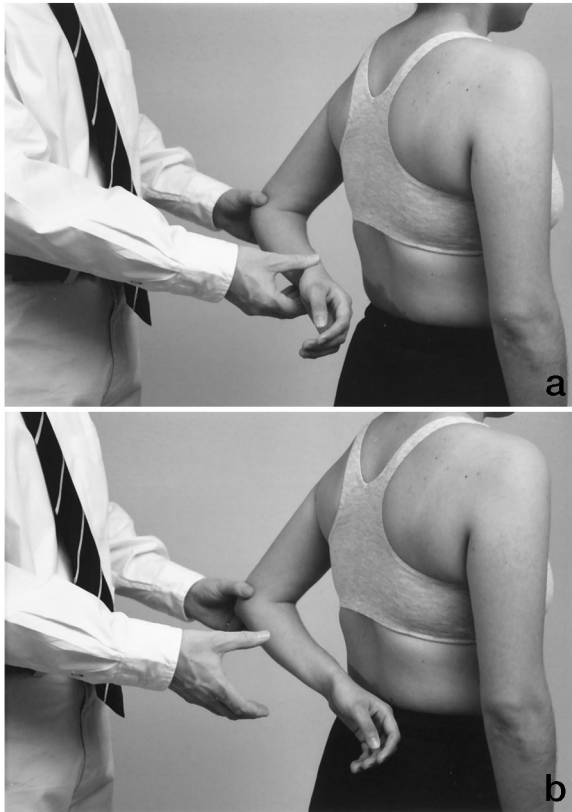


Figure 3. Positive lift-off test: (a) starting position, and (b) end position: Note that the patient is not capable of holding her forearm off her low back.

arthroscope, arthroscopy has proved to serve a limited purpose in the diagnosis of subscapularis tears.

Early operative management with primary tendon repair has been shown to yield reproducible results.¹ Chronic tears lead to muscle atrophy and involution of the tendons with resultant scar tissue that is difficult to reapproximate. Ticker and Warner¹⁶ found that tears repaired more than 1 year after the injury have frequent repair failures because of severe muscle degeneration. The high rate of success achieved by Gerber and colleagues¹ with early surgical intervention led them to favor early operative management rather than delayed repair. Furthermore, Wirth and Rockwood¹⁴ reported satisfactory results in their series of 13 patients with irreparable subscapularis rupture using pectoralis muscle transfer to manage recurrent instability.

In conclusion, rupture of the subscapularis tendon occurs more frequently in the general population than was once postulated. Increased vigilance is necessary to detect subscapularis injuries in the

woman, athlete, or elderly person who sustains a traumatic hyperextension or external rotation injury of an abducted shoulder. Increased passive external rotation is a hallmark of complete subscapularis rupture. Weakness of internal rotation, especially when tested at the extreme of internal rotation, such as the lift-off test, can lead to appropriate diagnostic studies. Being alert to this condition when examining routine shoulder injuries, correct diagnosis, and early operative management can result in improved function and decreased shoulder pain.

References

1. Gerber C, Hersche O, Farron A. Isolated rupture of the subscapularis tendon. *J Bone Joint Surg Am* 1996;78:1015–23.
2. White GM, Riley LH Jr. Isolated avulsion of the subscapularis insertion in a child. A case report. *J Bone Joint Surg Am* 1985;67:635–6.
3. Codman EA. The shoulder; rupture of the supraspinatus tendon and other lesions in or about the subacromial bursa. 2nd ed. Boston: T Todd Co, 1934: 262–312.
4. Symeonides PP. The significance of the subscapularis muscle in the pathogenesis of recurrent anterior dislocation of the shoulder. *J. Bone Joint Surg Br* 1972;54:476–83.
5. Moseley HF, Overgaard B. The anterior capsular mechanism in recurrent anterior dislocation of the shoulder. morphological and clinical studies. *J Bone Joint Surg Br* 1962;44:913–27.
6. DePalma AF, Cooke AJ, Prabhakar M. The role of the subscapularis in recurrent anterior dislocations of the shoulder. *Clin Orthop* 1967;54:35–49.
7. Dragoni S, Giombini A, Candela V, Rossi F. Isolated partial tear of the subscapularis muscle in a competitive water skier. A case report. *J Sports Med Phys Fitness* 1994;34:407–10.
8. Deutsch A, Altchek DW, Veltri DM, Potter HG, Warren RF. Traumatic tears of the subscapularis tendon. Clinical diagnosis, magnetic resonance imaging findings, and operative treatment. *Am J Sports Med* 1997;25:13–22.
9. Mendoza Lopez M, Cardoner Parpal JC, Samsó Bardes F, Coda Sotes J. Lesions of the subscapularis tendon regarding two cases in arthroscopic surgery. *Arthroscopy* 1993;9:671–4.
10. Biondi J, Bear TF. Isolated rupture of the subscapularis tendon in an arm wrestler. *Orthopedics* 1988; 11:647–9.
11. Smith HG. Pathological appearances of seven cases of injury of the shoulder joint with remarks. *Am J Med Sci* 1835;16:219–24.
12. Gerber C, Krushell RJ. Isolated rupture of the tendon of the subscapularis muscle. Clinical features in 16 cases. *J Bone Joint Surg Br* 1991;73:389–94.

13. Neviaser RJ, Neviaser TJ, Neviaser JS. Concurrent rupture of the rotator cuff and anterior dislocation of the shoulder in the older patient. *J Bone Joint Surg Am* 1988;70:1308–11.
14. Wirth MA, Rockwood CA Jr. Operative treatment of irreparable rupture of the subscapularis. *J Bone Joint Surg Am* 1997;79:722–31.
15. McAuliffe TB, Dowd GS. Avulsion of the subscapularis tendon. A case report. *J Bone Joint Surg Am* 1987;69:1454–5.
16. Ticker JB, Warner JJ. Single-tendon tears of the rotator cuff. Evaluation and treatment of subscapularis tears and principles of treatment for supraspinatus tears. *Orthop Clin N Am* 1997;28:99–116.