

Group A Streptococcal Sepsis and Ovarian Vein Thrombosis After an Uncomplicated Vaginal Delivery

Margaret Gourlay, MD, Cecilia Gutierrez, MD, Anthony Chong, MD, and Robin Robertson, MD

Background: Group A streptococcal puerperal sepsis is an uncommon peripartum infection that can quickly progress to a fulminant, multisystemic infection and life-threatening toxin-mediated shock. This infection can be asymptomatic during a short hospital stay after a routine delivery. Early treatment with antibiotics might not alter the course of tissue destruction caused by the exotoxin A.

Methods: Literature searches were performed using the key words “puerperal infections,” “streptococcal infections,” “septic sacroiliitis,” “postpartum septic arthritis,” and “postpartum ovarian vein thrombosis.” After patient consent was obtained, a report was prepared documenting the disease course, diagnosis, and treatment of a case of puerperal sepsis with multiple serious complications.

Results and Conclusion: Puerperal sepsis occurs when streptococci colonizing the genital tract or acquired nosocomially invade the endometrium, adjacent structures, lymphatics, and bloodstream. A lack of symptoms early in the course of infection is common; later, minor somatic complaints can quickly progress to septic shock as effects of the exotoxin A are manifest. Women who complain of fever, pelvic pain, or unexplained systemic symptoms in the early postpartum period should have a detailed history and physical examination. All sites of suspected infection should be cultured. If sepsis is suspected, diagnostic imaging includes chest radiographs, contrast-enhanced computed tomographic scans, or magnetic resonance imaging to rule out ovarian vein thrombosis, pelvic abscess, or sacroiliac septic arthritis. Broad-spectrum antibiotic coverage must be initiated immediately after collection of cultures. Clindamycin plus a β -lactam antibiotic is preferred for streptococcal toxic shock syndrome. (*J Am Board Fam Pract* 2001;14:375–80.)

Group A streptococcal puerperal sepsis is an uncommon peripartum infection marked by rapid invasion of tissue, lymphatics, and bloodstream, with potential progression to life-threatening toxin-mediated shock. Destructive effects on tissue and systemic toxicity are associated with strains of the organism that produce the exotoxin A. Even with early treatment intervention, severe complications can continue as a result of toxin-mediated effects that are not altered by antibiotics. Group A streptococcal puerperal infections can be asymptomatic during a short hospital stay after a routine delivery. Infections with virulent strains can take an unpre-

dictable course in which fever or mild somatic complaints might be the only warning signs before rapid progression to fulminant infection and multorgan involvement.

Methods

Searches were performed through MEDLINE and the National Library of Medicine Internet Grateful Med using the following key words: “puerperal infections,” “streptococcal infections,” “septic sacroiliitis,” “postpartum septic arthritis,” and “postpartum ovarian vein thrombosis.” The case report was prepared after review of medical records and consultant reports during the patient’s initial hospitalization for puerperal sepsis, and two subsequent admissions for fever of unknown origin. Consent was obtained from the patient before this report was written.

Submitted, revised, 21 January 2001.

From the Department of Family and Preventive Medicine (MG, CG, AC, RR), University of California, San Diego. Address reprint requests to Margaret Gourlay, MD, Department of Family Medicine, Georgetown University, 212 Kober-Cogan Hall, 3750 Reservoir Rd, NW, Washington, DC 20007.

Case Report

A 39-year-old woman, gravida 2 para 2, gave birth to a healthy, full-term infant by spontaneous vaginal delivery. Her prenatal course was uncomplicated except for an episode of bacteriuria at 9 weeks of gestational age, which was treated with cephalexin. She also developed a pustular rash in the T-10 dermatomal distribution, which was diagnosed as zoster in the Emergency Department and not treated. A vaginal-rectal culture was negative for group B streptococcus. The peripartum period was marked by rupture of membranes approximately 12 hours before delivery, the use of oxytocin to augment her contractions, and a transient episode of elevated blood pressure without proteinuria. She sustained a second-degree midline posterior vaginal wall laceration during delivery, which was repaired without incident using standard sterile techniques. She was discharged from the hospital on postpartum day 1, feeling well.

The patient had had a cesarean section in 1996; her health history was otherwise noncontributory to her subsequent illness. She was married and worked as a registered nurse in a neonatal intensive care unit. She had no history of tobacco, alcohol, or drug abuse. She had no known drug allergies.

On postpartum day 2 the patient reported mild urinary incontinence to her primary physician. A urine culture performed on that day showed growth of mixed urethral flora. Her condition was treated empirically with nitrofurantoin on an outpatient basis, and she reported initial improvement. On postpartum day 5 she developed fever, chills, lethargy, and left hip pain that progressed until she began to have difficulty bearing weight. She sought medical attention on postpartum day 7, at which time her primary physician referred her for hospital admission because of her worsening previous symptoms and new pain in the right wrist and left knee.

She appeared ill at the time of admission. She had a temperature of 100.7°F, her blood pressure was 105/55 mm Hg without orthostatic changes, and her pulse was 110 beats per minute. Findings of a cardiopulmonary examination were unremarkable, and she had no skin rashes. Her abdomen was tender to palpation in both lower quadrants with guarding and peritoneal signs. She had a poorly approximated midline laceration with purulent discharge, as well as purulent material at the cervical os, and tenderness to palpation in the labia, left

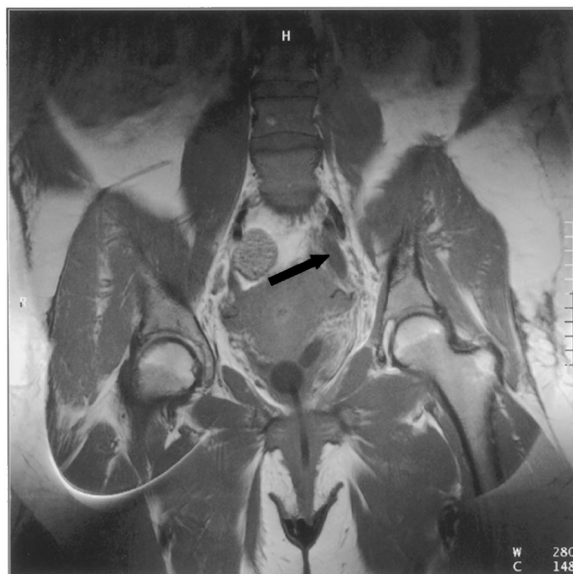

Figure 1. Magnetic resonance imaging: precontrast T-1 weighted image of the pelvis showing a tubular structure with decreased signal representing clot in left ovarian vein (arrow).

greater than right. Bimanual examination elicited cervical motion tenderness and left adnexal tenderness. Her neurologic examination findings were normal.

After cultures were collected, she was started on broad-spectrum intravenous antibiotic coverage with ampicillin, gentamicin, and clindamycin. Diagnostic testing showed the following values: white cell count 17,000/ μ L, with 40% neutrophils and 56% band cells; hemoglobin 9.2 g/dL, hematocrit 26.9%, and platelets 184,000/ μ L. Blood urea nitrogen was 24 mg/dL, and creatinine was 1.5 mg/dL. Urine culture showed a group A streptococcus colony growth of $> 100,000$ /mL. Group A streptococcus was also cultured from the vaginal wound and from an aspirate of the right wrist. A bilateral lower extremity Doppler examination was negative for evidence of deep venous thrombosis. Findings on a chest radiograph, electrocardiogram, and transthoracic echocardiogram were normal. A computed tomographic (CT) scan of the pelvis and abdomen showed evidence of left ovarian vein thrombophlebitis. Magnetic resonance imaging (MRI) of the pelvis showed left ovarian vein thrombosis (Figure 1) and septic arthritis of the left sacroiliac joint (Figure 2). A pelvic bone scan showed no evidence of osteomyelitis.

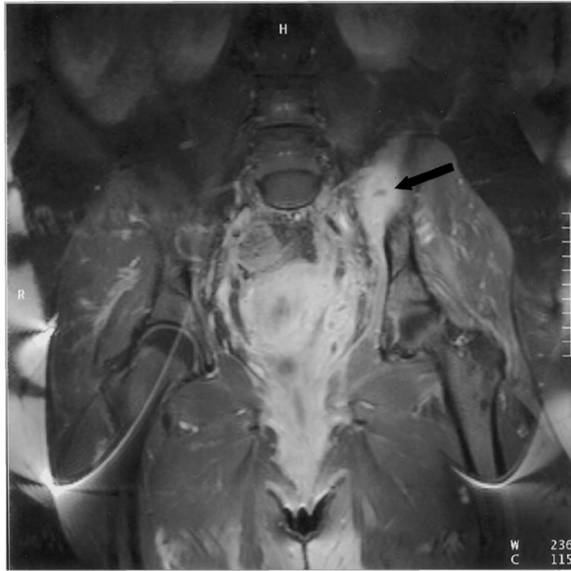


Figure 2. Magnetic resonance imaging: postcontrast T-1 weighted image showing inflammatory thrombophlebitis surrounding clot in left ovarian vein. Inflammation extends to the area of the left sacroiliac joint (arrow).

The patient underwent surgical incision and drainage of septic fluid from the right wrist. A 10-day course of intravenous heparin was completed for treatment of ovarian vein thrombosis. She was discharged with a peripherally inserted central catheter for administration of ceftriaxone at home; a 6-week course of ceftriaxone with trimethoprim-sulfamethoxazole was initially planned.

The patient was hospitalized twice during the subsequent 2 weeks for complaints of fever and intermittent rashes despite decreased joint pain and good progress in physical therapy. Repeat cultures 3 and 4 weeks postpartum, including aspirate of the left knee, were all negative. Pelvic and abdominal imaging was without evidence of abscess, and a transesophageal echocardiogram showed no valvular vegetations. Fever and rash secondary to drug reaction was diagnosed by exclusion. With the patient's consent, all antibiotics were withdrawn after a total of 4 weeks of intravenous treatment. Her temperature immediately returned to normal, and she has since achieved increased strength and improved limb function.

Discussion

Group A Streptococcal Puerperal Sepsis

Puerperal sepsis has been described by physicians since the time of Hippocrates. Formerly known as

childbed fever, puerperal sepsis caused up to two thirds of deaths of new mothers in the 18th and 19th centuries.¹ In his essay on puerperal fever published in 1842, Oliver Wendell Holmes, the eminent Professor of Anatomy and Physiology at Harvard, suggested that puerperal sepsis could be transmitted by obstetricians.² It was not until Semmelweis studied puerperal fever in the late 1840s, however, that the concept of an infectious cause for the disease began to be accepted. Semmelweis reported decreased mortality from puerperal sepsis after instituting systematic hand-washing policies in the obstetric wards of the General Hospital in Vienna.³ In 1879, Pasteur reported that puerperal sepsis was usually caused by streptococcus.

As sterile techniques and antibiotic treatment became standard, morbidity and mortality from this disease declined markedly; by the early 1980s only small, sporadic epidemics were reported. The so-called disappearance of serious streptococcal infections during this period has been attributed to a disappearance of type A exotoxin produced by certain strains of the organism.⁴ Reports during the past decade suggest a reemergence worldwide of more virulent strains of group A streptococcus that can cause severe soft-tissue invasion, septic shock, and disseminated intravascular coagulation.⁵⁻⁸

Puerperal sepsis occurs when streptococci colonizing the genital tract or acquired nosocomially invade the endometrium, adjacent structures, lymphatics, and bloodstream. The postpartum birth canal can remain susceptible to invasion for several days after delivery. Cesarean section has been cited as a risk factor for serious puerperal infection.⁴ Early high fever is considered a classic feature; however, fever has been reported as late as 7 days postpartum.⁹ An absence of pelvic signs and symptoms is also common, and a flu-like syndrome with vague somatic complaints might be the only heralding symptoms before septic shock ensues. Invasive infection can be complicated by pelvic cellulitis, septic ovarian vein thrombosis, peritonitis, pelvic abscess, or septic arthritis.

The toxic-shock-like syndrome that can occur with group A streptococcal infection is attributed to exotoxin A (scarlet fever toxin) produced by M1 or M3 serotypes of the organism. The exotoxin produces rapid skin and soft tissue necrosis, fever, septic shock, and multiple organ failure, with a reported mortality rate of 20% to 25%.^{10,11} Timely treatment with β -lactam antibiotics is crucial; how-

Table 1. Differential Diagnosis of Group A Streptococcal Puerperal Sepsis.

Sepsis from other pathogens (eg, toxic shock syndrome from <i>Staphylococcus aureus</i> , group B, C, or G streptococcal sepsis)
Postpartum endometritis
Preeclampsia
Retained products of conception predisposing to infection
Pelvic abscess
Endocarditis
Hypotensive shock secondary to postpartum bleeding
Pulmonary embolism
Sheehan syndrome (postpartum pituitary necrosis)
More limited infections such as urosepsis or pneumonia

ever, antibiotics are not effective against the exotoxin, and tissue damage might progress despite antibiotic therapy.

Differential diagnosis of group A streptococcal puerperal sepsis is presented in Table 1. Diagnostic imaging can include chest radiographs, contrast-enhanced CT scans, or MRIs to rule out ovarian vein thrombosis, pelvic abscess, or sacroiliac septic arthritis.

Broad-spectrum antibiotic coverage must be initiated immediately after collection of cultures. Group A streptococcus is exquisitely sensitive to β -lactams. Clindamycin plus a β -lactam antibiotic is preferred for streptococcal toxic shock syndrome.¹² Prompt and aggressive exploration and debridement of necrotic tissue are important. Hysterectomy is usually not needed; however, in severe cases involving large bacterial inocula, extensive tissue necrosis, or gangrene, hysterectomy and even removal of adnexal tissue might be indicated.

Septic Sacroiliitis

Only one to two cases of septic sacroiliitis are reported in the English literature each year. Intravenous drug use, infections remote from the site of the sacroiliac joint, and chronic joint disease are the most common predisposing factors. In one review of 166 cases, 4% of patients diagnosed with septic sacroiliitis had an underlying associated gynecologic condition.¹³

Patients typically complain of fever, hip or buttock pain, and pain on weight bearing. Pain can be referred to the low back, thigh, or lower abdomen because of the common innervation of structures surrounding the affected joint.¹⁴ If diagnosis is delayed, considerable morbidity can result, and surgical drainage might be warranted.

Laboratory studies commonly show an elevated erythrocyte sedimentation rate, with or without an elevated white cell count. Blood cultures were positive in 23% of cases in one review.¹³ If blood cultures are negative, fluoroscopic-guided fine-needle aspiration may be used to obtain fluid for culture.

Radiographic studies are important in confirming the diagnosis. While plain films tend to be normal early in the disease process, a bone scan is usually positive within 48 hours after the onset of symptoms. Sacroiliitis must be distinguished from other inflammatory disorders in which a bone scan might be positive, such as ankylosing spondylitis, Reiter syndrome, rheumatoid arthritis, or inflammatory bowel disease.¹⁵ A CT scan has been reported to show abnormalities before bone scan in some cases of sacroiliitis.¹⁶

Treatment should be started as soon as a clinical diagnosis is made. High-dose intravenous antibiotic treatment is administered for 4 to 6 weeks. Empiric antibiotics should cover for *Staphylococcus aureus* and streptococcus species, since these are the most common associated pathogens in developed countries.¹⁷

Postpartum Ovarian Vein Thrombosis

Postpartum ovarian vein thrombosis (POVT) is a rare and serious complication that can occur after delivery. It can be more common after an abortion or in association with preterm or cesarean deliveries; it can also occur after a hysterectomy-salpingo-oophorectomy or in the setting of gynecologic malignancy.¹⁸ POVT has been reported to occur postpartum in 1:500 to 1:2000 women.¹⁹ Risk factors include multiparity, infection, cesarean section, and a thrombophilic tendency. Thrombosis develops 1 to 17 days postpartum (average 8 days).^{19,20} Patients can have spiking fever and lower abdominal pain, flank pain, or back pain. When examined, patients are often tachycardic, and most will have a tender, palpable abdominal mass along the paracolic gutter. Ninety percent of cases involve the right ovarian vein.²¹ The right ovarian vein is usually longer than the left, has multiple incompetent valves, and unlike the left ovarian vein, has antegrade blood flow.

Differential diagnosis of POVT is listed in Table 2. Before the advent of radiologic studies, diagnosis of this disease was often made after exploratory laparotomy. POVT can now be definitively

Table 2. Differential Diagnosis of Postpartum Ovarian Vein Thrombosis.

Acute appendicitis
Adnexal torsion
Broad ligament hematoma
Adnexal abscess
Intestinal volvulus
Pyelonephritis
Pelvic inflammatory disease
Urinary tract infection

diagnosed with the aid of a contrast-enhanced CT scan, which has a sensitivity and specificity approaching 100%. An MRI can also be useful; however, the sensitivity is lower at 92%. Doppler sonography has a sensitivity of about 50% to 52% for detection of POVT.²²

The current theory of POVT pathogenesis is based on Virchow's triad of thrombus formation, which comprises epithelial injury, stasis, and hypercoagulability. Endometritis or infectious thrombophlebitis promotes epithelial injury. During pregnancy the size of the ovarian veins increases threefold while their blood-carrying capacity increases by 60-fold, leading to diminished blood flow in the immediate postpartum period. Pregnancy itself is a hypercoagulable state caused by pregnancy-related decrease in protein S; increased fibrinogen and factors I, II, VII, VIII, IX, and X; increased platelet adhesiveness; and decreased fibrinolytic activity up to 72 hours after delivery.¹⁹ These factors combine to increase the risk of venous thrombus formation.

The most dangerous complications of POVT are (1) pulmonary embolism, (2) sepsis with risk of multiorgan failure, (3) extension of the thrombus into the inferior vena cava, the renal veins, or the iliofemoral veins, and (4) increased risk of ovarian infarction. Treatment for POVT in the past consisted of surgical options. Today, however, it consists of anticoagulation and antibiotics, if needed. There is no uniform agreement regarding length of treatment, and no standard protocol exists for determining the duration of anticoagulation with heparin or the need for conversion to warfarin. Heparin treatment is typically continued for 7 to 10 days,²³ although an alternative recommendation is 144 hours of total heparin (6 days) with 120 hours at the therapeutic heparin level.²⁰

Improvement can occur within 48 hours of initiation of heparin treatment; however, clinical response might take up to 18 days.¹¹ Whether anticoagulation should be continued with long-term warfarin depends on extension of thrombus, circumstances surrounding the POVT, and findings during follow-up studies. Computed tomography²³ and serial sonograms²⁴ have been used to monitor regression of clot to help guide therapy.

It is interesting to note that our patient developed a left-sided ovarian vein thrombosis. She completed a 10-day course of intravenous heparin during her first hospitalization. A follow-up CT scan performed 12 days after completion of therapy showed no evidence of extension of the thrombus.

Conclusion

Puerperal infection from group A β -hemolytic streptococcus is uncommon today, but recent reports indicate a reemergence of virulent strains that can cause rapid tissue invasion, toxin-mediated shock, and multiple organ failure. A lack of symptoms early in the course of infection is common; later, minor somatic complaints can quickly progress to septic shock as effects of the exotoxin A are manifest.

Unlike for group B streptococcus, routine screening and prophylaxis for group A streptococcus bacteria in the prenatal period is not standard. The following recommendations apply to women who complain of fever, pelvic pain, or unexplained systemic symptoms in the early postpartum period: (1) Obtain a detailed history and physical examination to detect possible early signs or symptoms of pelvic infection. (2) Collect cultures of all suspected sites of infection, including blood, vaginal fluid, urine, and joint fluid. (3) When sepsis is suspected, obtain a chest radiograph, electrocardiogram, and echocardiogram, as indicated. (4) CT scans and MRI are useful to rule out ovarian vein thrombophlebitis as a septic complication. (5) Immediately after collection of cultures, initiate broad-spectrum antibiotics. Clindamycin plus a β -lactam antibiotic is preferred for streptococcal toxic shock syndrome. (6) Surgical debridement of necrotic tissue and, rarely, hysterectomy are warranted in severe cases.

William A. Norcross, MD, provided advice and editorial comments. Michael Middleton, MD, and Robert Mattrey, MD, prepared the diagnostic images included in this report.

References

1. Gergis H, Barik S, Lim K, Porter W. Life-threatening puerperal infection with group A streptococcus. *J R Soc Med* 1999;92:412-3.
2. Holmes OW. The contagiousness of puerperal fever. *New England Quarterly Journal of Medicine and Surgery* 1842-1843;1:503-30.
3. Semmelweis I (Carter KC, translator). The etiology, concept, and prophylaxis of childbed fever. In: *Wisconsin Publications in the History of Science and Medicine*, no. 2. Madison, WI: University of Wisconsin Press, 1983.
4. Nathan L, Peters MT, Ahmed AM, Leveno KJ. The return of life-threatening puerperal sepsis caused by group A streptococci. *Am J Obstet Gynecol* 1993;169:571-2.
5. Group A beta-hemolytic streptococcal bacteremia—Colorado, 1989. *MMWR Morbid Mortal Wkly Rep* 1990;39:3-6, 11.
6. Stevens DL. Streptococcal toxic-shock syndrome: spectrum of disease, pathogenesis, and new concepts in treatment. *Emerg Infect Dis* 1995;1(3):69-78.
7. Perez-Trallero E, Marimon JM, Montes M, Orden B, de Pablos M. Clonal differences among erythromycin-resistant *Streptococcus pyogenes* in Spain. *Emerg Infect Dis* 1999;5:235-40.
8. Use of pulsed-field gel electrophoresis for investigation of a cluster of invasive group A streptococcal illness—Spokane, Washington, 1999. *MMWR Morbid Mortal Wkly Rep* 1999;48:681-3.
9. Silver RM, Heddleston LN, McGregor JA, Gibbs RS. Life-threatening puerperal infection due to group A streptococci. *Obstet Gynecol* 1992;79(5 Pt 2):894-6.
10. Noronha S, Yue CT, Sekosan M. Puerperal group A beta-hemolytic streptococcal toxic shock-like syndrome. *Obstet Gynecol* 1996;88(4 Pt 2):728.
11. Martens PR, Mullie A, Goessens L. A near-fatal case of puerperal sepsis. *Anaesth Intensive Care* 1991;19:108-10.
12. Bisno AL. Group A streptococcal infections and acute rheumatic fever. *N Engl J Med* 1991;325:783-93.
13. Vyskocil JJ, McIlroy MA, Brennan TA, Wilson FM. Pyogenic infection of the sacroiliac joint: case reports and review of the literature. *Medicine* 1991;70:188-97.
14. Abbott GT, Carty IT. Pyogenic sacroiliitis, the missed diagnosis? *Br J Radiol* 1993;66:120-2.
15. Rambaldi PF, Ambrosone L, Mansi L, Torino G, Del Vecchio E, Rambaldi M. Immunoscintigraphy as an adjunct to diagnostic imaging in septic sacroiliitis. Report of a case. *Clin Rheumatol* 1996;15:67-71.
16. Morgan GJ Jr, Schlegelmilch JG, Spiegel PK. Early diagnosis of septic arthritis of sacroiliac joint by use of computed tomography. *J Rheumatol* 1981;8:979-82.
17. Bronze MS, Whitby S, Schaberg DR. Group G streptococcal arthritis: case report and review of the literature. *Am J Med Sci* 1997;313:239-43.
18. Quane LK, Kidney DD, Cohen AJ. Unusual causes of ovarian vein thrombosis as revealed by CT and sonography. *AJR Am J Roentgenol* 1998;171:487-90.
19. Salomon O, Apter S, Shaham D, et al. Risk factors associated with postpartum ovarian vein thrombosis. *Thromb Haemost* 1999;82:1015-9.
20. Witlin AG, Sibai BM. Postpartum ovarian vein thrombosis after vaginal delivery: a report of 11 cases. *Obstet Gynecol* 1995;85(5 Pt 1):775-80.
21. Munsick RA, Gillanders LA. A review of the syndrome of puerperal ovarian vein thrombophlebitis. *Obstet Gynecol Surv* 1981;36:57-66.
22. Twickler DM, Setiawan AT, Evans RS, et al. Imaging of puerperal septic thrombophlebitis: prospective comparison of MR imaging, CT, and sonography. *AJR Am J Roentgenol* 1997;169:1039-43.
23. Magee KP, Blanco JD, Graham JM. Massive septic pelvic thrombophlebitis. *Obstet Gynecol* 1993;82(4 Pt 2 Suppl):662-4.
24. Lev-Toaff AS, Baka JJ, Toaff ME, Friedman AD, Radecki PD, Caroline DF. Diagnostic imaging in puerperal febrile morbidity. *Obstet Gynecol* 1991;78:50-5.