

Toxic Shock Syndrome: Broadening the Differential Diagnosis

Christopher M. Herzer, MD

Background: Toxic shock syndrome is a rare but potentially fatal toxin-mediated febrile illness. Although classically associated with tampon use, it is now known that many nonmenstrual conditions are related to this syndrome. Serious morbidity and mortality can occur if this syndrome is not promptly recognized.

Methods: MEDLINE was searched from 1978 to the present using the phrase “toxic shock syndrome.” Case reports and articles related to tampon-associated toxic shock syndrome were excluded from the literature review except when defining toxic shock syndrome or discussing the cause of the syndrome. A case of nonmenstrual toxic shock syndrome associated with an intrauterine device and a review of the definition, cause, diagnostic criteria, and management are reported.

Results and Conclusions: Toxic shock syndrome can mimic many common diseases. Because it can be associated with a number of nonmenstrual-related conditions, patients with unexplained fever and rash and a toxic condition out of proportion to local findings should have the diagnosis of toxic shock syndrome in their differential diagnosis. Early recognition and aggressive management can decrease the overall morbidity and mortality. (*J Am Board Fam Pract* 2001;14:131–6.)

Toxic shock syndrome is an acute, toxin-mediated febrile illness that rapidly leads to multiorgan system failure with serious morbidity and mortality. Although classically associated with tampon use, toxic shock syndrome has also been associated with a variety of nonmenstrual-related conditions. No reports in the literature have specifically cited a direct relation between toxic shock syndrome and intrauterine device (IUD) use. A case of toxic shock syndrome and septicemia associated with copper T IUD use is described, with a brief review of the clinical presentation and differential diagnosis of toxic shock syndrome. Although the potential link between toxic shock syndrome and IUD use is equivocal, this case clearly illustrates that tampon use is not the only clinical situation associated with this syndrome.

Methods

MEDLINE was searched from 1978 to the present using the phrase “toxic shock syndrome.” Excluded

from the literature review were case reports and articles related to tampon-associated toxic shock syndrome, except when defining toxic shock syndrome or discussing the cause of the syndrome. Reported is a case of nonmenstrual toxic shock syndrome associated with an IUD, followed by a review of the definition, cause, diagnostic criteria, and management.

Case Report

A 31-year-old woman came to the emergency department of a military community hospital complaining of a 2-day history of fever, headache, and myalgia. She reported nausea, nonbloody emesis, and diarrhea. A complete blood cell count showed a normal white cell count with considerable immature leukocytosis. An acute viral syndrome was diagnosed, and she was released from the emergency department. She returned to the clinic 2 days later complaining of increasing muscle pain. She had started her menses 2 days previously but denied tampon use. She had had an IUD placed 5 years earlier. There were no acute respiratory tract or urinary tract symptoms.

Her blood pressure, temperature, respirations, and heart rate were normal. When examined, she had diffuse muscle tenderness over her proximal

Submitted, revised, 24 August 2000.

From the Family Practice Department, Naval Hospital, Camp Pendleton, Calif. Address reprint requests to Christopher M. Herzer, MD, 447 Koelper St, Oceanside, CA 92054.

extremities, back, and abdomen. She had petechiae over the lower extremities, as well as palmar and medial thigh erythema. A bloody vaginal discharge consistent with menses was found during a pelvic examination. IUD strings were present, and there was mild uterine tenderness to palpation. A repeat complete blood cell count showed a normal white cell count with an elevated immature leukocyte count. Further tests showed thrombocytopenia, elevated liver enzymes, and a creatine phosphokinase reading twice the normal level. She was hypoalbuminemic and hypocalcemic, and she had pyuria, hematuria, and proteinuria. Blood, urine, and genital samples were obtained for culture. The patient was admitted for presumed pyelonephritis and started on broad-spectrum antibiotics. The patient became tachycardic and hypotensive, requiring large volumes of fluid to maintain her blood pressure. She was transferred to intensive care, where, despite aggressive fluid replacement, shock and disseminated intravascular coagulation ensued. She was transferred to a tertiary care facility for more intensive care after being intubated. Her IUD was removed by the accepting facility.

Blood and vaginal cultures grew *Staphylococcus aureus*. Urine cultures were negative. Her antibiotics were changed to oxacillin, vancomycin, and clindamycin. Ten days after admission she had exfoliation of her skin. She also developed adult respiratory distress syndrome, staphylococcal endocarditis and myocarditis, and septic emboli to the brain, kidney, spleen, and liver. She was released from the hospital after 2 months of inpatient therapy and is undergoing physical and occupational therapy.

Discussion

Toxic shock syndrome was first coined in 1978 by Todd et al,¹ who reported the symptom complex in a group of 7 children aged 8 to 17 years with an acute febrile illness. During the next few years, the number of cases increased, and toxic shock syndrome became associated with young menstruating women. When cases began to occur in men as well as nonmenstruating women, it became apparent that this syndrome could affect any population. It is now known that three criteria are required to develop toxic shock syndrome: (1) the patient is colonized or infected with *S aureus*, (2) the bacteria produce toxic shock syndrome toxin-1 (TSST-1) or

similar toxins, and (3) the toxins have a route of entry into the circulatory system.

Toxic shock syndrome is caused by a strain of *S aureus* that produces the toxins TSST-1 and enterotoxins A through E.² TSST-1 suppresses neutrophil chemotaxis, induces T-suppressor function, and blocks the reticuloendothelial system.³ The toxins act together as superantigens that stimulate the release of various cytokines, prostaglandins, and leukotrienes, which produce the signs and symptoms of the syndrome.⁴ TSST-1 produces an antibody response in vivo that is believed to be protective. By middle age, 90% to 95% of women have detectable antibody titers.⁵ Patients with toxic shock syndrome produce a poor response to TSST-1 with titers of <1:5, whereas healthy patients have titers of >1:100.⁶

The typical signs and symptoms of toxic shock syndrome are a high fever (>38.9°C), headache, vomiting, diarrhea, myalgias, and an erythematous rash characterized as a sunburn. Other signs and symptoms can include meningismus,⁷ pharyngitis, conjunctivitis, vaginitis, edema, arthralgias, irritability, fatigue, and abdominal pain.⁸ Shock, adult respiratory distress syndrome, disseminated intravascular coagulation, and renal failure can develop. Laboratory abnormalities that are found in greater than 85% of affected patients include immature pleocytosis, hypoalbuminemia, hypocalcemia, elevated liver enzyme levels, and elevated creatine phosphokinase levels.⁹ Thrombocytopenia, pyuria, proteinuria, and elevated blood urea nitrogen and creatinine levels can also occur. Figure 1⁹ represents the typical chronology of symptoms in toxic shock syndrome. Table 1¹⁰ displays the Centers for Disease Control (CDC) guidelines for diagnosis. The case described here clearly meets the criteria for classification as a true case of toxic shock syndrome within the CDC guidelines.

Toxic shock syndrome is separated into two distinct categories: menstrual and nonmenstrual. More than 99% of menstrual cases of toxic shock syndrome are associated with tampon use.¹¹ With increased awareness and reporting of toxic shock syndrome in the 1980s, it became evident that women could develop toxic shock syndrome unrelated to their menses. As increasing emphasis was placed on the criteria than on the source of toxic shock syndrome, it became evident that men could have similar signs and symptoms. Up to 45% of all cases of toxic shock syndrome are nonmenstrual.¹²

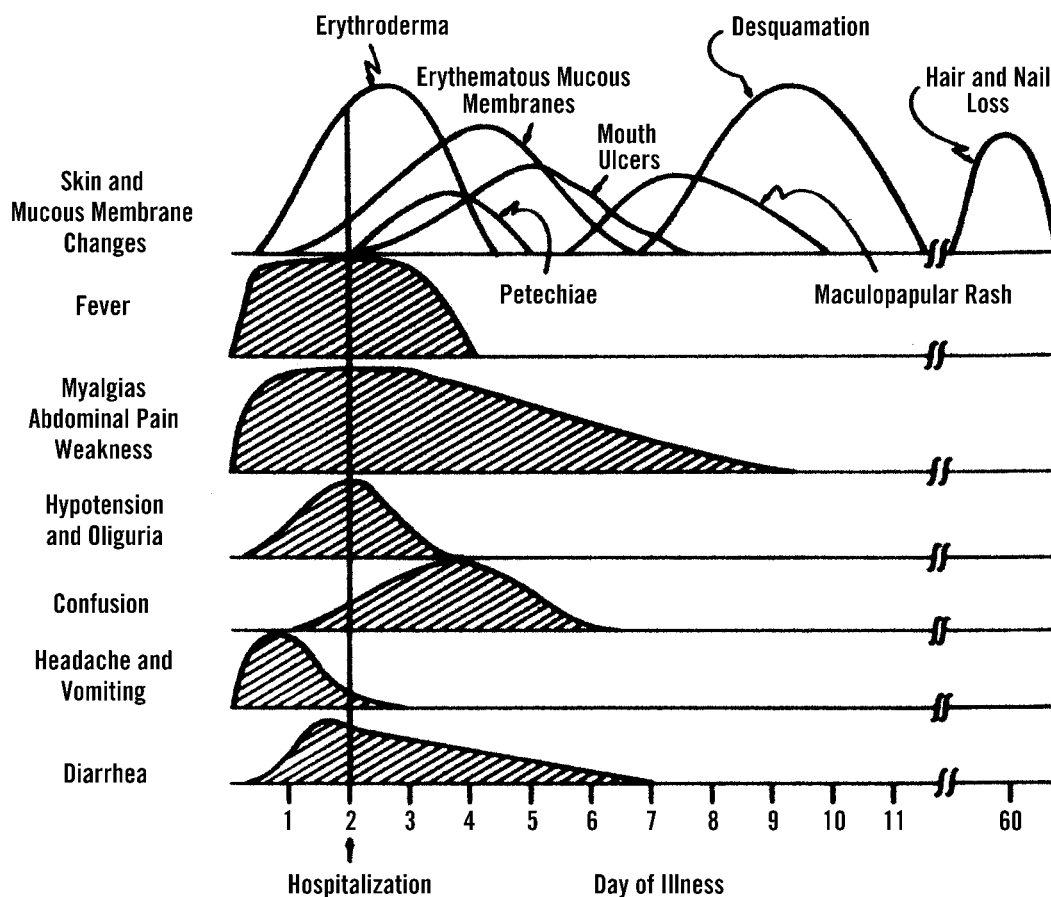


Figure 1. Composite drawing of major systemic, skin, and mucous membrane manifestations of toxic shock syndrome. (From JAMA 1981;246:741-8, Figure 1.⁹ Copyrighted 1981, American Medical Association).

Nonmenstrual cases have been attributed to abscesses, cellulitis, bursitis, postpartum infections, postsurgical procedures, and vaginal infections. Table 2 gives a comprehensive list of conditions associated with subsequent toxic shock syndrome.

To date, there have been two documented cases in the literature of toxic shock syndrome in patients related to IUD use.¹³ Two cases exist where IUD use was concurrent with tampon use.¹⁴ Although IUD use has not been cited as a risk factor for toxic shock syndrome, epidemiologic studies show that up to one third of cases come from an unknown focus of infection.¹⁵ IUD use might be a more common and heretofore unrecognized cause of toxic shock syndrome. IUD use has been shown to be associated with an increased incidence of pelvic inflammatory disease most commonly seen in the first 4 months after insertion.¹⁶ These infections are commonly polymicrobial and are consistent with the typical vaginal flora of healthy women. Some studies have reported *S aureus* in vaginal

cultures of 5% to 20% of women,^{17,18} with the highest prevalence in women using diaphragms and IUDs as contraception.¹⁹ One study found that a small percentage (4%) of IUDs was colonized with *S aureus*.²⁰ This finding clearly illustrates that *S aureus* infection is possible in women with IUDs.

IUDs cause an inflammatory response and microtrauma in the uterus that can allow bacteria or toxins to enter the systemic circulation. Microulcerations of the cervix might also serve as a portal of entry. It has been shown that tampon use leads to ulcerations of the cervix and vagina,²¹ and that toxic shock syndrome can be associated with this disruption in mucosal integrity.²² It could be argued that the strings from the IUD also form microulcerations on the cervix and vagina, which might allow bacteria and toxin to enter the circulation, leading to toxic shock syndrome and subsequent bacteremia, as seen in this patient.

An IUD as the focus of infection in this patient can be debated. *S aureus* bacteremia has been found

Table 1. Case Definition of Toxic Shock Syndrome.

Clinical Manifestation	Characteristic
Fever	>38.9°C or 102°F
Rash	Diffuse macular erythroderma
Hypotension	Systolic blood pressure <90 mm Hg for adults or less than the 5th percentile by age for children <16 years, orthostatic drop in diastolic blood pressure >15 mm Hg from lying to sitting, orthostatic syncope, or orthostatic dizziness
Multisystem involvement of 3 or more of the following:	
Gastrointestinal	Vomiting or diarrhea at onset of illness
Muscular	Severe myalgia or creatine phosphokinase levels at least twice the upper limit of normal for laboratory
Mucous membrane	Vaginal, oropharyngeal, or conjunctival hyperemia
Renal	Blood urea nitrogen or creatinine at least twice the upper limit of normal for laboratory or urinary sediment with pyuria (>5 leukocytes per high-power field) in the absence of urinary tract infection
Hepatic	Platelets <100,000/ μ L
Central nervous system	Disoriented or alterations in consciousness without focal neurologic signs when fever and hypotension are absent
Negative results on tests, if obtained	Blood, throat, or cerebrospinal fluid cultures (blood may be positive for <i>Staphylococcus aureus</i>) Rise in body titer to Rocky Mountain spotted fever, leptospirosis, or measles
Case classification	
Probable	A case with 5 of the 6 clinical findings above
Confirmed	A case with all 6 of the findings described above, including desquamation, unless the patient dies before desquamation can occur

Note: As defined by the Centers for Disease Control and Prevention.

to have no focus in up to one third of cases, and the initial infection by *S aureus* leading to toxic shock syndrome can be subclinical. This patient, on closer examination at the hospital to which she was transferred, was found to have a mild case of chronic scalp folliculitis with impetigo. Although a dermatologist dismissed this infection as clinically important, it could have served as the portal of entry for the bacteria and toxins. Her viral syndrome might have contributed as well. Influenza has been shown to act as a precursor to toxic shock syndrome in clinical studies.^{23,24} One might also debate whether the diagnosis of toxic shock syndrome was accurate in this patient. It could be argued that the patient's signs and symptoms, including acute respiratory distress syndrome, disseminated intravascular coagulation, and shock, were caused by *S aureus* septicemia from an unknown source. Although the sequelae of adult respiratory distress syndrome, disseminated intravascular coagulation, shock, and endocarditis could be easily attributed to bacteremia, her initial symptoms, including her prodrome, are more consistent with toxic shock syndrome.

Table 2. Clinical Situations in Which Toxic Shock Syndrome Has Occurred.

Abscesses
Animal bite
Barrier contraception (cervical cap, diaphragm, sponge)
Breast augmentation surgery
Burn wounds
Bursitis
Chemical face peel
Croup
Deep and superficial soft tissue infections
Dermatological surgery
Empyema
Endometritis
Influenza
Insect bite
Lymphadenitis
Nasal packing
Postoperative complication
Postpartum period
Septic abortion
Sinusitis
Tampon use
Tracheitis
Varicella zoster

Table 3. Differential Diagnosis in Toxic Shock Syndrome.

Acute pyelonephritis
Acute rheumatic fever
Acute viral syndrome
Gastroenteritis
Hematoma
Hemolytic uremic syndrome
Kawasaki disease
Legionnaire disease
Leptospirosis
Lyme disease
Meningococemia
Osteomyelitis
Pelvic inflammatory disease
Rocky Mountain spotted fever
Septic shock
Streptococcal or staphylococcal scarlet fever
Systemic lupus erythematosus
Thrombophlebitis
Tumor
Typhus

The differential diagnosis of toxic shock syndrome is broad (Table 3),^{25,26} but a few features should alert the provider. Although headache, myalgias, emesis, and fever can be symptoms of an acute viral syndrome or gastroenteritis, the severity of the patient's symptoms, along with a great amount of immature leukocytosis, suggests a more serious infection. The same is true for the most common diagnosis in the differential diagnosis of toxic shock syndrome, acute pyelonephritis. A final added precaution is that a patient with a severe headache and a temperature to 104°F should have spinal fluid analysis to rule in or out the diagnosis of meningococemia.

At her follow-up visit, the patient had a nearly classic picture of toxic shock syndrome, but this diagnosis was not entertained because no tampon use was reported, and there was no obvious focus of infection. Had toxic shock syndrome been diagnosed, the patient could have benefited from the combination of large doses of β -lactamase-resistant penicillin, aminoglycoside, or clindamycin. These combinations have been shown to inhibit the production of TSST-1 by *S aureus*.²⁷ The patient could also have had more aggressive hydration to prepare for the imminent rapid volume depletion. Corticosteroid and intravenous immunoglobulin

therapy have been beneficial in slowing disease progression in toxic shock syndrome.^{28,29}

Conclusion

Toxic shock syndrome is associated with a wide range of nonmenstrual-related conditions. Because it mimics a number of more common diseases, it is not always considered in the differential diagnosis. When patients have fever, rash, hypotension, a toxic condition out of proportion to local findings, rapid decompensation, and unanticipated laboratory abnormalities, physicians should include the diagnosis of toxic shock syndrome in their differential diagnosis. A thorough evaluation for any foci of infection is necessary, including an IUD. If the patient has an IUD, it should be removed promptly and sent for culture. It is imperative that clinicians not think narrowly of toxic shock syndrome as a disease related to tampon use. The diagnosis of this syndrome should be based on the case definition, not solely on the clinical situation. A strong suspicion, early recognition, and aggressive management of this syndrome will decrease overall morbidity and mortality.

References

1. Todd J, Fishaut M, Kapral F, Welch T. Toxic-shock syndrome associated with phage-group 1 staphylococci. *Lancet* 1978;2:1116–8.
2. Tofte RW, Williams DN. Clinical and laboratory manifestations of toxic shock syndrome. *Ann Intern Med* 1982;96(6 Pt 2):843–7.
3. Lauter CB. Recent advances in toxic shock syndrome. *Contemp Intern Med* 1994;6(6):11–6,19–22.
4. Parsonnet J. Mediators in the pathogenesis of toxic shock syndrome: overview. *Rev Infect Dis* 1989; 11(Suppl 1):S263–9.
5. Kass EH, Parsonnet J. On the pathogenesis of toxic shock syndrome. *Rev Infect Dis* 1987;9(Suppl 5): S482–9.
6. Arbuthnott JP. Toxic shock syndrome: a multisystem conundrum. *Microbiol Sci* 1988;5:13–6.
7. Lund L, Nielsen D, Andersen ES. Meningismus as main symptom in toxic shock syndrome. *Acta Obstet Gynecol Scand* 1988;67:395.
8. McKenna UG, Meadows JA 3rd, Brewer NS, Wilson WR, Perrault J. Toxic shock syndrome, a newly recognized disease entity. Report of 11 cases. *Mayo Clin Proc* 1980;55:663–72.
9. Chesney PJ, Davis JP, Purdy WK, Wand PJ, Chesney RW. Clinical manifestations of toxic shock syndrome. *JAMA* 1981;246:741–8.
10. Centers for disease control and prevention: case def-

inition for public health surveillance. *MMWR Morb Mortal Wkly Rep* 1990;39:38–9.

11. Reingold AL, Hargrett NT, Shands KN, et al. Toxic shock syndrome surveillance in the United States, 1980–1981. *Ann Intern Med* 1982;96(6 Pt 2):875–80.
12. Colbry SL. A review of toxic shock syndrome: the need for education still exists. *Nurse Pract* 1992; 17(9):39,40–3,46.
13. Paris AL, Herwaldt LA, Blum D, Schmid GP, Shands KN, Broome CV. Pathologic findings in twelve cases of toxic shock syndrome. *Ann Intern Med* 1982;96(6 Pt 2):852–7.
14. Shands KN, Schmid GP, Dan BB, et al. Toxic-shock syndrome in menstruating women: association with tampon use and *Staphylococcus aureus* and clinical features in 52 cases. *N Engl J Med* 1980;303:1436–42.
15. Broome CV. Epidemiology of toxic shock syndrome in the United States: overview. *Rev Infect Dis* 1989; 11(Suppl 1): S14–S21.
16. Toivonen J. Intrauterine contraceptive device and pelvic inflammatory disease. *Ann Med* 1993;25: 171–3.
17. Larsen B, Galask RP. Vaginal microbial flora: composition and influences of host physiology. *Ann Intern Med* 1982;96(6 Pt 2):926–30.
18. Heap MG, Tagg JR. Toxic shock syndrome. *N Z Med J* 1987;100:169–71.
19. Guinan ME, Dan BB, Guidotti RJ, et al. Vaginal colonization with *Staphylococcus aureus* in healthy women: a review of four studies. *Ann Intern Med* 1982;96(6 Pt 2):944–7.
20. Lewis R. A review of bacteriological culture of removed intrauterine contraceptive devices. *Br J Fam Plann* 1998;24(3):95–7.
21. Crowder WE, Shannon FL. Colposcopic diagnosis of vaginal ulcerations in toxic shock syndrome. *Obstet Gynecol* 1983;63(3 Suppl): 50S–53S.
22. Gonzalez A, Gorbea HF, Ramirez-Ronda CH. Toxic shock syndrome-pathogenesis. *Boletin–Asociacion Medica De Puerto Rico* 1982;74:383–6.
23. MacDonald KL, Osterholm MT, Hedberg CW, et al. Toxic shock syndrome. A newly recognized complication of influenza and influenzalike illness. *JAMA* 1987;257:1053–8.
24. Prechter GC, Gerhard AK. Postinfluenza toxic shock syndrome. *Chest* 1989;95:1153–4.
25. Wolfe MW, Bennett JT. Pyomyositis with toxic shock syndrome presenting as back pain and fever: a case report and literature review. *Am J Orthop* 1997; 26:135–7.
26. Chesney PJ, Davis JP, Purdy WK, Wand PJ, Chesney RW. Clinical manifestations of toxic shock syndrome. *JAMA* 1981;246: 741–8.
27. van Langevelde P, van Dissel JT, Meurs CJ, Renz J, Groeneveld PH. Combination of flucloxacillin and gentamicin inhibits toxic shock syndrome 1 production by *Staphylococcus aureus* in both logarithmic and stationary phases of growth. *Antimicrob Agents Chemother* 1997;41:1682–5.
28. Barry W, Hudgins L, Donta ST, Pesanti EL. Intravenous immunoglobulin therapy for toxic shock syndrome. *JAMA* 1992;267:3315–6.
29. Lauter CB. Recent advances in toxic shock syndrome. *Contemp Intern Med* 1994;6(6):11–16, 19–22.